

A review of endovascular treatment for medium vessel occlusion stroke

Johanna Maria Ospel ^{1,2}, Mayank Goyal ^{2,3}

► Additional material is published online only. To view, please visit the journal online (<http://dx.doi.org/10.1136/neurintsurg-2021-017321>).

¹Radiology, Universitätsspital Basel, Basel, Switzerland

²Clinical Neurosciences, University of Calgary, Calgary, Alberta, Canada

³Diagnostic Imaging, University of Calgary, Calgary, Alberta, Canada

Correspondence to

Dr Mayank Goyal, Diagnostic Imaging, University of Calgary, Calgary, AB T2N 1N4, Canada; mgoyal2412@gmail.com

Received 15 January 2021

Revised 17 February 2021

Accepted 17 February 2021

Published Online First

26 February 2021

ABSTRACT

Medium-vessel occlusions (MeVOs), that is, occlusions of the M2/3 middle cerebral artery, A2/3 anterior cerebral artery, and P2/3 posterior cerebral artery segments, account for 25%–40% of all acute ischemic stroke cases. Clinical outcomes of MeVO stroke with intravenous thrombolysis, which is the current standard of care, are moderate at best. With improving imaging technologies and a growing literature, MeVOs are increasingly recognized as a target for endovascular treatment (EVT). For the time being, there is limited but promising evidence for the safety and efficacy of MeVO EVT, and many neurointerventionists are already routinely offering EVT for MeVO stroke, despite the lack of clear guideline recommendations. In this article, we review the evidence on endovascular treatment for MeVO stroke and summarize the available literature on current imaging strategies, commonly used EVT selection criteria, EVT techniques, and outcome assessment for MeVO stroke.

In acute ischemic stroke, blockage of an intracranial artery leads to interruption of blood supply of the brain parenchyma with subsequent ischemia and infarction unless blood flow is restored quickly. Acute ischemic stroke has traditionally been divided into large-vessel occlusion (LVO) stroke, that is, acute stroke due to occlusion of proximal arteries of the anterior circulation (the terminal intracranial internal carotid artery (ICA), M1, or A1 segment),¹ and non-LVO stroke. Around 35%–40% of acute ischemic stroke cases occur due to LVO, while 25%–40% are caused by medium-vessel occlusions (MeVOs).^{2,3} Although it is commonly assumed that outcomes of MeVO strokes are better compared with LVO strokes, due to the more distal occlusion location and less extensive ischemia, cohort studies suggest that outcomes are frequently poor, despite best medical management.⁴ Over the past few years, several randomized trials have proven the safety and efficacy of endovascular treatment (EVT) in LVO stroke,⁵ while for patients with MeVOs, there is currently no high-level evidence for EVT. But given the high efficacy of EVT in LVO stroke⁶ and the substantial morbidity associated with MeVO,⁴ EVT is now increasingly performed for MeVO stroke.

DEFINITION OF MEDIUM-VESSEL OCCLUSIONS

In a recent publication, MeVOs have been defined as occlusions of the M2, M3, A2, A3, P2, or P3 segment.^{2,3} That being said, the distinction between LVOs and MVOs is often challenging. For example, there are various ways to define the border between

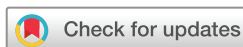the M1 segment, which is considered a “large vessel”, and the M2 segment¹ of the middle cerebral artery. Furthermore, because M2 occlusions, particularly those affecting the dominant branch, can cause clinical symptoms identical to M1 occlusions, some authors include M2 occlusions in their definition of LVO. Given the variability in anatomy and clinical symptoms, a multidimensional definition based on morphological features (ie, vessel anatomy and size) and clinical deficits (ie, symptoms that are commensurate with the occluded vessel) may be preferred over a purely anatomical definition.⁷

PRIMARY AND SECONDARY MEVOS

Not all MeVOs are the same: MeVOs can be classified based on their underlying mechanism as either primary or secondary MeVOs. “Primary” MeVOs occur de novo, with etiologies similar to LVOs. “Secondary” MeVOs occur when clot migration or fragmentation of a LVO occurs.^{8,9} This can happen spontaneously or iatrogenically, after intravenous thrombolysis or during EVT. Secondary MeVOs may either represent embolization to new territory, if they are located outside the area that is affected by the primary occlusion, or embolization to distal territory, if they are located within the territory of the proximal occlusion. Another, rare subtype are “concurrent MeVOs”, that is, MeVOs that occur simultaneously with other occlusions. They are likely part of an “embolic shower” or could be due to fragmentation of a more proximal occlusion.

PREVALENCE AND CLINICAL COURSE OF MEVO STROKE

Although it is commonly assumed that outcomes of MeVO strokes are better compared with LVO strokes, due to the more distal occlusion location and less extensive ischemia, a recent analysis from the INTERSeCT and PROVE-IT cohort studies has shown that one out of four patients with MeVO stroke does not achieve functional independence (modified Rankin Scale (mRS) 0–2) at 90 days with current best management, including intravenous thrombolysis if indicated. An excellent outcome (mRS 0–1) is only achieved by half of the patients with MeVO stroke (online supplemental figure 1).⁴ These somewhat sobering results emphasize the need for a more effective therapy. Given the overwhelming efficacy of endovascular treatment (EVT) in LVO strokes, it might seem obvious to expand this treatment to MeVO patients as well. Many neurointerventionalists already routinely offer EVT in MeVO strokes, particularly in the case of M2



© Author(s) (or their employer(s)) 2021. No commercial re-use. See rights and permissions. Published by BMJ.

To cite: Ospel JM, Goyal M. *J NeuroInterv Surg* 2021;**13**:623–630.

occlusions,^{7 10} but there is no randomized evidence for MeVO EVT, and it is possible that due to the smaller vessel size, MeVO EVT may yield an increased risk of procedural complications.¹¹ Therefore, the question whether EVT is truly beneficial in the setting of MeVO stroke or not, remains to be answered. Furthermore, the smaller vessel caliber and more distal occlusion location of MeVOs compared with LVOs warrant changes in EVT technique and technology.

In the following, we review the existing literature on treatment indications, imaging selection criteria, and treatment techniques for MeVO EVT as well as clinical outcomes following MeVO EVT. We conclude with an outlook on open questions and ongoing developments.

SEARCH STRATEGY

We searched the electronic databases Medline/PubMed, Google Scholar, and EMBASE using the search terms stroke, thrombectomy, endovascular, aspiration, mechanical, small, distal, medium, M2, M3, A2, A3, P2, and P3. We included original research studies, systematic reviews, and meta-analyses which: reported angiographic and/or clinical outcomes of patients with MeVO stroke treated with EVT; included at least five patients; and were published in English. Bibliographies of identified manuscripts were screened for additional relevant studies. The literature search is up-to-date as of 23 November 2020. [Tables 1 and 2](#) provide an overview of the studies and systematic reviews that were identified during the literature search.

IMAGING PROTOCOLS – HOW TO IMAGE MEVO STROKE?

Baseline imaging can facilitate EVT treatment decision making in MeVO stroke, or enrolment in a randomized EVT MeVO trial for that matter, by answering the following questions:

1. Is there evidence of intracranial hemorrhage? Just as with LVO stroke, hemorrhagic stroke needs to be ruled out prior to treatment.
2. Is there an acute MeVO? EVT can only be initiated if a target occlusion is visualized.
3. Does that MeVO explain the patient's deficit (clinical-anatomical correlation, particularly important for secondary MeVOs and concurrent MeVOs in the setting of multiple occlusions)? Right-sided hemiparesis, for example, can be well-explained by a left-sided M2 occlusion, while left-sided hemiparesis cannot.
4. Is the occlusion likely to recanalize with intravenous thrombolysis? Smaller, permeable thrombi may resolve with intravenous thrombolysis which may influence EVT decision-making.
5. Is the MeVO amenable to safe and fast recanalization using EVT? How technically challenging an operator perceives EVT for a certain MeVO and the availability of dedicated EVT tools designed for MeVOs will also influence the treatment decision and help to set the expectations of the patient and the medical team right.

Since EVT has been established as standard of care in 2015,⁶ non-invasive neurovascular imaging (CTA or less frequently MR angiography) is recommended for all acute ischemic stroke patients,¹² and should thus be obtained in all MeVO patients. In the past, detection of MeVOs on non-invasive imaging has been challenging, but innovative imaging techniques such as multiphase CTA (including color-coded mCTA maps) and CT perfusion have rendered fast and reliable MeVO detection possible^{13–15} (online supplemental figure 2). Determining the presence of salvageable brain tissue is more challenging in MeVOs compared with LVOs. Established EVT imaging selection criteria

that are currently used in LVO stroke, namely Alberta Stroke Program Early CT Score (ASPECTS) ≥ 6 ,⁶ intermediate to good collaterals,^{16 17} and currently established perfusion mismatch/core criteria (eg, ischemic core on rCBF maps)^{18–21} will likely be of little use in MeVO stroke. Due to the more distal occlusion, the ischemic territory will be smaller, and as such, ASPECTS will be generally higher and areas with severe hypoperfusion (“core”) smaller. When assessing collateral status, one would have to assess collaterals solely within the affected territory downstream to the MeVO, which can be challenging, especially in the ACA and PCA territory. So far, no standardized methodology has yet been established. Due to the relative insensitivity and high inter-rater reliability of NCCT in detecting early ischemic changes, and because detecting MeVOs on conventional CTA/MRA images is difficult at times, advanced imaging protocols (CTP and MRI) are often used.

However, accurately determining infarct core and penumbra in MeVO stroke may be challenging or not possible at all, as recent literature suggests that we currently lack the ability to precisely delineate infarct “core” with routinely used imaging methods.²² More importantly, delineating ischemic core and penumbra may not even be necessary, as past early time window LVO trials failed to show any volume cut-off below which EVT was no longer beneficial, and current EVT guidelines for LVO patients in the early time window therefore exclusively rely on NCCT ASPECTS to estimate the degree of irreversible tissue damage.⁶ That being said, using ASPECTS in MeVO stroke may be problematic, since the anterior and posterior cerebral artery territories are not represented at all, and even in middle cerebral artery MeVOs, the ASPECTS range will be relatively small, since the internal capsule, lentiform, and caudate are unlikely to be affected, and of the cortical 6 regions, only few will be affected. Thus, for a typical M3 occlusion, ASPECTS may be either 8, 9, or 10.

Most of the MeVO EVT studies we identified used a CT-based imaging protocol, and approximately half of them included CT perfusion as part of the standard protocol, regardless of the time frame, and some reported MRI-based protocols with DWI \pm PWI sequences ([table 2](#)). Studies that relied only on NCCT and single-phase CTA were mostly subgroup analyses from randomized LVO trials and LVO registries,^{23 24} that is, M2 occlusions were a small minority of all cases. Many studies simply transferred the perfusion thresholds²⁵ and ASPECTS^{26 27} cut-offs that are used for LVO strokes to their MeVO patient sample, which may be suboptimal for MeVO patient selection. Only a few studies adapted imaging selection criteria and used, for example, a higher ASPECTS cut-off.^{28 29} [Table 3](#) provides an overview of different MeVO imaging paradigms. Future studies should aim to develop MeVO-specific imaging selection criteria for EVT.

CLINICAL EVT SELECTION CRITERIA FOR MEVO EVT

Just as there are no uniform imaging criteria for EVT patient selection in MeVO strokes, there is also no consensus on clinical selection criteria. Several MeVO EVT studies used an NIHSS threshold of ≥ 6 ,^{25–28} as it is currently recommended for LVO strokes.⁶ However, a recent analysis from prospective cohort studies has shown that 1/3 of MeVO stroke patients have a baseline NIHSS < 6 . One study specifically stated that they included patients “with NIHSS ≥ 6 or disabling deficit”,³⁰ and another one lowered the NIHSS cut-off of 5 instead of 6,²⁹ which seems more appropriate, considering that one out of three patients with untreated supposedly “mild” strokes (NIHSS < 5) will not be functionally independent at 90 days.³¹ Indeed, in a recent survey, most physicians stated that they would offer EVT for

Table 1 Original research manuscripts that were identified during the literature search

First Author Year	Study type	N with MeVO EVT	NIHSS (median/mean)	ASPECTS (median/mean)	Imaging modality used	Treatment criteria	MeVO type	Technique used	Anesthesia	Angiographic outcome	Clinical outcome	sICH
Romano et al 2020 ²⁷	MC	44	10	9	NCCT+CTA (±DWI if onset unknown)	NIHSS≥6 Pre-stroke mRS 0–2 ASPECTS≥6 Absence of large infarction DWI-clinical mismatch Contraindication to IV tPA	M2, M2/M3	DA	GA, CS	TICI 2b/3: 91%	mRS 0–2: 71%	0%
Hausen et al 2020a ³⁴	SC	137	18	8/9	NCCT+CTA+CTP	–	M2, M3 Any ACA Any PCA	DA, SR	–	TICI 2b/3: 84% (SR) vs 69% (DA) TICI 3: 58% (SR) vs 46% (DA)	mRS 0–2: 45% (SR) vs 46% (DA)	–
Atchaneeyasakul et al 2020 ⁴⁶	MC	197	15/17	9	NCCT+CTA	Isolated MeVO (absence of concurrent LVO)	M2	DA, SR	–	TICI 2b/3: 90% (SR) vs 77% (DA)	mRS 0–2: 52% (SR) vs 37% (DA)	3% (SR) vs 5% (DA)
Jiang et al 2019 ³⁵	SC	37	15	10	NCCT+CTA+CTP	Symptom onset ≤24 hour NIHSS ≥6 Pre-stroke mRS 0–1 ASPECTS ≥6 Absence of large infarction CTP mismatch ratio>1.8	M2	SR	CS	TICI 2b/3: 95% TICI 3: 76%	mRS 0–2: 49%	11%
Compagne et al 2019 ³³	MC	244	14	9	NCCT+CTA	Symptom onset ≤6.5 hour	M2	DA, SR, IA tPA	–	TICI 2b/3: 57%	mRS 0–2: 46% mRS 0–1: 2.6% mRS 0: 7%	7%
Gory et al 2018 ⁴⁷	RCT	79	13.4	8	–	–	M2	DA, SR	CS, GA	TICI 2b/3: 84% (SR) vs 90% (DA) TICI 2/3: 55% (SR) vs 54% (DA) TICI 3: 42% (SR) vs 35% (DA)	mRS 0–2: 50% (SR) vs 54% (DA)	3% (SR) vs 6% (DA)
Qureshi et al 2017 ⁴⁸	RCT	34	16	–	NCCT+CTA	Age 18–82y tPA eligibility Symptom onset ≤3 hour Absence of large infarction	M2	SR, IA tPA	–	TICI 2b/3: 52.6%	mRS 0–2: 53% mRS 0–1: 38%	6%
Vargas et al 2017 ³⁷	SC	35	14.1	–	NCCT+CTA+CTP	Contraindication to IV tPA	M2, A3, combinations	DA	–	TICI 2b/3: 97% TICI 2c/3: 83% TICI 3: 43%	mRS 0–2: 59%	3%
Sarraj et al 2016 ⁴⁹	MC	288	16	9	NCCT+CTA	Symptom onset ≤8 hour	M2	DA, SR±IA tPA	–	TICI 2b/3: 78%	mRS 0–2: 63% mRS 0–1: 3.6% mRS 0: 1.4%	6%
Navia et al 2016 ⁴⁹	SC	6	12.5	–	NCCT+CTA+CTP	NIHSS≤5 ASPECTS≥8	M2, M3, P2, A2	DA	CS and GA	TICI 2b/3: 100% TICI 3: 83%	mRS 02: 100% mRS 0–1: 60% mRS 0: 20%	0%
Menon et al 2019 ⁴⁴	RCT	67	14	9	NCCT+CTA (±CTP/MRI)	–	M2	SR	–	TICI 2b/3: 59%	mRS 0–2: 58% mRS 0–1: 3.7% mRS 0: 1.9%	0%
Coutinho et al 2016 ⁴⁸	MC	50	13	9	NCCT+CTA (±CTP/MRI)	–	M2	SR	CS, GA	TICI 2b/3: 85%	mRS 0–2: 60% mRS 0–1: 5.0%	2%
Grossberg et al 2018 ⁴⁵	SC	69	18.1	8	NCCT+CTA+CTP	Persisting disabling deficits despite IV tPA with occlusion location accounting for the symptoms	M3 Any ACA Any PCA	DA, SR	–	TICI 2b/3: 83% TICI 3: 45%	mRS 0–2: 30% mRS 0–1: 1.3%	–

Continued

Table 1 Continued

First Author Year	Study type	N with MeVO EVT	NIHSS (median/mean)	ASPECTS (median/mean)	Imaging modality used	Treatment criteria	MeVO type	Technique used	Anesthesia	Angiographic outcome	Clinical outcome	sICH
Nakano et al 2020 ³¹	MC	51	17	8	–	–	M2	DA, SR	–	TICI 2b/3: 84%	mRS 0–2: 49%	3%
Altenbernd et al 2018 ⁴⁸	SC	58	15	9	NCCT+CTA+CTP	Age ≥18 NIHSS ≥6 ASPECTS ≥8	M2, M3	DA	GA	TICI 2b/3: 100% TICI 3: 83%	mRS 0–2: 95% mRS 0–1: 86% mRS 0: 35%	3%
Crockett et al 2019 ⁴⁵	SC	14	8	9	–	–	A2, A3, P2, M3, SCA	DA	–	TICI 2b/3: 100% TICI 2c/3: 100% TICI 3: 91%	mRS 0–2: 63% mRS 0–1: 50% mRS 0: 43%	0%
Bhargal et al 2017 ⁵²	SC	106	12	9	NCCT+CTA or MRI	–	M2	SR	–	TICI 2b/3: 91% TICI 3: 69%	mRS 0–2: 55% mRS 0–1: 45% mRS 0: 24%	5%
de Castro Afonso et al 2019 ⁴⁶	SC	30	16	9	NCCT+CTA	Symptom onset ≤6 hour or CTP mismatch if symptom onset 6–24 hour NIHSS ≥6 ASPECTS ≥6	M2	DA, SR, combination	CS, GA	TICI 2b/3: 90% TICI 2c/3: 60% TICI 3: 53%	mRS 0–2: 50% mRS 0–1: 23% mRS 0: 17%	7%
Grieb et al 2019 ³⁰	SC	52	12	–	NCCT+CTA	NIHSS ≥6 or aphasia Absence of large infarction	M2	DA	GA	TICI 2b/3: 91% TICI 3: 65%	mRS 0–2: 56%	0%
Pérez-García et al 2020 ⁴³	SC	102	16	9	–	–	M2, M3, Any ACA Any PCA	SR, combination	CS, GA	TICI 2b/3: 50% (SR) vs 64% (combination) TICI 2c/3: 34% (SR) vs 57% (combination)	mRS 0–2: 53 (SR) vs 51% (combined)	13% (SR) vs 2% (combination)
Hausse et al 2020b ³⁴	SC	22	17	8	–	–	M2	Combination	–	TICI 2b/3: 84% TICI 3: 64%	mRS 0–2: 40%	–
Plaff et al 2016 ⁵⁴	SC	30	18	9	DWI+MRA+ PWI or NCCT+CTA+CTP	Symptom onset ≤8 hour NIHSS ≥8 ASPECTS ≥6	A2, A3, A4	SR	CS, GA	TICI 2b/3: 73%	mRS 0–2: 37%	0%
Styczen et al 2020 ⁵⁵	MC	15	13	10 (pcASPECTS)	–	–	SCA, AICA, PCA	SR, DA, combination, IA tPA	–	TICI 2b/3: 88% TICI 3: 31%	mRS 0–2: 50% mRS 0–1: 29% mRS 0: 7%	–

Note: MC = multi center, SC = single center, EVT = endovascular treatment, MeVO = medium vessel occlusion stroke, NIHSS = National Institutes of Health Stroke Scale, (pc)ASPECTS = (posterior circulation) Alberta Stroke Program Early CT Score, CTA = CT angiography, NCCT = non contrast head CT, DWI = diffusion weighted imaging, CTP = CT perfusion, DA = direct aspiration, SR = stent retriever, IA tPA = intra-arterial alteplase, CS = conscious sedation, GA = general anesthesia, SCA = superior cerebellar artery, AICA = anterior inferior cerebellar artery, PCA = posterior inferior cerebellar artery, TICI = Thrombolysis in Cerebral Infarction Score, mRS = modified Rankin Score, sICH = symptomatic intracranial hemorrhage

Table 2 Systematic reviews and meta-analyses that were identified during the literature search

First Author Year	Study type	Research question	Main findings	N of studies	N with MeVO EVT	NIHSS (median/mean)	ASPECTS (median/mean)	MeVO type	Technique used	Angiographic outcome	Clinical outcome	sICH
Phan et al 2018 ³⁸	MA	What are the reperfusion rates in M2 occlusions treated with SR vs DA?	Both SR and DA are effective in recanalizing M2 occlusions. The literature is skewed by DA being performed sooner after onset of stroke compared with SR EVT.	12	835	14	9	Mostly M2	SR (n=612) vs DA (n=223)	TICI 2b/3: 81% (SR) vs 87% (DA) TICI 3: 54% (SR) vs 57% (DA) (I ² =37%)	mRS 0–2: 60% (SR) vs 75% (DA) mRS 0–1: 40% (SR) vs 66% (DA) (I ² =52%)	6% (SR) vs 3% (DA) (I ² =0%)
Saber et al 2018 ⁴²	MA	What are the angiographic results and functional outcome after M2 EVT and how do they compare to EVT for LVO?	M2 EVT is technically feasible and safe with high functional independence. There may be a slightly increased risk of ICH.	12	1080	14	–	M2	SR, DA	TICI 2b/3: 81% (I ² =20%)	mRS 0–2: 59% (I ² =61%)	10% (I ² =75%)
Kim et al 2019 ⁵⁶	MA	What are the angiographic results and functional outcome after M2 EVT and how do they compare to EVT for M1 occlusions?	M2 EVT is technically feasible. Further studies are needed to better characterize the effect of EVT in M2 occlusions.	8	650	–	–	M2	–	TICI 2b/3: 69% (I ² not provided)	mRS 0–2: 59% (I ² not provided)	6% (I ² not provided)
Chen et al 2017 ⁵⁷	SR	What is the evidence for M2 EVT in the existing literature?	M2 EVT results in high functional independence with modest ICH rates. But given the relatively favorable clinical course of M2 occlusions with conservative management, the benefits of EVT remain unclear.	8	630	–	–	M2	SR, DA	TICI 2b/3: 78% (I ² not provided)	mRS 0–2: 63% mRS 0–1: 40% (I ² not provided)	5% (I ² not provided)

Note: MA = meta-analysis, SR = stent retriever, DA = direct aspiration, EVT = endovascular treatment, (s)ICH = (symptomatic) intracranial hemorrhage, TICI = Thrombolysis in Cerebral Infarction Score, mRS = modified Rankin Score.

LVO patients with low NIHSS.³² Whether a patient is eligible for intravenous thrombolysis or not also seems to play an important role in MeVO EVT decision-making. More than 50% of physicians would perform EVT in M3, A2, and P2 occlusions if the patient is ineligible for intravenous thrombolysis, but when intravenous thrombolytics can be safely administered, the willingness to proceed with EVT is substantially lower.⁷ For now, until randomized trial data become available, the decision to treat or not to treat a MeVO will remain a subjective one that is influenced by many factors, including patient preferences, eligibility for intravenous thrombolysis, and operator skills. Treatment decision-making is further complicated by the variety of clinical symptoms MeVO patients can present with, which are dependent on the eloquence of the affected area.³ A patient with a right-sided small branch anterior M2 occlusion, for example, may barely suffer from any deficits, but another patient suffering from a similar sized left-sided M2 occlusion may present with severe aphasia. Furthermore, new thrombolytic agents such as Tenecteplase,³³ and neuroprotectants such as Nerinetide¹⁷ could improve the prognosis of MeVO stroke with conservative management and thereby also influence treatment decision-making in MeVO EVT.

THROMBECTOMY TECHNIQUE – HOW TO PERFORM EVT IN MEVO STROKE?

Several challenges emerge when performing EVT for MeVOs stroke. For the time being, we don't know how high the risk of vasospasm and dissection is when the catheter size matches or exceeds the vessel diameter, which can happen with large-bore aspiration catheters in MeVOs. Medium-sized vessels can be too small to harbor a regular-sized distal access catheter (DAC), as most of the currently used DACs are 5–6F in diameter. Another problem is the DAC often gets stuck at the ledge of a bifurcation point such, such as the M1 bifurcation, but there

are wedge-shaped microcatheters available to overcome this ledge effect. Furthermore, using a primary combined approach (ie, the combination of stent retriever, DAC, and balloon guide catheter), and advancing the system in a tri-axial manner, as it is commonly done for LVOs, may not be possible because of insufficient catheter length and diameter discrepancies. For example, using a longer DAC to access an M3 occlusion may not allow for a small enough and long enough microcatheter capable of deploying a stent. Thus, currently, the microwire and microcatheter are often introduced without a DAC. Once the microcatheter is in place, the stent can be deployed and the microcatheter removed before the distal access catheter is navigated to the site of occlusion (so-called “blind exchange mini-pinning technique”).^{34,35} However, this is probably a transient problem, as many of the newer stent retrievers can be deployed through a 017 microcatheter and more and more microcatheters are now available in 160 cm length. On the other hand, numerous authors reported promising results of primary aspiration as the first-line approach in MeVO stroke, which may constitute an equally effective alternative to stent retriever-based techniques.^{27–30,36,37} A comprehensive and unbiased comparison of different MeVO EVT techniques is currently not possible, since most studies are small, focus on specific devices, and a comparator group is often lacking. Furthermore, the literature on MeVO EVT techniques is biased, with onset-to-treatment times being on average much shorter in studies that used primary aspiration compared with those in which stent retrievers were used.³⁸ Of note, MeVO EVT techniques and technologies are constantly evolving, and with MeVOs increasingly being targeted by neurointerventionalists, it is likely that treatment devices that are specifically tailored to MeVOs will be developed in the near future.

A substantial number of LVOs are treated without the use of general anesthesia (GA). Although randomized trials show equivalent or even better outcomes with GA vs conscious sedation,³⁹

Table 3 Overview of different MeVO stroke imaging protocols

MeVO stroke imaging protocols	Studies in which the protocol was used	Advantages	Disadvantages
NCCT+CTA	Romano et al 2020 ²⁷ (+DWI if symptom onset unknown) Atchaneeyasakul et al 2020 ⁴⁶ Compagne et al 2019 ²³ Qureshi et al 2017 ⁴⁸ Sarraj et al 2016 ⁴⁹ Menon et al 2019 ²⁴ (CTP/MRI was available in some patients) Coutinho et al 2016 ⁵⁰ Bhogal et al 2017 ⁵² (either NCCT+CTA or MRI) De Castro Afonso et al 2019 ²⁶ Grieb et al 2019 ³⁰	<ul style="list-style-type: none"> ► Wide availability ► Inexpensive ► Fast ► Robust against patient motion ► No post-processing needed ► Option to use multiphase CTA, including color-coded time-variant mCTA maps and mCTA-derived CTP-like maps^{14 58} 	<ul style="list-style-type: none"> ► If single-phase CTA is used MeVOs may be missed⁵⁹ ► Little information about collateral status if single-phase CTA is used ► Current ASPECTS thresholds for LVO EVT are probably not optimal for MeVO EVT ► ASPECTS does not capture ischemic changes in ACA and PCA MeVO stroke
NCCT+CTA + CTP	Haussen et al 2020a ³⁴ Jiang et al 2019 ²⁵ Vargas et al 2017 ³⁷ Navia et al 2016 ²⁹ Menon et al 2019 ²⁴ (CTP/MRI was available in some patients) Coutinho et al 2016 ⁵⁰ (CTP/MRI was available in some patients) Grossberg et al 2018 ⁴⁵ Altenbernd et al 2018 ²⁸ Pfaff 2016 ⁵⁴ (either NCCT+CTA + CTP or DWI+MRA + PWI)	<ul style="list-style-type: none"> ► Higher information content compared with NCCT+CTA only ► Estimates for ischemic penumbra and "core" volumes, also for ACA and PCA MeVO stroke ► Does not exclusively rely on ASPECTS for ischemic "core" assessment ► Option to use either single or multiphase CTA 	<ul style="list-style-type: none"> ► Unavailability or limited availability of CTP in smaller hospitals ► Limited accuracy of "core" and penumbra estimates due to variability in post-processing mechanisms ► Susceptibility to patient motion
MRI (DWI-MRI±PWI)	Romano et al 2020 ²⁷ (NCCT +CTA, DWI only if symptom onset unknown) Menon et al 2019 ²⁴ (CTP/MRI was available in some patients) Bhogal et al 2017 ⁵² (either NCCT+CTA or MRI) Pfaff et al 2016 ⁵⁴ (either NCCT+CTA + CTP or DWI+MRA + PWI)	<ul style="list-style-type: none"> ► DWI: Highest sensitivity for acute small infarcts ► PWI: Estimates ischemic penumbra and "core" volumes, also for ACA and PCA MeVO stroke 	<ul style="list-style-type: none"> ► Limited availability of MRI and particularly PWI in many hospitals ► Contraindications ► Limited accuracy of PWI "core" and penumbra estimates due to variability in post-processing mechanisms ► Susceptibility to patient motion ► Various pitfalls in MRI interpretation due to artifacts (eg, slow flow, metal artifacts due to dental fillings, etc.)

NCCT = non contrast head CT, CTA = CT angiography, CTP = CT perfusion, DWI = diffusion-weighted imaging, MRA = MR angiography, PWI = perfusion-weighted imaging, ACA = anterior cerebral artery, PCA = posterior cerebral artery, LVO = large vessel occlusion, ASPECTS = Alberta Stroke Program Early CT Score

data from the HERMES collaboration⁴⁰ and individual EVT trials⁴¹ show worse outcomes with GA. It is possible that the use of GA will substantially increase when performing MeVO EVT, given the need for an excellent roadmap to get access to the relatively distally located clot. In addition, the anatomical variability is much higher in distal vessels. Sometimes, the MeVO may be right at the origin of a vessel branch, which requires the operator to blindly explore the site of the occlusion very gently in order to find the relevant vessel origin, which is much easier under GA, when patient movement is completely eliminated. Thus, the impact of an increased use of GA on functional outcome will need to be better understood.

OUTCOME ASSESSMENT IN MEVO EVT

Clinical outcomes

In MeVO strokes the area that is affected by ischemia is smaller than in LVO strokes. Thus, one would intuitively expect clinical outcomes to be better. Most studies that were identified in the literature search reported "good outcome", defined as mRS 0–2 at 90 days, as primary outcome (table 1). Given the overall better prognosis, it seems however worthwhile to consider a more restrictive outcome measure such as "excellent outcome", i.e. mRS 0–1, or mRS shift analysis. Indeed, this has been recognized by several authors, who reported mRS 0–1 or proportions of patients in each mRS category in addition to mRS 0–2 (table 1).

It is important to note that deficits such as isolated abulia (due to A2/3 occlusion), alexia and agraphia (due to M2/3 occlusions), or quadrantanopia (due to P2/3 occlusion) are not well captured in the NIHSS and mRS. Not only are those scales limited in their granularity, they are also heavily focused on motor function and thus unable to capture the more subtle personality changes and domain-specific impairment that often play a dominant role in MeVO stroke-related disability.

Angiographic outcomes

In most MeVO EVT studies, angiographic outcomes are reported as "successful reperfusion", that is, TICI 2b/3, analogous to reperfusion assessment in LVO stroke, although several studies reported TICI 3 and/or TICI 2c/3 reperfusion in addition to TICI 2b/3 rates (table 1). Reporting successful reperfusion (TICI 2b/3) only is problematic, given that MeVOs in the anterior and posterior cerebral artery territory are not reflected in TICI at all, and patients with distal M2 or M3 occlusions will frequently have TICI 2b at baseline. There is currently no satisfactory reperfusion grading system tailored to MeVO stroke. Crockett et al made an interesting attempt in this regard: in addition to the "regular" TICI, they used a modified TICI, which focused solely on the territory affected by the MeVO, with a scoring system identical to the standard TICI system (1, 2a, 2b, 2c, 3).³⁶ Figure 1 shows a proposed modified eTICI scoring system for

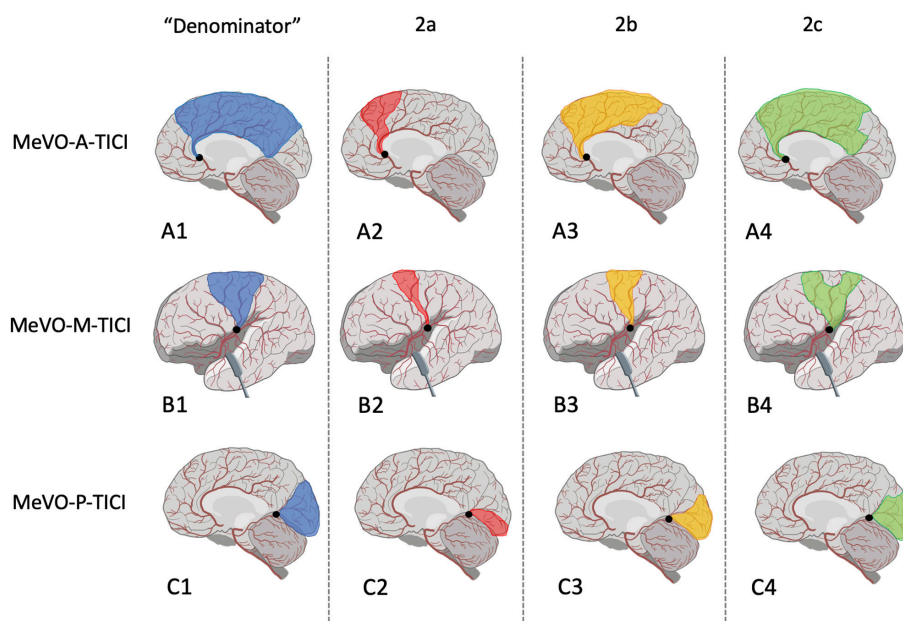


Figure 1 Suggested modified eTICI classification for MeVOs in the anterior (MeVO-A-TICI: A), middle (MeVO-M-TICI: B) and posterior (MeVO-P-TICI: C) cerebral artery. Blue overlays in (A1), (B1), and (C1) indicate the “denominator”, that is, the territory downstream of the occlusion that serves as a comparator. Complete reperfusion of the territory marked in blue would correspond to an eTICI score of 3. Reperfusion contained to territory marked with red overlays in (A2), (B2), and (C2) would indicate a MeVO-A-TICI, MeVO-M-TICI, and MeVO-P-TICI score of 2A, that is, reperfusion of less than 50% of the initially affected territory. Reperfusion contained to territory marked with yellow overlays in (A3), (B3), and (C3) would indicate an MeVO-A-TICI, MeVO-M-TICI, and MeVO-P-TICI score of 2B, that is, reperfusion of 50%–90% of the initially affected territory. Reperfusion contained to territory marked with green overlays in (A4), (B4), and (C4) would indicate an MeVO-A-TICI, MeVO-M-TICI, and MeVO-P-TICI score of 2c, that is, near-complete reperfusion/ reperfusion of less than 90%–99% of the initially affected territory.

anterior, middle, and posterior cerebral artery MeVOs. The key difference to the conventional eTICI score is hereby the “denominator”, that is, only the affected territory downstream to the MeVO, rather than the entire middle cerebral artery territory, is used as a comparator.

Safety outcomes

Accurate and consistent reporting of safety outcomes is crucial when performing MeVO EVT, since the risk of complications is probably higher compared with LVOs, due to the relatively smaller vessel size and more distal occlusion location. Symptomatic intracranial hemorrhage (sICH) was the most consistently reported complication type in MeVO EVT studies (table 1), although many reported asymptomatic hemorrhage, vasospasm, and extracranial complications as well. In two studies, sICH rates ranged from 10%–11%,^{25 42} while the prevalence in other studies was below 8%, which is only slightly higher compared with LVOs.⁵

OUTCOMES FOR EVT IN PRIMARY VS. SECONDARY MEVOS

Most of the literature published on MeVO EVT does not distinguish between primary and secondary MeVOs. But in particular the effect of “rescue” EVT in procedure-related secondary MeVOs is of great interest for neurointerventionalists, since peri-procedural embolization of clot fragments is a common phenomenon. Embolization causing anterior cerebral artery occlusion, for example, has been observed in more than 10% of LVO EVT procedures,⁴³ especially in cases with terminal ICA occlusion, in which the clot segment extending into the ACA might get “guillotined off” by the distal aspiration catheter or stent retriever.⁴⁴ Since the infarcted area will often be larger in

secondary MeVOs, one would assume clinical outcomes to be worse compared with primary MeVO strokes. However, Grossberg et al, who reported post-EVT outcomes for primary and iatrogenic (EVT-induced) secondary MeVOs separately, found similar recanalization results and even slightly better clinical outcomes in patients with secondary MeVOs, despite more severe symptoms at baseline.⁴⁵ Future studies on MeVO EVT should aim to capture information on MeVO types, and report results stratified for primary vs secondary MeVOs.

CONCLUSION AND OUTLOOK

With improving imaging technologies and a growing body of literature, MeVOs are being increasingly recognized as a target for EVT. Outcomes with intravenous thrombolysis, which is the current standard of care, are moderate at best and many patients are not eligible for thrombolytic treatment at all. At the present time, there is limited but promising evidence for the safety and efficacy of MeVO EVT. Many interventionists are already routinely treating primary as well as secondary MeVOs, that is, emboli into distal vessels during EVT for LVO stroke. However, standardized imaging protocols, treatment indication criteria, and unbiased comparisons of different EVT techniques for MeVOs are lacking. At the same time, imaging tools and particularly MeVO EVT techniques are rapidly evolving. A randomized controlled trial seems unavoidable in order to establish MeVO EVT as standard of care.

Twitter Johanna Maria Ospel @johanna_ospel and Mayank Goyal @mayank_GO

Acknowledgements The authors want to thank Basti Uhlmann for his help in designing the figure.

Contributors Both authors were involved in drafting and critical revisions of the manuscript.

Funding The authors have not declared a specific grant for this research from any funding agency in the public, commercial, or not-for-profit sectors.

Competing interests MG is a consultant for Medtronic, Stryker, Microvention, GE Healthcare, Mentice.

Patient consent for publication Not required.

Provenance and peer review Commissioned; externally peer reviewed.

Supplemental material This content has been supplied by the author(s). It has not been vetted by BMJ Publishing Group Limited (BMJ) and may not have been peer-reviewed. Any opinions or recommendations discussed are solely those of the author(s) and are not endorsed by BMJ. BMJ disclaims all liability and responsibility arising from any reliance placed on the content. Where the content includes any translated material, BMJ does not warrant the accuracy and reliability of the translations (including but not limited to local regulations, clinical guidelines, terminology, drug names and drug dosages), and is not responsible for any error and/or omissions arising from translation and adaptation or otherwise.

ORCID iDs

Johanna Maria Ospel <http://orcid.org/0000-0003-0029-6764>

Mayank Goyal <http://orcid.org/0000-0001-9060-2109>

REFERENCES

- Goyal M, Menon BK, Krings T, et al. What constitutes the M1 segment of the middle cerebral artery? *J Neurointerv Surg* 2016;8:1273–7.
- Dulquin G, Graber M, Garnier L, et al. Incidence of acute ischemic stroke with visible arterial occlusion: a population-based study (Dijon Stroke Registry). *Stroke* 2020;51:2122–30.
- Saver JL, Chapot R, Agid R, et al. Thrombectomy for distal, medium vessel occlusions: a consensus statement on present knowledge and promising directions. *Stroke* 2020;51:2872–84.
- Ospel JM, Menon BK, Demchuk AM, et al. Clinical course of acute ischemic stroke due to medium vessel occlusion with and without intravenous alteplase treatment. *Stroke* 2020;51:STROKEAHA120030227.
- Goyal M, Menon BK, van Zwam WH, et al. Endovascular thrombectomy after large-vessel ischaemic stroke: a meta-analysis of individual patient data from five randomised trials. *Lancet* 2016;387:1723–31.
- Powers WJ, Rabinstein AA, Ackerson T, et al. Guidelines for the early management of patients with acute ischemic stroke: 2019 update to the 2018 guidelines for the early management of acute ischemic stroke: a guideline for healthcare professionals from the American Heart Association/American Stroke Association. *Stroke* 2019;50:e344–418.
- Goyal M, Ospel JM, Menon BK, et al. MeVO: the next frontier? *J Neurointerv Surg* 2020;12:545–7.
- Goyal M, Kappelhof M, McDonough R, et al. Secondary medium vessel occlusions: when clots move north. *Stroke* 2021:STROKEAHA120032799.
- Ospel JM, Cimflova P, Marko M, et al. Prevalence and outcomes of medium vessel occlusions with discrepant infarct patterns. *Stroke* 2020;51:2817–24.
- Almekhlafi M, Ospel JM, Saposnik G, et al. Endovascular treatment decisions in patients with M2 segment MCA occlusions. *AJNR Am J Neuroradiol* 2020;41:280–5.
- Kurre W, Aguilar-Pérez M, Martínez-Moreno R, et al. Stent retriever thrombectomy of small caliber intracranial vessels using pREset LITE: safety and efficacy. *Clin Neuroradiol* 2017;27:351–60.
- Powers WJ, Rabinstein AA, Ackerson T, et al. 2018 guidelines for the early management of patients with acute ischemic stroke: a guideline for healthcare professionals from the American Heart Association/American Stroke Association. *Stroke* 2018;49:e46–110.
- Menon BK, d'Este CD, Qazi EM, et al. Multiphase CT angiography: a new tool for the imaging triage of patients with acute ischemic stroke. *Radiology* 2015;275:510–20.
- Ospel JM, Volny O, Qiu W, et al. Displaying multiphase CT angiography using a time-variant color map: practical considerations and potential applications in patients with acute stroke. *AJNR Am J Neuroradiol* 2020;41:200–5.
- Yu AXY, Zerna C, Assis Z, et al. Multiphase CT angiography increases detection of anterior circulation intracranial occlusion. *Neurology* 2016;87:609–16.
- Goyal M, Demchuk AM, Menon BK, et al. Randomized assessment of rapid endovascular treatment of ischemic stroke. *N Engl J Med* 2015;372:1019–30.
- Hill MD, Goyal M, Menon BK, et al. Efficacy and safety of nirenitide for the treatment of acute ischaemic stroke (ESCAPE-NA1): a multicentre, double-blind, randomised controlled trial. *Lancet* 2020;395:878–87.
- Albers GW, Marks MP, Kemp S, et al. Thrombectomy for stroke at 6 to 16 hours with selection by perfusion imaging. *N Engl J Med* 2018;378:708–18.
- Campbell BCV, Mitchell PJ, Kleinig TJ, et al. Endovascular therapy for ischemic stroke with perfusion-imaging selection. *N Engl J Med* 2015;372:1009–18.
- Saver JL, Goyal M, Bonafe A, et al. Stent-retriever thrombectomy after intravenous t-PA vs. t-PA alone in stroke. *N Engl J Med* 2015;372:2285–95.
- Nogueira RG, Jadhav AP, Haussen DC, et al. Thrombectomy 6 to 24 hours after stroke with a mismatch between deficit and infarct. *N Engl J Med* 2018;378:11–21.
- Goyal M, Ospel JM, Menon B, et al. Challenging the ischemic core concept in acute ischemic stroke imaging. *Stroke* 2020;51:3147–55.
- Compagne KCJ, van der Sluijs PM, van den Wijngaard IR, et al. Endovascular treatment: the role of dominant caliber M2 segment occlusion in ischemic stroke. *Stroke* 2019;50:419–27.
- Menon BK, Hill MD, Davalos A, et al. Efficacy of endovascular thrombectomy in patients with M2 segment middle cerebral artery occlusions: meta-analysis of data from the HERMES Collaboration. *J Neurointerv Surg* 2019;11:1065–9.
- Jiang L, Xia W-Q, Huang H, et al. Mechanical thrombectomy outcome predictors in stroke patients with M2 occlusion: a single-center retrospective study. *World Neurosurg* 2019;127:e155–61.
- de Castro Afonso LH, Borghini Pazuella G, Seizem Nakiri G, et al. Thrombectomy for M2 occlusions and the role of the dominant branch. *Interv Neuroradiol* 2019;25:697–704.
- Romano DG, Frauenfelder G, Caragliano A, et al. Multicentric experience with an intermediate aspiration catheter for distal M2 ischemic stroke. *J Stroke Cerebrovasc Dis* 2020;29:105389.
- Altenbernd J, Kuhnt O, Hennigs S, et al. Frontline ADAPT therapy to treat patients with symptomatic M2 and M3 occlusions in acute ischemic stroke: initial experience with the Penumbra ACE and 3MAX reperfusion system. *J Neurointerv Surg* 2018;10:434–9.
- Navia P, Larrea J-A, Pardo E, et al. Initial experience using the 3MAX cerebral reperfusion catheter in the endovascular treatment of acute ischemic stroke of distal arteries. *J Neurointerv Surg* 2016;8:787–90.
- Grieb D, Schlunz-Hendann M, Brinjikji W, et al. Mechanical thrombectomy of M2 occlusions with distal access catheters using ADAPT. *J Neuroradiol* 2019;46:231–7.
- Spokorny I, Raman R, Erstrom K, et al. Defining mild stroke: outcomes analysis of treated and untreated mild stroke patients. *J Stroke Cerebrovasc Dis* 2015;24:1276–81.
- Ospel JM, Kim B, Heo J-H, et al. Endovascular treatment decision-making in acute ischemic stroke patients with large vessel occlusion and low National Institutes of Health Stroke Scale: insights from UNMASK EVT, an international multidisciplinary survey. *Neuroradiology* 2020;62:715–21.
- Campbell BCV, Mitchell PJ, Churilov L, et al. Tenecteplase versus alteplase before thrombectomy for ischemic stroke. *N Engl J Med* 2018;378:1573–82.
- Haussen DC, Al-Bayati AR, Eby B, et al. Blind exchange with mini-pinning technique for distal occlusion thrombectomy. *J Neurointerv Surg* 2020;12:392–5.
- Pérez-García C, Moreu M, Rosati S, et al. Mechanical thrombectomy in medium vessel occlusions: blind exchange with mini-pinning technique versus mini stent retriever alone. *Stroke* 2020;51:3224–31.
- Crockett MT, Phillips TJ, Chiu AHY. Dual suction Headway27 microcatheter thrombectomy for the treatment of distal intracranial arterial occlusion strokes: initial experience with the micro-ADAPT technique. *J Neurointerv Surg* 2019;11:714–8.
- Vargas J, Spiotta AM, Fargen K, et al. Experience with a direct aspiration first pass technique (ADAPT) for thrombectomy in distal cerebral artery occlusions causing acute ischemic stroke. *World Neurosurg* 2017;99:31–6.
- Phan K, Maingard J, Kok HK, et al. Contact aspiration versus stent-retriever thrombectomy for distal middle cerebral artery occlusions in acute ischemic stroke: meta-analysis. *Neurointervention* 2018;13:100–9.
- Campbell D, Diprose WK, Deng C, et al. General anesthesia versus conscious sedation in endovascular thrombectomy for stroke: a meta-analysis of 4 randomized controlled trials. *J Neurosurg Anesthesiol* 2021;33:21–7.
- Campbell BCV, van Zwam WH, Goyal M, et al. Effect of general anaesthesia on functional outcome in patients with anterior circulation ischaemic stroke having endovascular thrombectomy versus standard care: a meta-analysis of individual patient data. *Lancet Neurol* 2018;17:47–53.
- Menon BK, Sajobi TT, Zhang Y, et al. Analysis of workflow and time to treatment on thrombectomy outcome in the endovascular treatment for small core and proximal occlusion ischemic stroke (ESCAPE) randomized, controlled trial. *Circulation* 2016;133:2279–86.
- Saber H, Narayanan S, Palla M, et al. Mechanical thrombectomy for acute ischemic stroke with occlusion of the M2 segment of the middle cerebral artery: a meta-analysis. *J Neurointerv Surg* 2018;10:620–4.
- Kurre W, Vorlaender K, Aguilar-Pérez M, et al. Frequency and relevance of anterior cerebral artery embolism caused by mechanical thrombectomy of middle cerebral artery occlusion. *AJNR Am J Neuroradiol* 2013;34:1606–11.
- McTaggart RA, Ospel JM, Psychogios M-N, et al. Optimization of endovascular therapy in the neuroangiography suite to achieve fast and complete (expanded treatment in cerebral ischemia 2c–3) reperfusion. *Stroke* 2020;51:1961–8.
- Grossberg JA, Rebello LC, Haussen DC, et al. Beyond large vessel occlusion strokes: distal occlusion thrombectomy. *Stroke* 2018;49:1662–8.
- Atchaneeyasakul K, Malik AM, Yavagal DR, et al. Thrombectomy outcomes in acute ischemic stroke due to middle cerebral artery M2 occlusion with stent retriever versus aspiration: a multicenter experience. *Interv Neurol* 2020;8:180–6.
- Gory B, Lapergue B, Blanc R, et al. Contact aspiration versus stent retriever in patients with acute ischemic stroke with M2 occlusion in the aster randomized trial (contact aspiration versus stent retriever for successful revascularization). *Stroke* 2018;49:461–4.

- 48 Qureshi AI, Saleem MA, Aytac E. Comparison of endovascular treatment with intravenous thrombolysis for isolated M2 segment of middle cerebral artery occlusion in acute ischemic stroke. *J Vasc Interv Neurol* 2017;9:8–14.
- 49 Sarraj A, Sangha N, Hussain MS, et al. Endovascular therapy for acute ischemic stroke with occlusion of the middle cerebral artery M2 segment. *JAMA Neurol* 2016;73:1291–6.
- 50 Coutinho JM, Liebeskind DS, Slater L-A, et al. Mechanical thrombectomy for isolated M2 occlusions: a post hoc analysis of the StAR, swift, and swift prime studies. *AJNR Am J Neuroradiol* 2016;37:667–72.
- 51 Nakano T, Shigeta K, Ota T, et al. Efficacy and Safety of Mechanical Thrombectomy for Occlusion of the Second Segment of the Middle Cerebral Artery : Retrospective Analysis of the Tama-REgistry of Acute endovascular Thrombectomy (TREAT). *Clin Neuroradiol* 2020;30:481–7.
- 52 Bhogal P, Bücke P, Aguilar Pérez M, et al. Mechanical thrombectomy for M2 occlusions: a single-centre experience. *Interv Neurol* 2017;6:117–25.
- 53 Pérez-García C, Moreu M, Rosati S, et al. Mechanical thrombectomy in medium vessel occlusions: blind exchange with Mini-Pinning technique versus mini stent retriever alone. *Stroke* 2020;51:3224–31.
- 54 Pfaff J, Herweh C, Pham M, et al. Mechanical thrombectomy of distal occlusions in the anterior cerebral artery: recanalization rates, periprocedural complications, and clinical outcome. *AJNR Am J Neuroradiol* 2016;37:673–8.
- 55 Styczen H, Fischer S, Yeo LL, et al. Approaching the Boundaries of Endovascular Treatment in Acute Ischemic Stroke : Multicenter Experience with Mechanical Thrombectomy in Vertebrobasilar Artery Branch Occlusions. *Clin Neuroradiol* 2020. doi:10.1007/s00062-020-00970-7. [Epub ahead of print: 27 Oct 2020].
- 56 Kim CH, Kim S-E, Jeon JP. Meta-Analysis of endovascular treatment for acute M2 occlusion. *J Korean Neurosurg Soc* 2019;62:193–200.
- 57 Chen C-J, Wang C, Buell TJ, et al. Endovascular mechanical thrombectomy for acute middle cerebral artery M2 segment occlusion: a systematic review. *World Neurosurg* 2017;107:684–91.
- 58 Ospel JM, Qiu W, Goyal M. Missed medium-vessel occlusions on CT angiography: make it easier ... easily! *AJNR Am J Neuroradiol* 2020;41:E73–4.
- 59 Fasen BACM, Heijboer RJJ, Hulsmans F-JH, et al. CT angiography in evaluating large-vessel occlusion in acute anterior circulation ischemic stroke: factors associated with diagnostic error in clinical practice. *AJNR Am J Neuroradiol* 2020;41:607–11.