



OPEN ACCESS

## CASE REPORT

# Double-barrel extracranial–intracranial bypass surgery followed by endovascular carotid artery occlusion in a patient with an extracranial giant internal carotid artery aneurysm due to Ehlers–Danlos syndrome

Jason Michael Perrin,<sup>1</sup> Bernd Turowski,<sup>2</sup> Hans-Jakob Steiger,<sup>1</sup> Daniel Hänggi<sup>1</sup>

<sup>1</sup>Department of Neurosurgery, Heinrich-Heine-University, Düsseldorf, Germany  
<sup>2</sup>Department of Radiology, Heinrich-Heine-University, Düsseldorf, Germany

**Correspondence to**

Jason Michael Perrin,  
 Department of Neurosurgery,  
 Heinrich-Heine-University  
 Düsseldorf, Moorenstr 5,  
 Düsseldorf D-40225, Germany;  
 Jason.Perrin@med.uni-  
 duesseldorf.de

Received 22 May 2012

Revised 4 August 2012

Accepted 21 August 2012

**ABSTRACT**

**Objective** In this case report we describe a successful interdisciplinary approach (including flow redirection and endovascular occlusion) applied to a patient with a continuously growing extracranial giant aneurysm of the right internal carotid artery (ICA) due to known Ehlers–Danlos syndrome.

**Case presentation** A 42-year-old man with a continuously growing extracranial giant aneurysm of the right ICA sought treatment after failed surgery of a similar lesion of the left ICA. A multidisciplinary consultation was held at the end of 2008.

**Treatment strategy** The treatment strategy consisted of flow redirection in order to secure sufficient cerebral perfusion prior to surgical trapping of the carotid aneurysm. Flow redirection was achieved by placement of a double-barrel extracranial–intracranial bypass. Subsequent surgical trapping failed due to the extreme size of the aneurysm, making certain identification of surrounding structures impossible. The aneurysm was then successfully occluded by neuroradiological intervention. In a further procedure, a large intra-aneurysmal hematoma was surgically removed to reduce the remaining bulging aneurysm sac.

**Conclusions** This case report describes a successful interdisciplinary approach for the treatment of a rare giant extracranial ICA aneurysm in a patient with Ehlers–Danlos syndrome. Treatment options for this type are few and carry high risks. Flow redirection via extracranial–intracranial bypass followed by endovascular occlusion appears to be a good treatment approach.

**CASE REPORT**

A 42-year-old man with EDS type IV was admitted to our department with a rapidly progressive cervical pulsatile and painful swelling on the right side (figure 1). Apart from the swelling, a neurological examination also showed right-sided palsy of the hypoglossal nerve. The patient's history indicated that, in 1999, direct revascularization using a vessel graft to treat an extracranial giant aneurysm of the left ICA had failed due to technical problems in performing an adequate anastomosis causing left hemispheric ischemia. Neurological impairment such as right-sided hemiparesis or aphasia was not seen at the current presentation.

**Radiology**

Cerebral digital subtraction angiography (DSA) showed a giant aneurysm of the right ICA (C1 segment) measuring 10×7×7 cm, extending from the carotid bifurcation to the base of the skull (figure 2). A largely dilated basal artery and left posterior communicating branch indicating compensatory supply to the left hemisphere was also demonstrated. A Doppler-controlled balloon occlusion test of the right ICA revealed a moderate insufficiency of the middle cerebral artery (MCA) territory and additional collateralization of the right hemisphere via the ophthalmic branches. MRI demonstrated ischemic lesions of the left hemisphere as a result of the previous occlusion of the left ICA.

**Technique**

The radiological findings were then thoroughly discussed in an interdisciplinary conference including neuroradiological, neurological and neurosurgical colleagues in order to achieve a low-risk and adequate treatment of the growing aneurysm of the right ICA. The agreed strategy consisted of securing right cerebral perfusion via flow redirection through a double-barrel extracranial–intracranial bypass followed by surgical trapping of the aneurysm. The double-barrel bypass was successfully placed from the superficial temporal artery to two M4 cortical branches of the right MCA (figure 3). Both branches showed sufficient flow in postoperative angiographic studies. Prior to definite occlusion, a temporary ICA occlusion test was conducted using an eclipse

**INTRODUCTION**

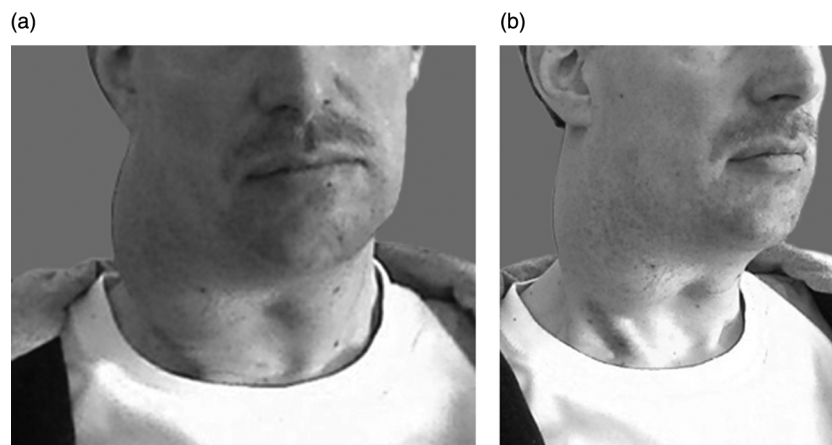
Ehlers–Danlos syndrome (EDS) is a group of inherited connective tissue disorders caused by a defect in collagen synthesis. The clinical presentation varies widely based on the type of EDS.<sup>1</sup> Joints, skin and blood vessels are typically affected, the latter being the problem in the case presented in this paper. Some types of EDS lead to fragile blood vessels resulting in cystic medial necrosis with a high tendency to aneurysms at any location of the vascular system.<sup>2</sup> We report an interdisciplinary treatment approach in a middle-aged man with a continuously growing giant extracranial aneurysm of the right internal carotid artery (ICA) caused by type IV EDS.



Open Access  
 Scan to access more  
 free content

**To cite:** Perrin JM, Turowski B, Steiger H-J, et al. *J NeuroIntervent Surg* 2013;5:e40.

**Figure 1** (A) Frontal and (B) lateral views showing a large pulsatile swelling on the right side of the neck in a patient with Ehlers–Danlos syndrome with a giant extracranial internal carotid artery aneurysm.

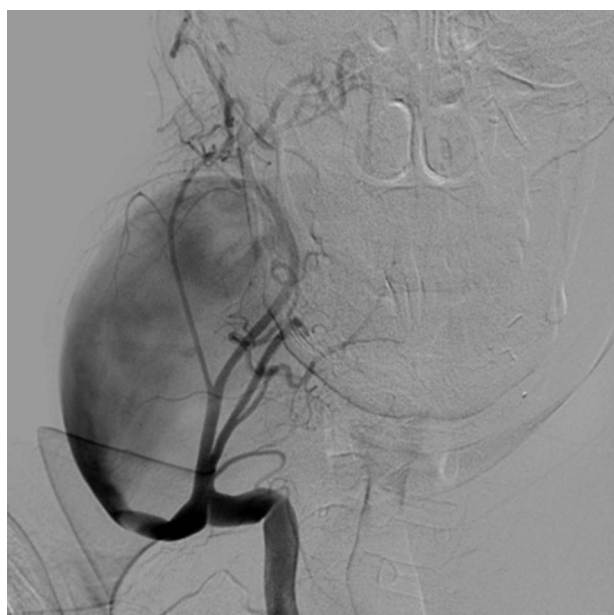

balloon in order to confirm sufficient contrast perfusion of the right hemisphere through the previously placed tandem bypass (figure 4). The occlusion test showed good flow through the bypass and additional ophthalmic collateral filling, so we were able to proceed with the permanent elimination of the aneurysm from the circulation. Surgical trapping of the aneurysm failed due to the risk of sacrificing the external carotid artery. A decision was therefore made to occlude the aneurysm by means of endovascular coiling. Two separate sessions were needed to occlude both the distal and proximal segments of the giant aneurysm. The distal segment was successfully occluded with platinum spiral coils (figure 5). A stent was then placed in the right external carotid artery to secure its patency and, from there, stent-supported coiling was performed to occlude the proximal segment (figure 6). Secure proximal placement of the coils was not possible in a single-catheter technique owing to the high flow turbulence within the aneurysm sac. By using a double-catheter method, two coils could be placed simultaneously directly outside the stent wall facing the proximal segment of the extracranial ICA. Immediately after the procedure the patient had a

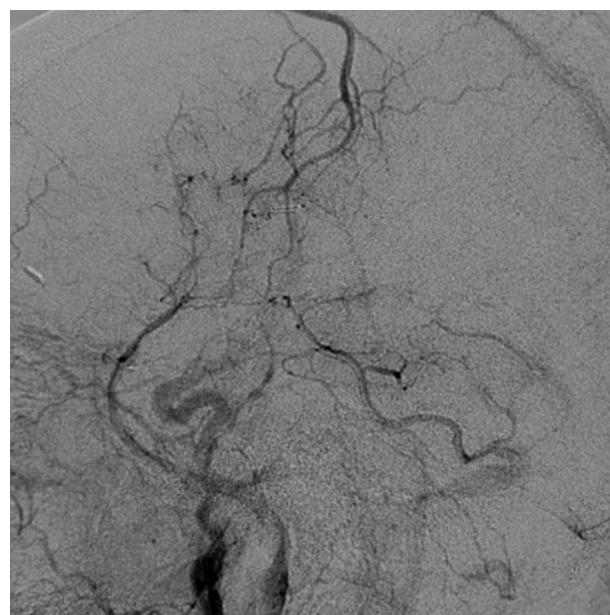
transient ischemic attack with latent left-sided hemiparesis which regressed within 48 h. Ischemic lesions were excluded in post-procedural non-enhancement CT scans. Minor surgery was later performed to drain the residual hematoma in the aneurysm sac. The bulging skin collapsed instantly, reducing the large visible swelling on the patient's neck. The patient recovered rapidly from the individual procedures without any additional impairment and was discharged in an unaltered clinical/neurological condition.

#### Clinical follow-up

Follow-up at 2 months revealed a good clinical result without any deficits with slight recurrence of the swelling on the right side of the neck. CT and CT angiography showed a hypodense non-enhancing filling of the remaining aneurysm sac. Density measurements indicated the filling to be serous fluid which was safely drained via CT-assisted puncture. Again the swelling collapsed immediately, leaving the patient with a good cosmetic result (figure 7). The patient died a year later due to a ruptured aneurysm of the splenic artery.

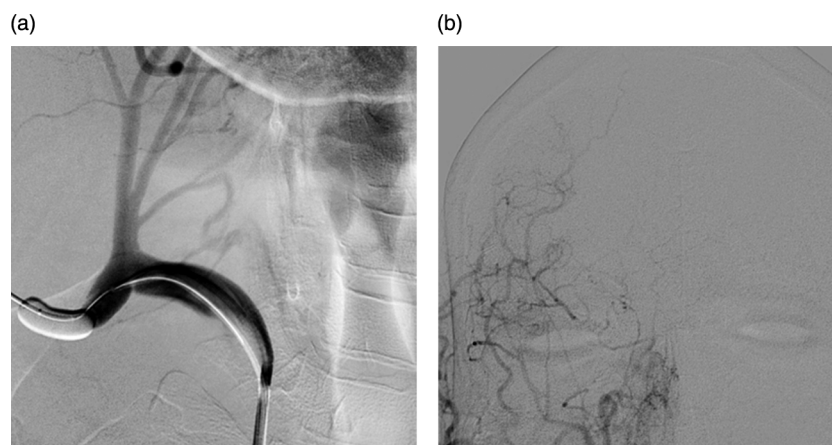


**Figure 2** Angiographic study prior to treatment showing the contrast in the giant extracranial internal carotid artery aneurysm measuring 10×7×7 cm.



**Figure 3** Angiographic study demonstrating patent superficial temporal artery–middle cerebral artery bypass with sufficient contrast (lateral view).

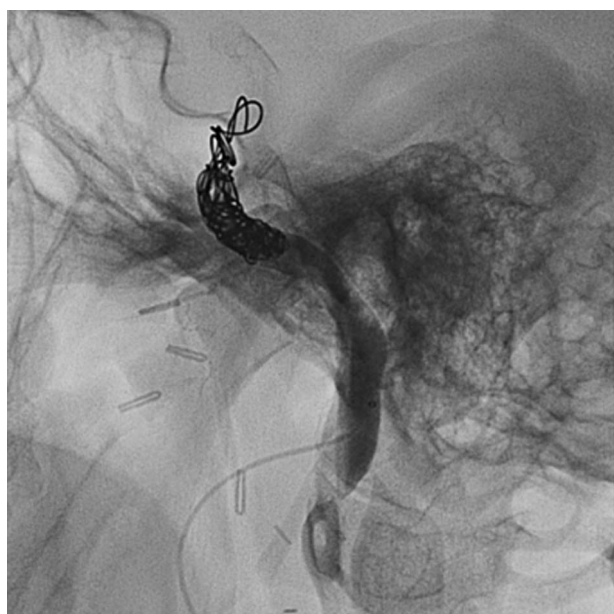**Figure 4** (A) Internal carotid artery (ICA) occlusion test during cerebral angiography. (B) Anteroposterior view of patent contrast via extracranial–intracranial bypass during temporary ICA occlusion.



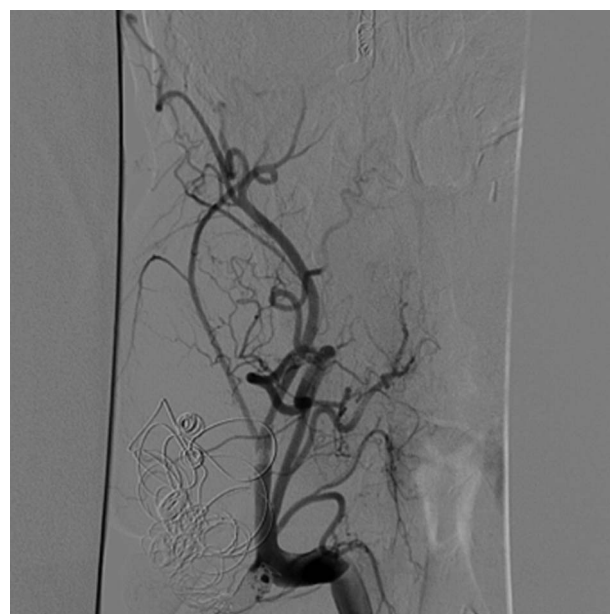## DISCUSSION

Extracranial giant ICA aneurysms are rare lesions and treatment is often accompanied by a high risk of morbidity and mortality.<sup>3–4</sup> Surgical resection with reconstruction is considered to be the best therapeutic option for these extracranial vascular pathologies.<sup>4–5</sup> In the case presented here, surgical treatment had been attempted for a similar lesion of the left EICA but failed due to the dimensions of the lesion and led to ischemic stroke. An alternative treatment method for the abovementioned lesion of the right EICA in this patient was therefore sought. A well-accepted approach for giant and complex intracranial ICA aneurysms is the combination of flow redirection followed by definite exclusion of the aneurysm from the circulation.<sup>6–8</sup> A transcranial Doppler-controlled balloon occlusion test performed during the initial diagnostic angiography revealed moderate insufficiency of the right MCA territory, so a STA–MCA bypass was seen as adequate in this case. After interdisciplinary consultation, we decided to apply this combined approach to this extracranial ICA aneurysm in order to prevent further ischemic events.

Exclusion from the circulation can be achieved either through surgical trapping or by endovascular occlusion.<sup>6–9–10</sup> Both methods are reported to be equally acceptable. Extracranial–intracranial bypass and aneurysm exclusion can be carried out as a single-stage or two-stage procedure.<sup>11</sup> If aneurysm exclusion is performed as surgical trapping, the single-stage procedure under a single anesthesia is the more common protocol.<sup>11</sup> To avoid the increased risk of postoperative bleeding, a two-stage procedure with anticoagulation after the endovascular occlusion of the aneurysm should be considered. Given the fact that the patient had already had an ischemic stroke of the left hemisphere due to ICA ligation after failed surgery, we decided to apply the aforementioned standard methods for intracranial ICA aneurysms to this giant aneurysm of the right EICA. At first we chose a single-stage strategy in which we planned to place an extracranial–intracranial bypass with subsequent open surgical trapping in one procedure. Trapping failed again due to the extreme dimensions of the aneurysm at the bifurcation, making it impossible to trap the aneurysm and not the external ICA. As mentioned above, endovascular occlusion is a well-accepted




**Figure 5** Angiographic study showing coiling of the distal segment of the right internal carotid artery (lateral view).



**Figure 6** Angiographic study showing stent-assisted proximal occlusion of the right internal carotid artery.





**Figure 7** Photograph showing reduction of the swelling on the right side of the neck after drainage of the residual hematoma at clinical follow-up.

treatment method in combination with bypass for intracranial aneurysms which has not previously been used in a patient with EDS with an extracranial ICA aneurysm. This combined surgical and endovascular approach presented a valid alternative. Occlusion was successfully performed in two separate endovascular procedures (distal coiling followed by proximal stent-assisted coiling).

There are few reports of the use of this method for the treatment of extracranial ICA aneurysms in the literature, and this is the first report of its use in a patient with type IV EDS.

## CONCLUSIONS

A combination of flow redirection using cerebral bypass surgery and endovascular occlusion is a rational treatment method for intracranial aneurysms and also seems to be a valid option for high-risk extracranial giant ICA aneurysms, even in a patient with EDS.

**Contributors** JMP performed the analyses on all samples, interpreted the data, wrote the manuscript and acted as corresponding author. BT contributed to planning of the article and critical evaluation. HJS and DH supervised development of the work, helped with data interpretation and manuscript evaluation. All authors approved the final version of the manuscript.

**Competing interests** None.

**Patient consent** Obtained.

**Provenance and peer review** Not commissioned; externally peer reviewed.

**Open Access** This is an Open Access article distributed in accordance with the Creative Commons Attribution Non Commercial (CC BY-NC 3.0) license, which permits others to distribute, remix, adapt, build upon this work non-commercially, and license their derivative works on different terms, provided the original work is properly cited and the use is non-commercial. See: <http://creativecommons.org/licenses/by-nc/3.0/>

## REFERENCES

- 1 Castori M, Camerota F, Celletti C, *et al.* Natural history and manifestations of the hypermobility type Ehlers-Danlos syndrome: a pilot study on 21 patients. *Am J Med Genet* 2010;152A:556–64.
- 2 Lawrence EJ. The clinical presentation of Ehlers-Danlos syndrome. *Adv Neonatal Care* 2005;5:301–14.
- 3 Blanco E, Serrano FJ, Reina R, *et al.* Saccular aneurysms of the extracranial internal carotid artery. Experience and review of the literature. *J Cardiovasc Surg (Torino)*. 2008;49:73–8.
- 4 El-Sabroun R, Cooley DA. Extracranial carotid artery aneurysms: Texas Heart Institute experience. *J Vasc Surg* 2000;31:702–12.
- 5 Moreau P, Albat B, Thevenet A. Surgical treatment of extracranial internal carotid artery aneurysm. *Ann Vasc Surg* 1994;8:409–16.
- 6 Drake CG. Giant intracranial aneurysms: experience with surgical treatment in 174 patients. *Clin Neurosurg* 1979;26:12–95.
- 7 Gelber BR, Sundt TM Jr. Treatment of intracavernous and giant carotid aneurysms by combined internal carotid ligation and extra- to intracranial bypass. *J Neurosurg* 1980;52:1–10.
- 8 Spetzler RF, Schuster H, Roski RA. Elective extracranial-intracranial arterial bypass in the treatment of inoperable giant aneurysms of the internal carotid artery. *J Neurosurg* 1980;53:22–7.
- 9 Sundt TM Jr., Piepgras DG. Surgical approach to giant intracranial aneurysms. Operative experience with 80 cases. *J Neurosurg* 1979;51:731–42.
- 10 Swearingen B, Heros RC. Common carotid occlusion for unclippable carotid aneurysms: an old but still effective operation. *Neurosurgery* 1987;21:288–95.
- 11 Serbinenko FA, Filatov JM, Spallone A, *et al.* Management of giant intracranial ICA aneurysms with combined extracranial-intracranial anastomosis and endovascular occlusion. *J Neurosurg* 1990;73:57–63.