






OPEN ACCESS

Original research

# Non-ischemic cerebral enhancing (NICE) lesions after flow diversion for intracranial aneurysms: a multicenter study

Cindy Richter <sup>1</sup>, Markus A Möhlenbruch,<sup>2</sup> Dominik F Vollherbst <sup>2</sup>, Christian A Taschner,<sup>3</sup> Samer Elsheikh <sup>3</sup>, Joachim Klisch,<sup>4</sup> Donald Lobsien,<sup>4</sup> Maxim Bester,<sup>5</sup> Nora Ramdani,<sup>5</sup> Daniel P O Kaiser,<sup>6</sup> Johannes C Gerber,<sup>6</sup> Stefan Schob,<sup>7</sup> Angelos Gazis,<sup>8</sup> Paulina Smirnov,<sup>1</sup> Cordula Scherlach,<sup>1</sup> Karl-Titus Hoffmann,<sup>1</sup> Matthias Gawlitza<sup>1</sup>

For numbered affiliations see end of article.

## Correspondence to

Dr Cindy Richter, Institute of Neuroradiology, University Hospital Leipzig, Leipzig 04103, Germany; cindy.richter@medizin.uni-leipzig.de

Received 31 October 2023  
Accepted 19 December 2023

## ABSTRACT

**Background** Non-ischemic cerebral enhancing (NICE) lesions have been reported as a rare complication of various neuroendovascular procedures, but information on their incidence after flow diversion is scant. It is unclear if specific devices or novel coating technologies may impact their occurrence.

**Methods** We conducted a multicenter study on the incidence of NICE lesions after flow diverter (FD) implantation for cerebral aneurysm treatment.

**Results** Eight centers identified 15 patients and provided detailed data. The clinical presentation ranged from asymptomatic to hemiplegia and cognitive impairment. The mean time to diagnosis after treatment was 65.1±101.5 days. Five centers disclosed information on all of their 1201 FD procedures during the inclusion period (2015–2022), during which 12 patients were diagnosed with NICE lesions in these institutions—that is, an incidence of 1%. FD coatings did not increase the incidence (6/591 patients (1%) treated with surface-modified FD vs 6/610 patients (1%) treated with bare FD;  $P=1.00$ ). Significantly increased rates of 3.7% (6 cases in 161 procedures;  $P<0.01$ ) and 3.3% (5 cases in 153 procedures;  $P<0.01$ ) were found with stents of two specific product lines. The use of one product line was associated with a significantly lower incidence (0 cases in 499 procedures (0%);  $P<0.01$ ).

**Conclusions** Novel stent coatings are not associated with an increased incidence of NICE lesions. The incidence rate of 1% suggests that these lesions may occur more often after flow diversion than after other endovascular treatments. We found a concerning accumulation of NICE lesion cases when FDs from two product families were used.

## INTRODUCTION

The rarely encountered delayed non-ischemic cerebral enhancing (NICE) lesions have been documented as a complication following ruptured and unruptured aneurysm embolizations and other neuroendovascular procedures.<sup>1–12</sup> They are defined as punctate, nodular, or circular enhancements of the brain parenchyma or the leptomeninges with or without perilesional edema with a distribution primarily in the vascular territory of

## WHAT IS ALREADY KNOWN ON THIS TOPIC

⇒ Non-ischemic cerebral enhancing (NICE) lesions occur after various types of endovascular procedures and manifest as an inflammatory reaction to hydrophilic polymer embolic materials. Series encompassing a broad spectrum of interventions report on incidences ranging from 0.05% up to 2.3%, but specific data on the incidence of NICE lesions after flow diversion, particularly when using novel polymer-based coated devices, are scarce.

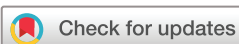## WHAT THIS STUDY ADDS

⇒ With an incidence of 1%, NICE lesions may occur more frequently after flow diversion than after other procedures. While stent coatings were not associated with an increased incidence, there was an accumulation of cases when devices from two product families were used.

## HOW THIS STUDY MIGHT AFFECT RESEARCH, PRACTICE OR POLICY

⇒ With regard to NICE lesions, novel coating technologies seem to be safe. However, our data are concerning and should initiate further research; in particular, bench tests on particle generation with transparent publication of the results are needed.

the endovascular procedure.<sup>1</sup> Although they can be completely asymptomatic, these lesions can be associated with considerable morbidity and often require long-term pharmacological treatment. Compelling evidence, confirmed through biopsy, indicates that these lesions manifest as granulomatous reactions, probably to hydrophilic polymer embolic material.<sup>8</sup> This material probably originates in either the inner or the outer layer of the catheters used during the procedure, or even from the devices themselves. Comprehensive information on NICE lesions after aneurysm treatment remains scant, primarily sourced from isolated case reports and concise case series with only one large series covering this important topic.<sup>2</sup>



© Author(s) (or their employer(s)) 2024. Re-use permitted under CC BY-NC. No commercial re-use. See rights and permissions. Published by BMJ.

**To cite:** Richter C, Möhlenbruch MA, Vollherbst DF, et al. *J NeuroIntervent Surg* Epub ahead of print: [please include Day Month Year]. doi:10.1136/jnis-2023-021176

Additionally, there are limited data available concerning the incidence of these lesions after treatment with flow diverters (FDs), a topic of particular interest as, over the past decade, this technique has emerged as a reliable therapeutic concept for cerebral aneurysms.<sup>13–16</sup> This technique has developed into a routine procedure. It is applied to treat a wide range of aneurysms beyond the initial indications (i.e., complex and giant aneurysms of the intracranial internal carotid artery (ICA)).<sup>17–19</sup>

In this study we sought to collect multicenter data on NICE lesions after aneurysm treatment with FDs. Our objective was to calculate the incidence of these lesions and to identify possible procedural factors associated with their occurrence. Moreover, we aimed to investigate if recently introduced stent coating technologies, considered a major leap in technological advance, could increase the incidence of NICE lesions.

## METHODS

### Survey

We conducted a retrospective multicenter study and included all patients above 18 years of age who received endovascular aneurysm treatment using an intravascular FD between January 1, 2015 and December 31, 2022. Intracranial flow-disrupting devices were excluded from the study. A survey was sent to 23 neurointerventional centers in Germany. NICE lesions were defined according to Shotar *et al*<sup>2</sup>: symptomatic or asymptomatic punctate, nodular, or circular enhancements of the brain parenchyma or the leptomeninges with or without perilesional edema with a distribution primarily in the vascular territory of the endovascular procedure. It was imperative that no other confounding factor could explain the clinical and imaging findings. Demographic, clinical, procedure-related, therapeutic, and follow-up data were collected retrospectively. We asked for the following data: patient characteristics (ie, age, sex, comorbidities, allergies, smoking habits); aneurysm characteristics (ie, location, maximum diameter, presentation (incidental, compressive symptoms, ruptured)); procedural characteristics (ie, catheter materials, implanted and ancillary devices); NICE lesion MRI characteristics (ie, number of lesions, perilesional edema, presence of lesions beyond the primarily targeted vascular territory).

Moreover, we collected information about the symptomatology of the NICE lesions including modified Rankin Scale (mRS) scores, and gathered details on the medical treatment regimens and the clinical and imaging follow-up. The centers were additionally invited to provide information on the number and type of FD used during the inclusion period. For the purpose of this study, the following surface modifications, listed with their vendor name, were considered as coating: Shield (Medtronic), Hydrophilic Polymer Coating (HPC, phenox), Heal (Acandis), X-coating (Microvention); the so-called BlueXide by Acandis was not considered a coating as it consists of a surface modification by electropolishing and heating.<sup>20</sup>

### Statistical analysis

Statistical analyses were performed with SPSS version 25.0 (IBM Corporation, New York, New York, USA). We calculated the incidence of NICE lesions based on the reported numbers of NICE cases in the complete sample. Vendor-specific incidences were additionally calculated. Statistical analyses were executed using Fisher's exact test;  $p < 0.05$  was defined as the threshold for statistical significance.

## RESULTS

### Patients and aneurysms

Eight of the 23 centers reported 15 cases with NICE lesions. There was an equal distribution regarding gender (n=8, 53.3%) female patients) and smoking (n=8, 53.3%) patients were smokers). Four patients (26.7%) had previously known allergies and seven patients (46.7%) had various comorbidities. Baseline characteristics and patient demographics are shown in [table 1](#).

All aneurysms were located in the anterior circulation: two (13.3%) were located at the infra-ophthalmic and 10 (66.7%) at the para-ophthalmic or supra-ophthalmic ICA. Three had a middle cerebral artery location (20.0%). The maximum diameter of the aneurysms varied from 1 mm (in the case of a ruptured blister-like aneurysm) to 45 mm (mean  $\pm$  SD 14.9  $\pm$  14.0 mm).

### Procedural characteristics

Patients were treated with either primary flow diversion (n=9, 60.0%), FD after initial coiling of the target aneurysm during a previous session (n=5, 33.3%), or FD after initial stent-assisted coiling (n=1, 6.7%). Four patients (26.7%) had a history of aneurysmal subarachnoid hemorrhage: one with a blister-like aneurysm of the ICA (6.7%) underwent flow diversion in the acute phase of the subarachnoid hemorrhage and the three remaining patients (20.0%) were treated with FDs for an aneurysm remnant or reappearance following primary coil embolization in the acute setting.

### Material characteristics

Detailed information on the relevant materials used for treatment of the 15 reported cases is summarized in [table 2](#). Of the eight centers contributing to the study, five were able to provide information concerning the exact numbers of all FD devices used during the study period. Altogether, 1201 patients were treated using FDs for intracranial aneurysms in these five centers. Almost all available kinds of FD from almost all vendors were used.

- ▶ Acandis, Pforzheim, Germany: DERIVO/DERIVO 2: n=151; DERIVO 2heal: n=2.
- ▶ Balt Extrusion, Montmorency, France: SILK: n=16; SILK Vista Baby: n=91.
- ▶ Medtronic Neurovascular, Irvine, USA: Pipeline Embolization Device (PED): n=17; PED Flex Shield: n=120; PED Vantage Shield: n=24.
- ▶ Microvention, Aliso Viejo, USA: FRED: n=152; FRED Jr: n=18; FRED X: n=74.
- ▶ phenox, Bochum, Germany: p48 MW: n=16; p48 MW HPC: n=212; p64/p64 MW: n=93; p64 MW HPC: n=178.
- ▶ Stryker Neurovascular, Kalamazoo, USA: Surpass Streamline: n=37.

In total, 591 (49.2%) procedures were executed using coated stents. Bare stents were used in 610 (50.8%) procedures.

### Incidence of NICE lesions

In the five centers providing complete information, the incidence of NICE lesions after FD treatment of intracranial aneurysms was 1% (12 patients in 1201 procedures). It must be noted that, in each of the three centers that could not provide detailed data on their case numbers, one patient was diagnosed with NICE lesions.

There were differences in the occurrence of NICE lesions between device families, as shown in [table 3](#). A significantly higher incidence was observed in patients treated with

**Table 1** Baseline demographics

	Details	N (in %) or mean (range) $\pm$ SD
Demographic data	n	15
	Age, years	49.2 (19–68) $\pm$ 15.2
	Women	8 (53.3)
	Smoker	8 (53.3)
	Allergies	Nickel (n=2), NSAID (n=1), penicillin (n=1), pollinosis (n=2)
	Systemic diseases	Asthma (n=1), CHD (n=1), cancer (n=2), diabetes (n=1), hypertension (n=2), hypercholesterinemia (n=2), RLS (n=1), hypothyroidism (n=1), anemia (n=1)
EVT	Primary flow diversion	9 (60)
	Flow diversion after coiling	5 (33.3)
	Flow diversion after stent-assisted coiling	1 (6.7)
NICE lesions	MRI characteristics	
	Onset after EVT (days)	65.1 (1.0–358.0) $\pm$ 101.5
	Last follow-up (days)	548.2 (23.0–1339.0) $\pm$ 467.0
	No. of enhancing lesions	1 lesion 2–5 lesions 6–10 lesions >10 lesions
	Perilesional edema	8 (53.3)
	Midline shift	1 (6.7)
	Patients with lesions outside the vascular territory of treatment	4 (26.7)
	Symptoms	
	Headache	5 (33.3)
	Focal neurological deficit	Hemiplegia and hemihypesthesia, neglect (n=1), impaired coordination and walking (n=1), vertigo and visually initiated seizures (n=1)
	Epileptic seizures	2 (13.3)
	Cognitive impairment	2 (13.3)
	Symptom dynamics	Progression Completely resolved Partially resolved Stable
	Treatment	
	None	9 (60.0)
	Glucocorticoids	Combined with ibuprofen (n=1)
	Antiepileptic drugs	2 (13.3)

CHD, coronary heart disease; EVT, endovascular treatment; No., number; NSAID, non-steroidal anti-inflammatory drug; RLS, restless legs syndrome.

FDs from the Pipeline (6 cases in 161 procedures, 3.7%;  $p < 0.01$ ) and Derivo (5 cases in 153 procedures, 3.3%;  $p < 0.01$ ) product lines. Significantly fewer cases with NICE lesions occurred after treatment with FDs from the phenox product family (0 cases in 499 procedures, 0.0%;  $p < 0.01$ ). This statistical significance would also have remained valid when taking the single case after treatment with a p64 MW HPC treatment (see [table 2](#)) into account, which could not be included in the statistical analysis due to lack of data from the center (hypothetical calculation: 1 case in 500 procedures, 0.2%;  $p < 0.05$ ). No statistical significance was observed for other product families. Likewise, FD coatings were not associated with an increased number of patients with NICE lesions (see [table 4](#)): six of 591 patients (1.0%)

treated with surface-modified FD versus six of 610 patients (1.0%) treated with bare stents ( $p = 1.00$ ).

### NICE lesion characteristics

Before endovascular treatment, all patients were asymptomatic or mildly symptomatic: 14 (93.3%) patients had mRS scores of 0 and one patient (6.7%) had a mRS score of 1. The mean delay between the endovascular treatment and the first MRI confirming NICE lesions was  $65.1 \pm 101.5$  days. Headache ( $n = 5$ , 33.3%) was observed to be the most common symptom leading to the diagnosis of NICE lesions. Further symptoms included epileptic seizures ( $n = 2$ , 13.3%), cognitive impairment ( $n = 2$ , 13.3%), and focal neurological deficits ( $n = 3$ , 20.0%). However, eight

**Table 2** Materials

Patient	Flow diverter	Coating	Guide catheter	Distal access catheter	Microcatheter	Other material
1	Derivo (Acandis)	No	Envoy (Cerenovus)	AXS Catalyst 5F (Stryker)	Headway 27 (Microvention)	
2	Derivo (Acandis)	No	Vista Brite Tip (Cordis)		Headway 27 (Microvention)	Neurospeed (Acandis), Gateway (Boston Scientific)
3	Derivo (Acandis)	No		AXS Catalyst 5F (Stryker)	Headway 27 (Microvention)	Scepter C (Microvention)
4	Derivo 2 (Acandis)	No	NeuronMAX (Penumbra)	ReFlex A+ (Reverse Medical)	Neuroslider 27 (Acandis), Excelsior XT 27 (Stryker)	Flow diversion following coiling 7 months earlier
5	Derivo 2 Heal (Acandis)	Yes	RIST (Medtronic)	AXS Catalyst 5F (Stryker)	Headway 27 (Microvention)	Solitaire (Medtronic)
6	P64 HPC MW (phenox)	Yes	Envoy (Cerenovus)	Sofia 5F (Microvention)	Rebar 18 (Medtronic)	Flow diversion following stent-assisted coiling 4 months earlier
7	Pipeline (Medtronic)	No	Envoy (Cerenovus)		Marksman (Medtronic)	Hyperglide (ev3)
8	Pipeline Flex Shield (Medtronic)	Yes		Navien 5F (Medtronic)	Phenom 27 (Medtronic), Excelsior SL 10 (Stryker)	Additional coils
9	Pipeline Flex Shield (Medtronic)	Yes	NeuronMAX (Penumbra)	Sofia 6F (Microvention)	Phenom 27 (Medtronic)	Flow diversion following coiling 6 months earlier
10	Pipeline Flex Shield (Medtronic)	Yes	NeuronMAX (Penumbra)	Sofia 6F (Microvention)	Phenom 27 (Medtronic)	
11	Pipeline Flex Shield (Medtronic)	Yes	NeuronMAX (Penumbra)	Sofia EX (Microvention)	Phenom 27 (Medtronic)	
12	Pipeline Vantage Shield (Medtronic)	Yes	Vista Brite Tip (Cordis)	Navien 5F (Medtronic)	Phenom 27 (Medtronic), Echelon 10 (ev3)	Additional coils
13	Pipeline Vantage Shield (Medtronic)	Yes	NeuronMAX (Penumbra)	Sofia 6F (Microvention)	Phenom 21 (Medtronic)	
14	Pipeline Vantage Shield (Medtronic)	Yes	NeuronMAX (Penumbra)	Sofia EX (Microvention)	Phenom 21 (Medtronic)	
15	Surpass Streamline (Stryker)	none	Vista Brite Tip (Cordis)	Navien 5F (Medtronic)	Excelsior 1018 (Stryker)	

patients (53.3%) remained asymptomatic and NICE lesions were discovered only on routine follow-up imaging. In the baseline MRI scan, a single enhancing lesion was diagnosed in four patients (26.7%), and eight patients (53.3%) presented with more than 10 enhancing lesions. Two initial MRIs were performed without contrast medium

and NICE lesions were then confirmed in follow-up MRI studies during which gadolinium was administered. In eight patients (53.3%), perilesional edema was described. In one patient the initial scan confirmed a midline shift (6.7%). Five patients (33.3%) had enhancing lesions outside the targeted vascular territory.

**Table 3** Fisher’s exact test for flow diverting stents

Product	Coating	Centers, n	Procedures, n (%)	Cases with NICE lesions, n (%)	Product family, N (%)	Cases with NICE lesions, n (%)	P values *
DERIVO/DERIVO 2	None	2	151 (12.6)	4 (33.3)	153 (12.7)	5 (41.7)	0.01†
DERVO 2heal	Fibrin-based nanocoating	1	2 (0.2)	1 (8.3)			
FRED	None	3	152 (12.7)	0 (0.0)	244 (20.3)	0 (0.0)	0.14
FRED Jr.	None	2	18 (1.5)	0 (0.0)			
FRED X	Nanoscale surface	2	74 (6.2)	0 (0.0)			
PED	None	3	17 (1.4)	1 (8.3)	161 (13.4)	6 (50.0)	0.00‡
PED Shield	Phosphorylchlorine	2	120 (10.0)	3 (25.0)			
PED Vantage	Phosphorylchlorine	2	24 (2.0)	2 (16.7)			
p48 MW	None	2	16 (1.3)	0 (0.0)	499 (41.5)	0 (0.0)	0.00‡
p48 HPC	Hydrophilic polymer	4	212 (17.7)	0 (0.0)			
p64/p64 MW	None	4	93 (7.7)	0 (0.0)			
p64 HPC	Hydrophilic polymer	3	178 (14.8)	0 (0.0)			
SILK	None	1	16 (1.3)	0 (0.0)	107 (8.9)	0 (0.0)	0.62
SILK Vista Baby	None	2	91 (7.6)	0 (0.0)			
SURPASS Streamline	None	2	37 (3.1)	1 (8.3)	37 (3.1)	1 (8.3)	0.32
<b>Overall</b>		<b>5</b>	<b>1201 (100.0)</b>	<b>12 (100.0)</b>			

\*p values were calculated with the Fisher’s exact test using four-field tables, comparing the incidence of NICE lesions associated with the respective device with the entire sample.

†Significant p<0.05.

‡Highly significant p<0.01.

NICE, non-ischemic cerebral enhancing.



**Table 4** Fisher's exact test for coated versus non-coated devices

Product	Company	Coating	Centers, N	Procedures, N (%)	Cases with NICE lesions, N (%)	Incidence, %	P value
DERIVO 2heal, FRED X, PED Shield, PED Ventage, p48 HPC, p64 HPC	All except BALT and Stryker	Coated	5	591 (49.2)	6 (50.0)	1.0	1.00
DERIVO/ DERIVO 2, FRED, FRED Jr, PED, p48 MW, p64/p64 MW, SILK, SILK Vista Baby, SURPASS Streamline	All	Non-coated	5	610 (50.8)	6 (50.0)	1.0	

\*Significant  $p < 0.05$ .  
†Highly significant  $p < 0.01$ .  
NICE, non-ischemic cerebral enhancing.

### NICE lesion treatment

Six patients (40.0%) were treated with glucocorticoids. In one of the cases this was combined with additional non-steroidal anti-inflammatory drugs. In two cases, epileptic seizures were treated with additional antiepileptic treatment. Nine patients did not receive any medical treatment.

### Follow-up

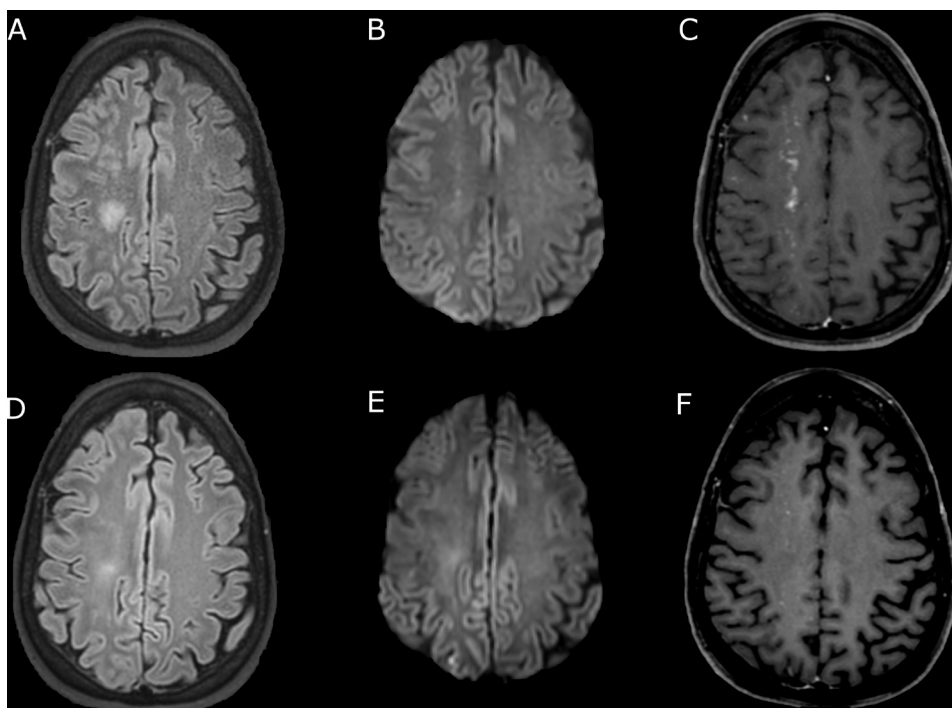
The follow-up period varied from 23 days to 3.5 years (mean  $\pm$  SD 548.2  $\pm$  467.0 days). Nine asymptomatic patients (60.0%), including two patients presenting with headaches and two patients with mild neurological symptoms (13.3%), did not develop further symptoms and remained stable. A symptom progression was seen in three patients (20.0%), leading to impaired memory and coordination. The patient with initially the most severe symptoms (see illustrative case below) and a second patient recovered completely (13.3%), while symptoms only resolved partially in one patient (6.7%).

Only one asymptomatic patient did not receive control imaging. In four cases (26.7%) the non-enhancing lesions resolved entirely and in seven cases (46.7%) they resolved

partially. In two cases (13.3%) the imaging findings remained unchanged and in one case (6.7%) a progression despite treatment was noted.

### Illustrative case

An otherwise healthy person in their 40s with a previously unremarkable medical history presented with severe headaches 12 days after a complication-free endovascular treatment of a right-sided incidental para-ophthalmic ICA aneurysm (3 mm) using a FD. As emergency CT scans were unremarkable, the patient was discharged and medication with 100 mg aspirin daily and 90 mg ticagrelor twice a day was continued as per postoperative discharge. At the time the patient had no focal neurological deficit. Within 3 days the status deteriorated. The person displayed decreased vigilance, visual disturbances, left hemiparesis, and left hemihypesthesia, rapidly progressing to left side hemiplegia (mRS 4). The patient was readmitted in an intubated and ventilated status. Epileptic action potentials were ruled out by EEG. There was no perfusion deficit and no vessel occlusion in multimodal CT imaging. The CT scan showed an edema in the right hemisphere. An emergency MRI showed multiple



**Figure 1** Baseline (top row) and follow-up (bottom row) MRI with a 2-week interval. Presented are T2 FLAIR weighted sequences (A, D), diffusion-weighted imaging (B, E), and gadolinium-enhanced T1 weighted sequences (C, F). The top row (A–C) shows the typical aspect of the non-ischemic enhancing (NICE) lesions after contrast administration with punctuate to patchy enhancement in the right watershed zone and subcortical white matter of the right middle cerebral artery territory with only focal edema. The bottom row (D–F) shows a significant regression of the NICE lesions and edema. Punctuate cortical diffusion restriction was explained by post-interventional emboli.

enhancing white matter lesions partially surrounded by edema in the right frontal and parietal lobes (figure 1). Seven additional punctate cortical lesions with restricted diffusion and without enhancement were rated as post-therapeutic microemboli. There was a vascular distribution in the right carotid artery, predominating the middle cerebral artery territory and watershed zone. Serum and spinal fluid analyses were negative for infections. Oral corticosteroid treatment was started (3×80 mg prednisolone for 2 weeks with a gradual dosage decrease) and the symptoms resolved almost completely. A mild impairment of fine motor skills remained at discharge (mRS 1). Follow-up MRI after 2 weeks showed subtotal regression of the NICE lesions (figure 1). The anti-inflammatory treatment was changed to 200 mg celecoxib twice a day before discharge. Approximately 6 months after treatment the last follow-up imaging was performed externally without contrast medium. Some focal FLAIR hyperintensities remained in the deep white matter. Clinically, the patient recovered completely.

## DISCUSSION

In this study we present the second largest case series on NICE lesions to date and the largest series specifically regarding flow diversion, which is of particular interest as FDs are increasingly used to treat various aneurysms and their use will likely further increase in the future.<sup>21</sup> For example, Cruz *et al* reported in their case series on two of seven patients treated with FDs,<sup>22</sup> three of six patients were treated with FDs in the series by Bayas *et al*,<sup>4</sup> and six of 32 patients were treated with FDs in the largest case series to date by Shotar *et al*.<sup>2</sup>

Biopsy-confirmed cases have shown that NICE lesions result from granulomatous foreign body reactions to microemboli formed by hydrophilic polymer coatings. The biopsies unveiled a spectrum of pathological findings including granulomas, angiitis, a periadventitial response characterized by giant cells reacting to foreign bodies, and microabscesses encapsulating foreign material, along with neutrophilic granulocytes and multinucleated macrophages.<sup>12 23</sup> Various types of hydrophilic polymer materials, including polytetrafluoroethylene, polyvinylpyrrolidone, polyacrylamide, polyoxyethylene, and polysaccharides, are now widely used as surface coatings on endovascular catheters and devices.<sup>2 23 24</sup> These coatings serve to reduce friction with vessel walls and other devices, enhancing maneuverability within the vasculature. However, a ‘simple’ embolus of foreign material cannot be the only possible problem, as is shown in our own series in which a significant proportion of patients were diagnosed with NICE lesions in a different vascular territory. Moreover, why some patients develop inflammatory symptoms and others do not can only be speculated. Previous hypotheses stating that these lesions presented as a type of nickel allergy have been rebutted.<sup>3</sup> This is also supported by our case series, as the majority of patients with NICE lesions were treated with FDs made of cobalt-chromium and not nickel-titanium.

In our large cohort of patients the incidence of NICE lesions was at the upper end of the spectrum of previously reported numbers. We observed a rate of 1%, which stands in contrast to previous larger studies on various neuroendovascular procedures in which incidence rates of 0.05%<sup>2</sup> or 0.14% were described.<sup>11</sup> Other studies report rates more comparable with our case series: Nakagawa *et al* described an incidence of 2.3% in a series of 305 patients and Ikemura *et al* found NICE lesions in 0.9% of patients after 1754 coil embolizations.<sup>9 10</sup> One must note, however, that our data are prone to bias as, of 23 centers, eight responded to our query and we do not know if any cases with NICE lesions were detected in the other centers or if the centers

did not contribute their cases. On the other hand, it is almost certain that NICE lesions are an underreported finding. In our series more than half of the patients were asymptomatic and their lesions were diagnosed on routine follow-up imaging. It should be noted that MRI is not part of the standard follow-up protocol in all participating centers—for example, the center of the senior author relies heavily on DSA follow-up and only switches to MR or CT angiography after completion of the regular DSA routine after 24 months for further non-invasive imaging. Accordingly, only symptomatic patients were diagnosed at that center. Thus, the incidence of NICE lesions after FD treatment may be even higher than the reported 1%. Our data suggest that NICE lesions may occur more often after FD treatment than after other procedures, taking the bias of a retrospective study into account.

Not only did we observe a surprisingly high overall incidence of NICE lesions after FD treatment, but the majority of affected patients were also treated with one of two particular device lines—namely, the Pipeline devices and the Derivo devices—with statistically significantly higher incidences of 3.7% and 3.3%, respectively. On the other hand, the product line by phenox was associated with statistically lower incidences of 0% (0.2% taking the single case from a center that could not provide detailed information on case numbers into account). We can rule out that the device material itself is responsible for these differences, as both Acandis and phenox produce their FDs from a nickel-titanium alloy. In contrast, the Pipeline from Medtronic consists of cobalt-chromium. However, we can only speculate on the reason for this particular finding and provide the following hypotheses. (1) Our findings may be a mere coincidence; however, in that case the difference of such a magnitude would be highly unusual. (2) The increased incidence may be caused by the mechanical properties of the respective stent. Since the devices are all made from different materials and fabricated with differing numbers of wires and braid angles, they exhibit varying mechanical properties such as radial force or push force. As a result, stent deployment differs. Some devices may cause more friction inside the catheter or require more catheter push or resheathing. This may increase the stress on the inner and outer layer of the microcatheter itself, or the inner layer of the guide or distal access catheter, potentially leading to more emboli occurrence in the hydrophilic polymers. Unfortunately, these data from bench testing, although certainly available, are not made public by the device manufacturers and are usually not published comparatively in scientific journals. Indeed, Chopra *et al* describe that hydrophilic polymers detach from interventional devices through two mechanisms; mechanical abrasion and time-dependent chemical degradation. Mechanical abrasion occurs when the device interacts with vasculature or other accessing/treating devices, causing strain on chemical bonds within the polymer structure. When a bond-energy threshold is reached, the bonds break, leading to coating separation from the device. Time-dependent chemical degradation weakens bonds in the polymer structure on contact with saline or pulsatile blood over extended periods. Avulsions occur within 60 min, with shedding seen in as little as 15 min. In both mechanisms the chemical bonds break, resulting in coating separation from the device.<sup>25</sup> (3) Vendor-specific microcatheters, guide or distal access catheters may cause the increased incidence. FDs are often sold together with the specified microcatheter from the same retailer or, if not, then their use with specific catheters is recommended. When looking at individual patient data (table 2), the range of microcatheters, guide, or distal access catheters was rather limited. Thus, NICE lesions may originate solely from these devices and are not related to the FD per se. However, one should note that catheters are often produced

by contract manufacturers that supply multiple customers. Also, the number of companies supplying the world market with polymers is very limited. (4) The more likely hypothesis is that the increased incidence is a combination of the aforementioned three factors. Our data are concerning and we believe that further research including comparative particle generation testing<sup>25</sup> with transparent publication of the results should be the next logical step. Specific technical details and bench testing results must be disclosed to the neurointerventional community in scientific journals.

Recently, surface modifications for neurovascular devices became available, most aiming to reduce the inherent thrombogenicity of the implant.<sup>26</sup> Most of these coatings are based on polymers: Medtronic uses the phosphorylcholine polymer, a component of the red blood cell membrane, to cover the surface of their FDs.<sup>27 28</sup> The glycan-based hydrophilic polymer coating by phenox was designed to imitate the glycocalyx.<sup>29 30</sup> The biopassive poly-2-methoxyethyl acrylate (PMEA) polymer was licensed by Microvention for their devices, referred to as X-Coating.<sup>31</sup> Acandis acquired a fibrin-based nanocoating, which is expected to make the device inert to the coagulation cascade.<sup>32</sup> With this study, we show that even if polymers are used for these coatings, the incidence of NICE lesions is not increased. One should note, however, that the coated devices used by Microvention and Acandis are comparatively underrepresented in our study.

The clinical manifestation of NICE lesions has a broad spectrum, ranging from incidental findings to seizures or focal neurological deficits. There are currently no recommendations for treating asymptomatic radiological findings to prevent impending clinical complications. Most symptomatic patients, both in more recent literature and in our series, were treated with corticosteroids.<sup>2 10</sup> Empiric antibiotic therapy was also administered in the past.<sup>3</sup> Estébanez *et al* described additional treatment with azathioprine<sup>11</sup> and Bayas *et al* reported on their experience with mycophenolate mofetil and tocilizumab.<sup>4</sup> It should be pointed out that NICE lesions are a chronic issue and often long-term immunosuppression may be needed. Patients can develop new symptoms even years after onset when corticosteroid dosages are slowly tapered down.<sup>8</sup>

### Study limitations

Our study has several limitations, with its retrospective design being the foremost concern. Additionally, there is a reduced external validity due to reliance on self-reported clinical and procedural data, and a lack of an independent clinical event committee adjudicating the severity and relevance of symptoms. Moreover, only eight of 23 centers responded to our query and contributed cases with NICE lesions, so a selection bias, which is shared with almost all retrospective multicenter series, may thus exist. Other limitations include non-standardized follow-up protocols and treatment regimens. It is imperative that these limitations be taken into consideration and rectified in a large prospective study involving a consecutive patient cohort under controlled conditions investigating this subject.

### CONCLUSION

In the largest study on NICE lesions after flow diversion to date, we prove that antithrombogenic coatings are not associated with an increased lesion incidence. However, we observed an incidence rate of 1%, which is higher than that of most previous studies, which include all kinds of endovascular treatment. We have furthermore found an accumulating number of cases with FDs from two specific product families. It is unclear if this

phenomenon originates from the device itself, from associated catheter materials or combinations of both, but our data are concerning and should prompt further research.

### Author affiliations

- <sup>1</sup>Institute of Neuroradiology, Leipzig University Hospital, Leipzig, Germany
- <sup>2</sup>Department of Interventional Neuroradiology, University of Heidelberg, Heidelberg, Germany
- <sup>3</sup>Department of Neuroradiology, University of Freiburg Faculty of Medicine, Freiburg, Germany
- <sup>4</sup>Institute of Diagnostic and Interventional Radiology and Neuroradiology, HELIOS Hospital Erfurt, Erfurt, Germany
- <sup>5</sup>Department of Diagnostic and Interventional Neuroradiology, University Medical Center Hamburg-Eppendorf, Hamburg, Germany
- <sup>6</sup>Institute of Neuroradiology, University Hospital Carl Gustav Carus, Dresden, Germany
- <sup>7</sup>Department of Radiology and Neuroradiology, University Hospital Halle, Halle, Germany
- <sup>8</sup>Department of Radiology and Neuroradiology, St Georg Hospital, Leipzig, Germany

**Twitter** Daniel P O Kaiser @daniel\_kaiserMD

**Acknowledgements** We would like to thank all centers included in our survey, and also those who could not contribute cases, for their efforts in going through their databases.

**Contributors** All authors were involved and made substantial contributions to the conception or design of the work, or the acquisition, analysis, or interpretation of the data; drafting the work or revising it critically for important intellectual content; final approval of the version published; and agreement to be accountable for all aspects of the work in ensuring that questions related to the accuracy or integrity of any part of the work are appropriately investigated and resolved. CR and MG are responsible for the overall content. CR is acting as the guarantor.

**Funding** The authors have not declared a specific grant for this research from any funding agency in the public, commercial or not-for-profit sectors.

**Competing interests** MG: Consultancy agreements with MicroVention, Balt, phenox. Scientific advisory board of Simq. Part of the clinical event committee in a study on a flow diverter sponsored by MicroVention.

**Patient consent for publication** Not applicable.

**Ethics approval** The local Ethics Committee of the Medical Faculty of the University of Leipzig approved this study (reference number: 488/22). The need for patient informed consent was waived for retrospective analyses of medical records and anonymized data collection. The study was performed in compliance with the World Medical Association's Declaration of Helsinki and this report adheres to the Strengthening of Reporting of Observational Studies in Epidemiology (STROBE) statement guidelines.

**Provenance and peer review** Not commissioned; externally peer reviewed.

**Data availability statement** All data relevant to the study are included in the article.

**Open access** This is an open access article distributed in accordance with the Creative Commons Attribution Non Commercial (CC BY-NC 4.0) license, which permits others to distribute, remix, adapt, build upon this work non-commercially, and license their derivative works on different terms, provided the original work is properly cited, appropriate credit is given, any changes made indicated, and the use is non-commercial. See: <http://creativecommons.org/licenses/by-nc/4.0/>.

### ORCID iDs

Cindy Richter <http://orcid.org/0000-0001-5105-9676>  
 Dominik F Vollherbst <http://orcid.org/0000-0002-8992-4757>  
 Samer Elsheikh <http://orcid.org/0000-0002-3796-5709>

### REFERENCES

- 1 Ishikawa S, Kudo Y, Miyake S, *et al*. Cerebral foreign body granulomas after mechanical thrombectomy: two case reports and a review of the literature. *J Stroke Cerebrovasc Dis* 2023;32:106990.
- 2 Shotar E, Labeyrie M-A, Biondi A, *et al*. Non-ischemic cerebral enhancing lesions after intracranial aneurysm endovascular repair: a retrospective French national registry. *J Neurointerv Surg* 2022;14:925–30.
- 3 Shotar E, Law-Ye B, Baronnet-Chauvet F, *et al*. Non-ischemic cerebral enhancing lesions secondary to endovascular aneurysm therapy: nickel allergy or foreign body reaction? Case series and review of the literature. *Neuroradiology* 2016;58:877–85.
- 4 Bayas A, Christ M, Berlis A, *et al*. Incidence, clinical spectrum, and immunotherapy of non-ischemic cerebral enhancing lesions after endovascular therapy. *Ther Adv Neurol Disord* 2022;15:17562864211072372.

- 5 Sirakov A, Aguilar Pérez M, AlMatter M. Paraophthalmic internal carotid artery aneurysm: non-ischemic cerebral enhancing (NICE) lesions after the endovascular treatment of an incidental paraophthalmic aneurysm with flow diverters and coils; conservative management, with resolution of the pathological cerebral findings and clinical recovery during mid-term follow-up. In: Henkes H, Lylyk P, Ganslandt O, eds. *The aneurysm casebook: a guide to treatment selection and technique*. Cham: Springer International Publishing, 2020: 183–94.
- 6 Forestier G, Escalard S, Sedat J, et al. Non-ischemic cerebral enhancing lesions after thrombectomy: a multicentric retrospective French national registry. *Neuroradiology* 2022;64:1037–42.
- 7 Guetarni Z, Bernard R, Boulouis G, et al. Longitudinal radiological follow-up of individual level non-ischemic cerebral enhancing lesions following endovascular aneurysm treatment. *J Neurointerv Surg* 2023;jnis-2023-020060.
- 8 Bakola E, Katsanos AH, Palaiodimou L, et al. Delayed recurrent enhancing white matter lesions complicating coiling of intracranial aneurysm. *Eur J Neurol* 2021;28:2388–91.
- 9 Nakagawa I, Park HS, Kotsugi M, et al. Delayed intracranial parenchymal changes after aneurysmal coil embolization procedures for unruptured intracranial aneurysms. *Operative Surg* 2020;19:76–83.
- 10 Ikemura A, Ishibashi T, Otani K, et al. Delayed leukoencephalopathy: a rare complication after coiling of cerebral aneurysms. *AJNR Am J Neuroradiol* 2020;41:286–92.
- 11 Moreno Estébanez A, Luna Rodríguez A, Pérez Concha T, et al. Symptomatic intracranial embolic foreign-body reactions after endovascular neurointerventional procedures: a retrospective study in a tertiary hospital. *Clin Neurol Neurosurg* 2021;200:106323.
- 12 Shapiro M, Ollenschleger MD, Baccin C, et al. Foreign body emboli following cerebrovascular interventions: clinical, radiographic, and histopathologic features. *AJNR Am J Neuroradiol* 2015;36:2121–6.
- 13 Gawlitza M, Soize S, Barbe C, et al. Aneurysm characteristics, study population, and endovascular techniques for the treatment of intracranial aneurysms in a large, prospective, multicenter cohort: results of the Analysis of Recanalization after Endovascular Treatment of Intracranial Aneurysm study. *AJNR Am J Neuroradiol* 2019;40:517–23.
- 14 Kaiser DPO, Boulouis G, Soize S, et al. Flow diversion for ICA aneurysms with compressive neuro-ophthalmologic symptoms: predictors of morbidity, mortality, and incomplete aneurysm occlusion. *AJNR Am J Neuroradiol* 2022;43:998–1003.
- 15 Hanel RA, Kallmes DF, Lopes DK, et al. Prospective study on embolization of intracranial aneurysms with the pipeline device: the PREMIER study 1 year results. *J NeuroInterv Surg* 2020;12:62–6.
- 16 Becske T, Brinjikji W, Potts MB, et al. Long-term clinical and angiographic outcomes following pipeline embolization device treatment of complex internal carotid artery aneurysms: five-year results of the pipeline for uncoilable or failed aneurysms trial. *Neurosurgery* 2017;80:40–8.
- 17 Michelozzi C, Darcourt J, Guenego A, et al. Flow diversion treatment of complex bifurcation aneurysms beyond the circle of Willis: complications, aneurysm SAC occlusion, reabsorption, recurrence, and jailed branch modification at follow-up. *J Neurosurg* 2018;131:1751–62.
- 18 Pistocchi S, Blanc R, Bartolini B, et al. Flow diverters at and beyond the level of the circle of Willis for the treatment of intracranial aneurysms. *Stroke* 2012;43:1032–8.
- 19 Hellstern V, Aguilar Pérez M, Henkes E, et al. Use of a P64 MW flow diverter with hydrophilic polymer coating (HPC) and prasugrel single antiplatelet therapy for the treatment of unruptured anterior circulation aneurysms: safety data and short-term occlusion rates. *Cardiovasc Intervent Radiol* 2022;45:1364–74.
- 20 Cattaneo G, Bräuner C, Siekmeyer G, et al. In vitro investigation of chemical properties and biocompatibility of neurovascular braided implants. *J Mater Sci Mater Med* 2019;30:67.
- 21 Henkes H, Klisch J, Lylyk P. Will coiling survive through the next decade? *J Clin Med* 2022;11:3230.
- 22 Cruz JP, Marotta T, O’Kelly C, et al. Enhancing brain lesions after endovascular treatment of aneurysms. *AJNR Am J Neuroradiol* 2014;35:1954–8.
- 23 Mehta RI, Mehta RI, Solis OE, et al. Hydrophilic polymer emboli: an under-recognized iatrogenic cause of ischemia and infarct. *Mod Pathol* 2010;23:921–30.
- 24 Abbasi M, Dai D, Liu Y, et al. Iatrogenic foreign materials associated with retrieved clot tissue via mechanical thrombectomy. *AJNR Am J Neuroradiol* 2021;42:1239–49.
- 25 Chopra AM, Rapkiewicz A, Daggubati R, et al. Analysis: intravascular devices with a higher risk of polymer emboli: the need for particulate generation testing. *Biomed Instrum Technol* 2020;54:37–43.
- 26 Gawlitza M, Klisch J, Kaiser DPO, et al. A systematic literature review and meta-analysis on the treatment of ruptured intracranial aneurysms with hydrophilic polymer and phosphorylcholine-coated flow diverters under single-antiplatelet therapy. *World Neurosurgery* 2023;170:e791–800.
- 27 Manning NW, Cheung A, Phillips TJ, et al. Pipeline shield with single antiplatelet therapy in aneurysmal subarachnoid haemorrhage: multicentre experience. *J Neurointerv Surg* 2019;11:694–8.
- 28 Hagen MW, Girdhar G, Wainwright J, et al. Thrombogenicity of flow diverters in an ex vivo shunt model: effect of phosphorylcholine surface modification. *J Neurointerv Surg* 2017;9:1006–11.
- 29 Aguilar-Perez M, Hellstern V, AlMatter M, et al. The P48 flow modulation device with hydrophilic polymer coating (HPC) for the treatment of acutely ruptured aneurysms: early clinical experience using single antiplatelet therapy. *Cardiovasc Intervent Radiol* 2020;43:740–8.
- 30 Lenz-Habijan T, Brodde M, Kehrel BE, et al. Comparison of the thrombogenicity of a bare and antithrombogenic coated flow diverter in an in vitro flow model. *Cardiovasc Intervent Radiol* 2020;43:140–6.
- 31 Yoshizawa K, Kobayashi H, Kaneki A, et al. Poly(2-methoxyethyl acrylate) (PMEA) improves the thromboresistance of FRED flow diverters: a thrombogenic evaluation of flow diverters with human blood under flow conditions. *J Neurointerv Surg* 2023;15:1001–6.
- 32 Link A, Michel T, Schaller M, et al. In vitro investigation of an intracranial flow diverter with a fibrin-based, hemostasis mimicking, nanocoating. *Biomed Mater* 2020;16:015026.