

Abstract E-110 Figure 1

10 cases out of a pool of 22 case scenarios and asked how they would treat the patient A) assumed there were no economical or infrastructural constraints, and B) given their current working conditions. Subgroup analyses were performed for female and male physicians respectively.

Results 607 physicians (97 women, 508 men, 2 who did not disclose their sex), of different specialties (326 neurologists, 173 interventional neuroradiologists, 81 interventional neurosurgeons, 2 geriatricians, 5 internists, 20 other) from 38 countries participated in this survey. 6070 responses were obtained. Neurologists constituted the largest group of both female (76.3%) and male (49.2%) physicians, with a more even distribution of specialties in male physicians. Assuming ideal conditions, no significant differences in EVT decision making was observed (EVT was favored by 77% of female and 79.3% of male physicians). Under their current working conditions, female physicians decided less frequently in favor of EVT (69.1%) as compared to their male colleagues (76.9%, $p < 0.001$).

Conclusion Under the ideal conditions, EVT decision between male and female physicians did not differ. Current working conditions restricted female physicians' endovascular treatment decision to a greater degree as compared to their male colleagues, resulting in a significantly lower decision rate in favor of EVT.

Disclosures J. Ospel: None. N. Kashani: None. B. Campbell: None. M. Foss: None. F. Turjman: None. S. Yoshimura: None. A. Wilson: None. W. Kunz: None. M. Cherian: None. B. Kim: None. A. Rabinstein: None. U. Fischer: None. P. Sylaja: None. B. Baxter: None. J. Heo: None. B. Menon: None. G. Saposnik: None. M. Hill: None. M. Goyal: None. M. Almekhlafi: 1; C; unrestricted research grant by Stryker to University of Calgary.

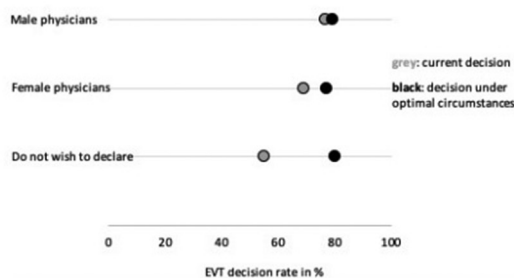
E-111

EFFICACY AND SAFETY OF ROBOTIC STEREOTACTIC ASSISTANCE (ROSA) DEVICE FOR MINIMALLY INVASIVE PLACEMENT OF INTRAPARENCHYMAL HEMATOMA AND INTRAVENTRICULAR CATHETERS: CASE SERIES

N Alan*, V Kokkinos, A Faraji, N Agarwal, B Jankowitz. *Neurosurgery, UPMC, Pittsburgh, PA*

10.1136/neurintsurg-2019-SNIS.186

Background In patients with supratentorial spontaneous intracerebral hemorrhage (ICH), intrahematoma catheter placement may allow for clot thrombolysis and drainage. Robotic assistance may be used for the stereotactic placement of catheters. **Objective** To describe efficacy and safety of stereotactic robotic assistance for placement of intrahematoma catheters.



Methods From 2017–2018, 4 patients with average age 64 year old (three females, one male) who presented with supratentorial ICH underwent placement of intrahematoma catheter using stereotactic robotic assistance. Postoperatively, alteplase was delivered via the catheters to the clot and the hematoma drained.

Results A total of 9 catheters were placed. The time from last seen well to incision in the operating room was between 38 to 48 hours. Average volume of ICH at initial presentation was 52 cc (29–68 cc) on volumetric analysis. Average dose of alteplase postoperatively was 6 mg (range 5–9 mg), delivered over 32.5 hours (range 18–46 hours). Average volume of ICH at 12 hours after last dose of alteplase was 13 cc (range 2–34 cc) resulting in an average reduction of 39 cc ($77 \pm 24\%$). Output from the drains were 102–872 cc (average of 561 cc). Average error associated with catheter placement at its tip was 3.3 mm \pm 2.0 mm, when comparing preoperative planned trajectory to immediate postoperative scan.

Conclusion Stereotactic robotic assistance was used safely and effectively for thrombolysis and drainage of supratentorial intracerebral hemorrhage.

Disclosures N. Alan: None. V. Kokkinos: None. A. Faraji: None. N. Agarwal: None. B. Jankowitz: None.

E-112

HOW DO CLOTS RESPOND TO DIRECT ASPIRATION DURING INTERVENTIONAL TREATMENT OF ACUTE ISCHEMIC STROKE

M Marosfoi, L Strittmatter, R Arslanian, C Raskett, M Gounis, A Puri, F Massari, K De Macedo Rodrigues, J Singh, J Chueh*. *UMass Medical School, Worcester, MA*

10.1136/neurintsurg-2019-SNIS.187

Introduction Advances in pump design make aspiration patterns programmable, producing an infinite combination of cyclical aspiration profiles for clot removal during treatment of acute ischemic stroke (AIS). However, little is known about how clots respond to different aspiration patterns. The goal of this study is to assess the structural and mechanical changes of the clot under aspiration. It is our hypothesis that a decreased fibrin pore size correlates to a higher aspiration efficacy.

Materials and methods A fibrin-rich bovine clot was used to create an MCA occlusion in a patient-specific silicone model and underwent thromboaspiration via a 6F Sofia Plus catheter (Microvention, Tustin, CA). Three sets of the retrieved clots were prepared for scanning electron microscopy (SEM) analysis, including clots lodged at the MCA without aspiration (control) as well as clots subjected to static (28 mmHg) or cyclic aspiration (amplitude: 18 to 27