

**E-073 IMPACT OF DIABETES WITH COMPLICATIONS ON SHORT-TERM IN-HOSPITAL OUTCOMES IN PATIENTS UNDERGOING SPINAL FUSION PROCEDURES**

T Colburn\*, D Schirmer, Z Rose-Reneau, B Wright. *Kansas City University of Medicine and Biosciences, Kansas City, MO*

10.1136/neurintsurg-2019-SNIS.148

**Background** Spinal fusion is a surgical procedure utilized to treat or alleviate several spinal diagnoses including: tumor, spinal stenosis, degenerative disc disease, scoliosis, and spondylolisthesis. Previous studies have explored clinical outcomes for this intervention. This study aims to further investigate short-term outcomes of patients after spinal fusion by looking at the impact of diabetes with complications.

**Methods** This retrospective cohort study utilized data from the Nationwide Inpatient Sample (NIS) to identify adult patients (18+) from 2012–2015 who underwent spinal fusion. ICD-9 codes identified these patients; specifically patients diagnosed with diabetes and associated complications. Any patients missing important clinical identifiers (age, gender, cause of death) and patients without spinal fusion intervention were excluded. Data analyses assessed hospital length of stay (LOS), inpatient charges, average age of admission and mortality rate.

**Results** Of the 290,752 patients that underwent spinal fusion procedure, 1,092 had the diagnosis of diabetes with complications (DMCx).

Mean mortality rate of patients was significantly increased (1.8%, DMCx vs. 0.6%, without DMCx,  $p = 0.0001$ )

LOS in patients with DMCx who underwent spinal fusion was significantly increased (7.44 days, DMCx vs. 4.01 days, no DMCx  $p = 0.0001$ )

Total hospital charges were significantly increased (\$135,783.00, DMCx vs. \$98,231.18, no DMCx,  $p = 0.0001$ )

Mean age of patients at admission was increased (63.6, DMCx vs. 57.67, no DMCx,  $p = 0.0001$ )

**Conclusion** Patients with complicated diabetes who undergo a spinal fusion procedure suffer from increased mortality rate, LOS, total hospital charges, and age at admission. This study aims to provide physicians with information in the management of patients with complicated diabetes that undergo spinal fusion procedures. Peri-procedural patient optimization could provide a potential avenue to lower LOS, total in-hospital charges, and mortality in patients.

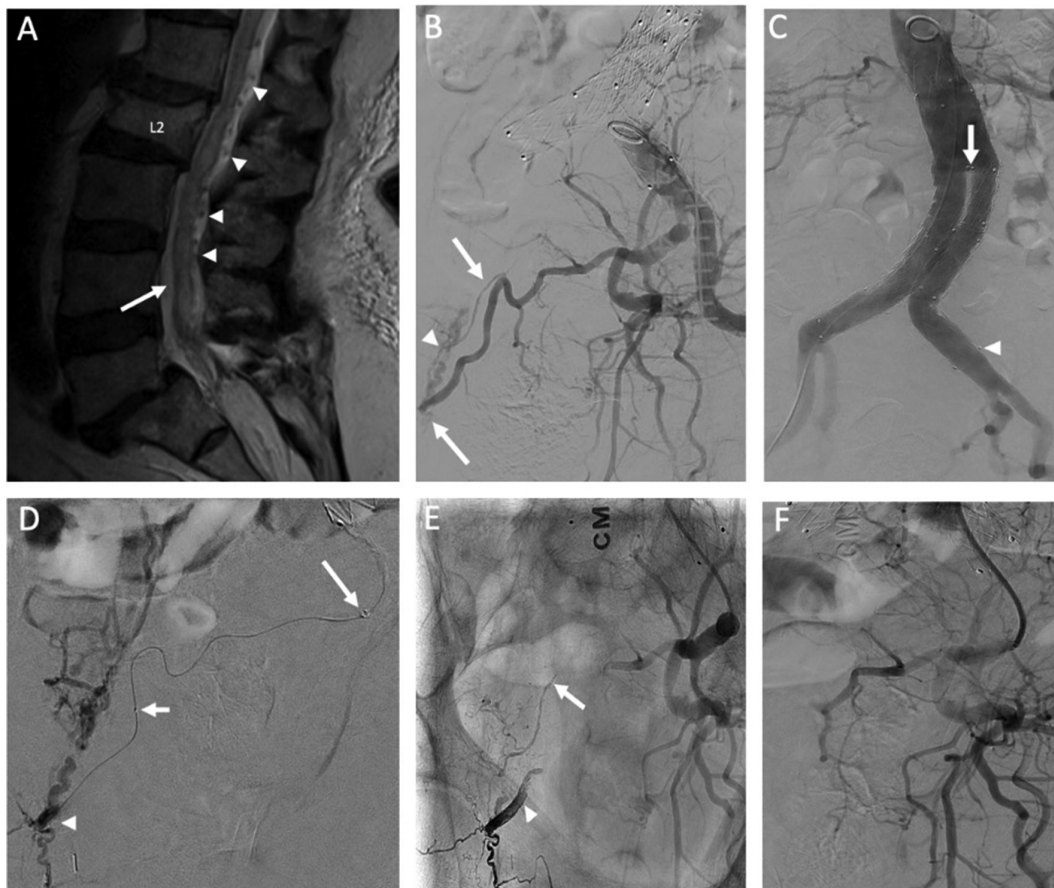
**Disclosures** T. Colburn: None. D. Schirmer: None. Z. Rose-Reneau: None. B. Wright: None.

**E-074 TRANSRADIAL APPROACH FOR THE TREATMENT OF A SACRAL DURAL ARTERIOVENOUS FISTULA: HOW FAR CAN WE GO?**

E Orru\*, C Tsang, J Klostranec, V Mendes Pereira. *Neuroradiology, Toronto Western Hospital, Toronto, ON, Canada*

10.1136/neurintsurg-2019-SNIS.149

Sacral dural arteriovenous fistulae (SDAVFs) are rare, constituting no more than 10% of all spinal dural fistulae. They are most commonly fed by the lateral sacral artery (LSA), a branch of the internal iliac artery (IIA). Catheterization of this vessel requires either a cross-over at the aortic bifurcation in



Abstract E-074 Figure 1

case of right femoral access or retrograde catheterization from the ipsilateral common femoral artery. We present the case of a 79-year-old male with tethered cord syndrome and a symptomatic SDAVF fed by two dural branches from the left LSA (A,B). Spinal diagnostic angiography was made exceptionally challenging by an aorto-bi-iliac endograft, and selective catheterization of the left IIA was not possible (C). Given suboptimal cardiovascular profile and the tethered cord, consensus was to proceed with endovascular embolization. Right transradial approach (TRA) was chosen in order to have the straightest path possible for selection of the left IIA with the guiding catheter. A 6F dedicated glidesheath was introduced under ultrasound guidance in the right radial artery and a 6F, 131 Cm Sofia Plus catheter was navigated retrogradely until the left IIA, negotiating the aorto-iliac graft with an 0.038, 180 cm wire. A 165 cm Apollo microcatheter was advanced over a 0.007 Hybrid microwire into the LSA until the most distal fistulous point, which was embolized with Onyx 18 (figure D). The second, proximal feeder was selected with a 165 cm Magic 1.2 and was embolized with a 2:1 mixture of glue (NBCA) and Lipiodol (E), successfully occluding the SDAVF (F). Recently, TRA has gained more popularity in the neuroendovascular field. Advantages include fewer haemorrhagic complications (notably eliminating the risk for retroperitoneal hematoma) increased post-procedural comfort and access to vessels that would not be reachable through transfemoral approach. Device size and length are key considerations. Most radial arteries accommodate 6F sheaths, although successful usage of 8F systems has been reported for arteries larger than 2.5 mm. In distal lesions device length can also be a problem, as the treatment target might be too distal even for the longest microcatheter. We pre-operatively measured the length of right arm and abdomen in order to choose catheters long enough to not run out of length. The presented case is, to our knowledge, the first report of a spinal vascular malformation treated by TRA. This approach, granted appropriate equipment selection, can allow treatment of spinovascular pathologies with an otherwise unfeasible aorto-iliac anatomy.

**Disclosures** E. Orru: None. C. Tsang: None. J. Klostranec: None. V. Mendes Pereira: 1; C; Philips. 2; C; Stryker, Balt, Medtronic, Cerenovus.

#### E-075 IMPACT OF COAGULATION DISORDERS ON SHORT-TERM IN-HOSPITAL OUTCOMES IN PATIENTS UNDERGOING SPINAL FUSION PROCEDURES

T Colburn\*, K Tong, A Wang-Selfridge, B Wright. *Kansas City University of Medicine and Biosciences, Kansas City, MO*

10.1136/neurintsurg-2019-SNIS.150

**Background** Spinal fusion is a surgical procedure utilized to treat or alleviate several spinal diagnoses including: tumor, spinal stenosis, degenerative disc disease, scoliosis, and spondylolisthesis. Previous studies have explored clinical outcomes for this intervention. This study aims to further investigate short-term outcomes of patients after spinal fusion by looking at the impact of coagulation disorders.

**Methods** This retrospective cohort study utilized data from the Nationwide Inpatient Sample (NIS) to identify adult patients (18+) from 2012–2015 who underwent spinal fusion. ICD-9 codes identified these patients; specifically patients diagnosed with a coagulation disorder. Any patients missing important

clinical identifiers (age, gender, cause of death) and patients without spinal fusion intervention were excluded. Data analyses assessed hospital length of stay (LOS), inpatient charges, average age of admission and mortality rate.

**Results** Of the 290,752 patients that underwent spinal fusion procedure, 182 had the diagnosis of a coagulation disorder (CD):

Mean mortality rate of patients was significantly increased (4.9%, CD vs. 0.6% no CD,  $p = 0.0001$ )

LOS in patients with CD who underwent spinal fusion was significantly increased (12.87 days, CD vs. 4.02 days, no CD,  $p = 0.0001$ )

Total hospital charges were significantly increased (\$289,377.06, CD vs. 98,232.87, no CD,  $p = 0.0001$ )

Mean age of patients at admission was significantly increased (60.68 years, CD vs. 57.69 years, no CD,  $p = 0.008$ )

**Conclusion** Patients with coagulation disorders who undergo a spinal fusion procedure suffer from increased mortality rate, LOS, total hospital charges, and age at admission. This study aims to provide physicians with information in the management of patients with coagulation disorders that undergo spinal fusion procedures. Peri-procedural patient optimization could provide a potential avenue to lower LOS, total in-hospital charges, and mortality in patients.

**Disclosures** T. Colburn: None. K. Tong: None. A. Wang-Selfridge: None. B. Wright: None.

#### E-076 CHARACTERIZATION OF CLINICAL OUTCOMES WITH THE SPINEJACK: A SINGLE-CENTER RETROSPECTIVE ANALYSIS OF EARLY EXPERIENCES IN THE UNITED STATES WITH A NOVEL PERCUTANEOUS VERTEBRAL AUGMENTATION SYSTEM

M Martini, K Yaeger, D Nistal, A Doshi, R De Leacy. *Neurosurgery, Icahn School of Medicine at Mount Sinai, New York, NY*

10.1136/neurintsurg-2019-SNIS.151

**Background and Purpose** Recently, the SpineJack has gained FDA clearance for marketing in the United States. These systems are quick and easy to deploy and have the advantage of being installed percutaneously under local anesthesia. As such, they are currently transforming the treatment landscape for patients with osteoporotic and malignant vertebral compression fractures (VCFs). Given the recency of this clearance, there is a dearth of information in the literature pertaining to experience with implementing the SpineJack in the United States. This study seeks to provide one of the first detailed analyses of outcomes following the use of the SpineJack for treating osteoporotic and malignant VCFs in the United States. This study will focus on determining the extent to which the SpineJack is able to achieve adequate vertebral height restoration, pain reduction, and functional restoration, while minimizing the incidence of adjacent level fractures and volume of cement required to be injected into the vertebrae.

**Methods** Retrospective data will be collected from cases at our institution in which the SpineJack was applied to treat patients presenting with osteoporotic or malignant VCFs. We expect to acquire data from approximately 25 cases of SpineJack procedures used to treat VCF, representing our institution's collective early experiences with this novel system. A detailed dataset will be generated from each case, including patient