




OPEN ACCESS

ORIGINAL RESEARCH

# Efficacy and safety of the dual-layer flow-diverting stent (FRED) for the treatment of intracranial aneurysms

Leopoldo Guimaraens,<sup>1,2</sup> Elio Vivas,<sup>1,2</sup> Jesus Saldaña,<sup>1,2</sup> Juan Carlos Llibre,<sup>1,2</sup> Alberto Gil,<sup>1,2</sup> Ernest Balaguer,<sup>1</sup> Ana Rodríguez-Campello,<sup>3</sup> Elisa Cuadrado-Godia,<sup>3</sup> Angel Ois <sup>3</sup>

<sup>1</sup>Interventional Neuroradiology, Hospital General de Catalunya, Sant Cugat del Vallès, Spain

<sup>2</sup>Interventional Neuroradiology, Hospital del Mar, Barcelona, Spain

<sup>3</sup>Neurology, Hospital del Mar, Barcelona, Spain

## Correspondence to

Mr Elio Vivas, Neuroradiologia Intervencionista, Hospital General de Catalunya, Sant Cugat del Vallès 08195, Spain; [evivas@gmail.com](mailto:evivas@gmail.com)

Received 15 August 2019

Revised 10 October 2019

Accepted 12 October 2019

Published Online First

25 October 2019

## ABSTRACT

**Purpose** To describe the efficacy and complications of treating cerebral aneurysms with the Flow Re-direction Endoluminal Device (FRED) and to identify predictors for aneurysm occlusion.

**Methods** A prospective observational registry including all consecutive aneurysms treated with FRED between December 2015 and July 2018 was designed in one therapeutic neuroangiography department. The primary endpoint for treatment efficacy was complete or near-complete occlusion (O'Kelly–Marotta (OKM) C–D), assessed by three-dimensional digital subtraction angiography. Major (all symptomatics) and minor complications were described and those with modified Rankin Scale scores 3–6 were considered clinically relevant. Univariate and multivariate analyses were performed to identify predictors of efficacy.

**Results** A total of 185 aneurysms were analyzed in 150 patients (mean age 54.3±11.5 years). Mean follow-up was 18.99±11.32 months (range 0–43). Efficacy was evaluated in 156 (84.32%) cases: 132 (84.6%) had OKM C–D occlusion, 31/47 (66%) within the first year and 101/109 (92.7%) later on. Major complications were observed in 12 (6.5%) cases: three strokes (one transient ischemic accident, two minor strokes), six intra-stent thrombosis, and three with bleeding, but only one (0.5%) was clinically relevant. Minor complications (all asymptomatic) were observed in 10 (5.4%) cases: three shortening/repositioning of stent; two arterial dissection, two arterial occlusion, and three intra-stent stenosis. Independent predictors of occlusion were immediate OKM grade B–C–D (OR 4.01, 95% CI 1.51 to 10.62), single aneurysm (OR 3.29, 95% CI 1.05 to 10.32), and small size aneurysm (OR 4.74, 95% CI 1.57 to 14.30).

**Conclusion** The FRED stent fully complied with efficacy and safety requirements for treatment of intracranial aneurysms. Three predictors of aneurysm occlusion were identified.

stent-assisted coil embolization<sup>2</sup>). The development of flow-diverter (FD) stents offers a simple way to treat these lesions with low morbidity and mortality. These are essentially fine-mesh stents, endovascularly implanted in cerebral arteries at the site of aneurysms. They were named for their primary function, which is to 'divert' blood flow away from the aneurysm and into the parent artery, reducing flow activity within the aneurysm.<sup>3</sup> In a further development, the Flow-Redirection Endoluminal Device (FRED; MicroVention, Aliso Viejo, California, USA) combines an outer self-expanding and dimensionally stable open-pored stent with an inner narrowly braided stent. It is intended to combine easy deployment with flow-redirecting properties. The flared ends of the outer layer exceed the inner layer on each side by approximately 3 mm with little or no flow-diverting effect.<sup>4–6</sup> However, especially in wide-necked, spindle-shaped, dissecting, and giant aneurysms or incomplete coiling and reperfusion, these FD stents are an important tool to produce a stable occlusion in the short or long term.

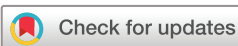The aims of our study were to describe the efficacy and security of treating cerebral aneurysms with FRED stents and to identify predictors for aneurysm occlusion.

## MATERIALS AND METHODS

A prospective observational registry was designed to include all consecutive aneurysms electively treated with the FRED implant from December 2015 to July 2018 in one therapeutic neuroangiography department serving two Barcelona hospitals, Hospital Universitari General de Catalunya and Hospital del Mar. The decision for treatment was taken jointly by at least two interventional neuroradiologists following morphologic and morphometric aneurysm criteria in cases in which other endovascular treatments were inadvisable due to wide-necked saccular aneurysms (fundus-to-neck ratio <2 or neck diameter >4 mm), fusiform, dissecting, blister-like, or giant aneurysms (>25 mm maximum diameter) or recanalization after previous coiling/surgery/stenting. Exclusion criteria were consensus due to branch configuration (an acute angle in relation to the parent vessel) or small diameter of the parent artery (<2.0 mm).

## INTRODUCTION

Due to the great complexity in the morphology and location of some cerebral aneurysms, endovascular treatment of these lesions is difficult, and recanalization and/or neck remnants have been observed despite refinements in coil technology (such as coated platinum coils) and/or procedural modifications (such as balloon-remodeling technique<sup>1</sup> or



© Author(s) (or their employer(s)) 2020. Re-use permitted under CC BY-NC. No commercial re-use. See rights and permissions. Published by BMJ.

**To cite:** Guimaraens L, Vivas E, Saldaña J, et al. *J NeuroIntervent Surg* 2020;**12**:521–525.

### Description of technique

All patients received dual antiplatelet therapy (aspirin 300 mg and clopidogrel 75 mg) for at least 5 days prior to the treatment. The effectiveness of the antiplatelet regime was tested using VerifyNow (Accumetrics, San Diego, California, USA). The post-procedural dual antiplatelet regimen was continued for the first 6 months, and then a single antiplatelet (clopidogrel or aspirin) for 12–18 months. All patients received an intravenous bolus of heparin (50 IU/kg weight) at the beginning of the procedure and a heparin bolus of 1000 IU during the procedure to maintain a clot activity time >250–300 s. All procedures were performed with the patient under general anesthesia and with a unilateral femoral approach. A digital subtraction angiography with three-dimensional volumetric reconstruction (3D-DSA) was performed for each case using a biplane angiographic system (Philips AlluraClarity, Philips Healthcare, Best, The Netherlands) to delineate the anatomy of the parent artery and measure its diameter proximal and distal to the aneurysm. The selection of FD size is crucial to promote a safe and complete occlusion of the aneurysm.<sup>7,8</sup> The diameter and length of the stent was calculated by measuring the 3D-DSA reconstruction, both volume rendering and shaded surface. The maximum diameter of the segment of the parent artery into which the device was deployed determined the FRED diameter selection, oversized in some cases by 25–30%. One of the reasons for an oversized stent diameter was the likely variability in arterial diameter, depending on the phase of the cardiac cycle or the values of arterial hypertension recorded at the time of the study.<sup>9</sup> Selection of the working length for flow diversion was based on covering the neck of the aneurysm or the length of the fusiform or dissecting aneurysm with a margin of 2.5 or 3 mm at both the proximal and distal ends. The FRED was delivered using a coaxial system (6Fr Envoy and Headway 21/27, MicroVention) over a 0.016 Terumo microguidewire. If the device is not correctly positioned across the aneurysm neck, the pusher allows resheathing and repositioning of the stent as long as 80% of its length has been unsheathed/deployed. As soon as the delivery microcatheter (Headway 21 or 27) is fully withdrawn over the delivery microwire, the coupling wire releases and the stent is deployed.

### Data collection

All data were acquired directly by the neurologist and interventional neuroradiologist using a predefined database with the following variables: age, sex, previous subarachnoid hemorrhage (SAH), single versus multiple aneurysm, FRED Junior (dedicated to small-vessel diameters between 2.0 and 3.0 mm), localization (dichotomized in anterior versus posterior circulation for analysis), aneurysm morphology (saccular fusiform, dissecting, blister/dysplasia, pre-treated), size according to largest diameter (small: <5 mm; medium: 5–10 mm; large: >11 mm), and OKM grade at the end of the procedure and at the last follow-up performed.

### Follow-up

Patients were evaluated by a vascular-trained neurologist before and immediately after the procedure and every 12 hours during the stroke unit stay. Mortality and disability using the modified Rankin Scale (mRS) were recorded by a neurologist and/or neuroradiologist at 1 month and, at the physician's discretion, every 3–6 months thereafter during a clinic appointment. The 3D-DSA studies were performed pre-treatment, immediately after treatment, and at 3–9 months post-treatment and every 3–12 months thereafter, at the physician's discretion.

### Efficacy

Occlusions were evaluated for degree of filling and stasis of flow within the aneurysm using the OKM grading scale,<sup>10</sup> which has been reported to have good intra- and inter-observer agreement.<sup>11</sup> The degree of filling of each aneurysm is graded with a letter as follows: A, total; B, subtotal; C, entry remnant; or D, no filling. The primary endpoint for treatment efficacy was complete or near-complete occlusion (OKM C and D) evaluated in the last available study performed during follow-up, regardless of degree of stasis.

### Complications

Complications were defined as major if any neurological symptom resulted and were considered clinically relevant if the mRS score was >2 at final follow-up. Minor complications included non-symptomatic intra-stent stenosis, vessel occlusion, dissection, and shortening or repositioning of the stent.

### Statistical analysis

Data are presented as mean and SD for continuous variables and as number and percentage for categorical variables. Univariate analysis was performed using the Pearson  $\chi^2$  (categorical variables) or t-test (continuous variables). OKM grade was analyzed as continuous in univariate testing (p value obtained in univariate analysis evaluated global differences between grades). Variables with  $p < 0.1$  in univariate analysis were selected to the multivariate regression model. Due to the number of cases, all variables were introduced as dichotomous in multivariate modeling adjusted by age and sex. OKM was dichotomized into A versus B–C–D grades. Associations are presented as odds ratios (OR) with the corresponding 95% confidence interval (95% CI). Statistical analysis was performed with the Statistical Package for Social Science Version 23.0 for Windows (SPSS, Chicago, Illinois, USA). The report of the analysis follows the Strengthening Reporting of Observational Studies in Epidemiology (STROBE) guidelines.

### Ethics

Before the intervention, all patients provided signed informed consent. The registry satisfies all requirements mandated by Spain's law on the protection of personal data and the institution review board approved the study (2008/3038/I).

## RESULTS

### Characteristics

From December 2015 to July 2019 a total of 185 aneurysms were treated with FRED stents in 150 patients; one aneurysm was treated with FRED twice. Four patients had three aneurysms, 27 had two and 119 had one. The mean age of the patients was  $54.3 \pm 11.5$  years. Patient characteristics and aneurysm morphology, localization, and immediate post-treatment OKM grade are shown in [table 1](#).

In four patients, complementary treatment with coiling was performed at the time of FRED implant. Fifty-four aneurysms had been treated previously: 39 by coiling, nine by coiling and stenting, two by clipping, and four by stenting.

### Follow-up

Mean follow-up was  $18.99 \pm 11.32$  months (range 0–43). All patients had immediate post-treatment angiography data; 47 cases had angiography data at 3–9 months and 109 cases were studied after more than 1 year. Therefore, efficacy was analyzed

**Table 1** Characteristics of patients, aneurysms, arterial location, and immediate O'Kelly–Marotta (OKM) grading scale

Variables	n=185 (%)
Characteristics of patients or stent	
Male	31 (20.1)
Previous subarachnoid hemorrhage	87 (47)
Single versus multiple aneurysm	67 (36.2)
FRED Junior	36 (19.5)
Aneurysm morphology	
Saccular	78 (42.2)
Fusiform	24 (13)
Blister/dysplastic artery	22 (11.9)
Dissecting	6 (3.2)
Pre-treated by other techniques	54 (29.2)
Size	
Small	86 (46.5)
Medium	27 (14.6)
Large	11 (5.9)
Posterior versus anterior territory	17 (9.2)
Immediate OKM grade	
A	57 (30.8)
B	93 (50.3)
C	30 (16.2)
D	5 (2.7)

in 156 cases, all with 3D-DSA except two cases that had CT angiography data.

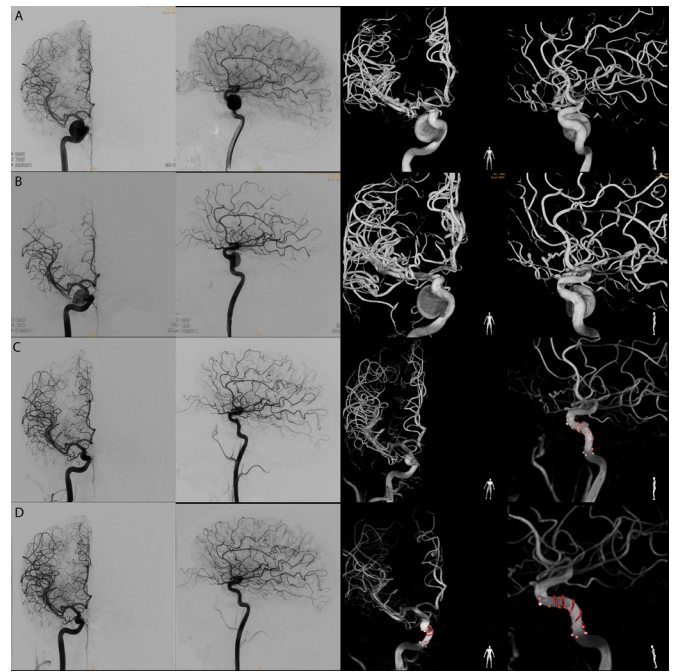
### Efficacy

Global percentage of occlusion at the end of follow-up was 84.6% (132/156), 31/47 (66%) within the first year and 101/109 (92.7%) more than 1 year post-treatment; [figure 1](#) shows an example of post-stent monitoring. The percentages of occlusion according to patient characteristics and aneurysm morphology, localization, and immediate OKM grade in those 156 cases with arterial monitoring during follow-up are shown in [tables 2 and 3](#)

Immediate OKM grade, small size, and single aneurysm were significantly associated with occlusion in univariate analysis. Immediate OKM grade B–C–D (OR 4.01, 95% CI 1.51 to 10.62), single aneurysm (OR 3.29, 95% CI 1.05 to 10.32), and small size (OR 4.74, 95% CI 1.57 to 14.30) were independent predictors of occlusion, adjusted by age and sex in multivariate analysis.

### Safety

Major complications were observed in 12 (6.5%) cases: three bleeding (two SAH and one cerebral hemorrhage) and nine ischemic events, including six intra-stent thrombus formation (in two cases thrombosis was detected during the procedure and treated immediately; patients were asymptomatic post-procedure), two strokes, and one TIA. Three of the ischemic complications occurred 1–2 weeks after antiplatelet cessation. Intra-stent thrombosis was resolved with administration of intra-arterial urokinase. Two bleeds were resolved (carotid occlusion in one case and coiling of the aneurysm in the other). Only one (0.5%) major complication (a spontaneous hypertensive deep hemorrhage contralateral to the side of the stent) was clinically



**Figure 1** (A) Three-dimensional pre-stent reconstruction. (B) Immediate post-stent follow-up. (C) Six-month follow-up showing great reduction in the size of the aneurysm. (D) Annual images showing complete exclusion of the aneurysm with correct permeability of the carrier vessel.

relevant (the only death in the series). At 1 month follow-up, mRS scores were as follows: 3 in three cases (1.6%), 2 in three cases (1.6%), and 0–1 in the rest of the cases (96.8%). At the end of the study, mRS scores were 6 in one case, 2 in three cases, and 0–1 in the rest of the cases.

Minor complications were observed in 10 (5.4%) cases: three shortening/repositioning of the stent, two arterial dissections, two artery occlusion during follow-up, and three intra-stent stenosis. All patients were asymptomatic during follow-up.

In the 36 cases receiving FRED Junior stents we observed five (13.9%) stent-related complications, all of them major: two clinically relevant bleeding events (one SAH and one cerebral hemorrhage) and three ischemic events (two intra-stent thrombus formation and one stroke) (see [table 4](#)).

### DISCUSSION

FD stents are an important development in the endovascular approach to the treatment of intracranial aneurysms, shifting the aim of the procedure from occluding the dome of the aneurysm to repairing the parent vessel wall. Stent therapy is now an alternative treatment for intracranial aneurysms because of its efficacy and safety profile.<sup>12–17</sup>

We have compiled here our experience using the FRED stent, evaluating its efficacy for the treatment of intracranial aneurysms. After more than 1 year we observed aneurysm occlusion/near occlusion (OKM C–D) of 92.7%, slightly lower than the 95.3% reported by Killer-Oberpfalzer *et al* (with a first-year rate of 91.3%) in the European retrospective multicenter study, which compiled the experience of 15 high-volume neurovascular centers.<sup>12</sup> Similarly, the Italian FRED Registry, which included 169 aneurysms treated in 30 Italian centers, reported a high rate of occlusion (94% in the first year, increasing to 96% at 12–24 months). However, 90% of cases in the Italian series were unruptured aneurysms; in our series, occlusion was achieved in 84.4%

**Table 2** Univariate analysis and percentage of aneurysm occlusion (O’Kelly–Marotta (OKM) C–D) ascribed to each variable in the 156 patients with arterial monitoring data

Variables	Aneurysm occlusion	
	N/total (%) of subgroup	P values
Characteristics of patients or stent		
Male	27/31 (87.1)	0.669
Previous subarachnoid hemorrhage	65/77 (84.4)	0.964
Single versus multiple aneurysm	52/58 (89.7)	0.180*
FRED Junior	28/32 (87.5)	0.612
Aneurysm morphology		
Saccular	56/66 (84.8)	0.945
Fusiform	15/17 (88.2)	0.661
Bliaster/dysplastic artery	19/19 (100)	0.047
Dissecting	2/3 (66.7)	0.384
Pre-treated by other techniques	40/50 (80)	0.273
Size		
Small	66/72 (91.5)	0.024*
Medium	17/22 (77.3)	0.303
Large	7/8 (87.5)	0.816
Posterior versus anterior territory	12/16 (75)	0.26
Immediate OKM grade		
A	27/39 (68.4)	
B	71/83 (85.4)	
C	29/29 (100)	
D	5/5 (100)	0.004*

\*Selected for multivariate analysis.

of 87 cases with previous SAH, lower than that of our overall series. Although we cannot report a statistical association, we also cannot rule out a lower probability of occlusion in these aneurysms; this will require further study with a larger sample of patients. The follow-up analysis of the 103 cases in the SAFE study (Safety and efficiency Analysis of FRED Embolic device in the treatment of aneurysms) reported occlusion/near occlusion

**Table 3** Arterial localization and percentage of aneurysm occlusion (O’Kelly–Marotta (OKM) C–D) ascribed to each location in the 156 patients with arterial monitoring data

	Total n=185 (%)	Aneurysm occlusion n=156 (% of subgroup)
Cervical carotid	3 (1.6)	1/1 (100)
Carotid siphon	85 (45.9)	63/71 (88.7)
Middle cerebral	25 (13.5)	17/22 (77.3)
Posterior communicating	21 (11.4)	14/18 (77.8)
Anterior communicating	18 (9.7)	14/15 (93.3)
Basilar	12 (6.5)	7/10 (70)
Anterior choroidal	5 (2.7)	3/4 (75)
Posterior inferior cerebellar	5 (3)	5/5 (100)
Anterior cerebral	3 (1.6)	3/3 (100)
Posterior cerebral	3 (1.6)	3/3 (100)
Vertebral	5 (2.7)	4/5 (75)

**Table 4** Efficacy and safety comparative analysis between FRED and FRED Junior devices

Variables	FRED	FRED Junior	P values
	n=149 (%)	n=36 (%)	
Clinical outcome			
mRS 3–6	0	1 (2.8)	
mRS 2	2 (1.3)	1 (2.8)	
mRS 0–1	147 (98.7)	34 (94.4)	0.102
Adverse events			
Major complications	7 (4.7)	5 (13.9)	
Minor complications	10 (6.7)	0	0.045
OKM grade C–D*			
Total	104 (87.5)	28 (83.9)	0.612
Follow-up >1 year	81 (92%)	20 (95.2)	0.614

\*In 156 cases with arterial monitoring data.

mRS, modified Rankin Scale; OKM, O’Kelly–Marotta.

of 81.1% at 6–12 months, slightly lower than in the other series but still pending a correspondingly long-term follow-up.

The high rate of occlusion in these studies is accompanied by a low incidence of relevant complications (defined the same in the SAFE study as in our sample: mRS >2). Our results agree with previous series, confirming a high rate of complete aneurysmal occlusion associated with a low incidence of clinically relevant complications (0.5% in our sample). Killer-Oberpfalzer *et al* reported a complications rate of 14% (7.3% periprocedural and 6.7% during follow-up), while the SAFE study observed 2.9% morbidity, 1.9% mortality, and 6.8% thromboembolic complications (with three of the seven cases occurring during the first 6 hours post-procedure).<sup>16 17</sup> The Italian FRED study, which achieved the highest occlusion rate, also reported a slightly higher rate of complications: 4.3% mortality and 7.3% morbidity. In our single-center study, the excellent safety data, especially for thrombus formation, highlight the importance of having an experienced team capable of treating complications in order to avoid clinical repercussions. Moreover, these patients will require prolonged single or dual antiplatelet treatments; the suspension of these treatments (for various reasons) in three patients led to ischemic complications and may have caused a spontaneous fatal hemorrhage in the basal ganglia of one of our patients.

The efficacy and safety of FRED treatment seems to be somewhat better than previously reported with other FD stents. A retrospective comparison of the FRED device (extracted from SAFE data) and the Pipeline Embolization Device showed an advantage of FRED for the treatment of aneurysms of the internal carotid artery in terms of near-complete occlusion (18.2% vs 5.4%, respectively), but comparable rates of complete occlusion (79.4% vs 77.8%) and neurological complications (7.7% vs 5.9%). In a recent meta-analysis by Briganti *et al*, results from 18 studies showed that FD stenting of intracranial aneurysms achieves a good percentage of occlusion (81.5%) with a low incidence of major complications (range 0–23.1%, mean 8.3%). In addition, mortality ranged from 0.5% to 8% (mean 3.4%) and permanent morbidity related to the procedure was 3.5% (range 1–15%).<sup>14</sup> However, a direct randomized comparison of the different FDs has not yet been performed and therefore the level of evidence is insufficient to recommend a specific type of stent.<sup>14</sup>

It is interesting to note the differences we observed in the percentage of occlusion achieved depending on aneurysm location (lower percentage in basilar artery), although these differences were not statistically significant due to the number of locations analyzed. Further analysis is needed in a larger sample. Our study included 36 FRED Junior stents used in parent vessels with diameters <3 mm. We found a similar efficacy to the whole series (87%) but with a higher rate of complications (13.9% vs 6.5% of FRED stents), with one fatal case (2.7%). Limited data are available on the effectiveness and safety of FRED Junior. Möhlenbruch *et al*<sup>18</sup> have reported a series of 47 aneurysms treated with FRED Junior that achieved 100% occlusion at 12 months, with 7% complications and a mortality rate of 2%. Rautio *et al*<sup>19</sup> reported an 87% occlusion rate between 6 and 24 months of follow-up in 15 patients treated with FRED Junior. Larger studies are needed in order to draw conclusions about the safety and efficacy of these stents.

Finally, no previous studies of FRED devices have analyzed predictors of final aneurysm occlusion at long-term follow-up. We have described three predictors of final occlusion: immediate post-procedure OKM grade B–C–D, single aneurysms, and small-sized aneurysms. These data can help to select the best candidates for treatment with this stent.

Limitations of the study were the relatively small number of cases, which limited the conclusions that could be drawn. A neurologist provided clinical follow-up but was not blinded to the procedure used, and there was no external evaluation of the angiographic results.

## CONCLUSIONS

From the results obtained in our series, we conclude that the FRED stent is a simple management tool that meets all safety and efficacy criteria for the treatment of cerebral aneurysms, as demonstrated by the low morbidity and mortality rates obtained. Patients with a single small aneurysm and an immediate OKM grade of B–C–D were more likely to achieve total occlusion.

**Twitter** Elio Vivas @evivas

**Contributors** All authors made substantial contributions to the conception and design of the work, or the acquisition of data, analysis or interpretation of data; and drafting or revising it critically for important intellectual content; and final approval of the submitted version. All authors agree to be accountable for all aspects of the work in ensuring that questions related to the accuracy or integrity of any part of the work are appropriately investigated and resolved.

**Funding** The authors have not declared a specific grant for this research from any funding agency in the public, commercial or not-for-profit sectors.

**Competing interests** None declared.

**Patient consent for publication** Not required.

**Provenance and peer review** Not commissioned; externally peer reviewed.

**Data availability statement** Data are available upon reasonable request.

**Open access** This is an open access article distributed in accordance with the Creative Commons Attribution Non Commercial (CC BY-NC 4.0) license, which

permits others to distribute, remix, adapt, build upon this work non-commercially, and license their derivative works on different terms, provided the original work is properly cited, appropriate credit is given, any changes made indicated, and the use is non-commercial. See: <http://creativecommons.org/licenses/by-nc/4.0/>.

## ORCID iD

Angel Ois <http://orcid.org/0000-0002-1375-5950>

## REFERENCES

- Moret J, Cognard C, Weill A, *et al*. The "remodelling technique" in the treatment of wide neck intracranial aneurysms. Angiographic results and clinical follow-up in 56 cases. *Interv Neuroradiol* 1997;3:21–35.
- Shapiro M, Becske T, Sahlein D, *et al*. Stent-supported aneurysm coiling: a literature survey of treatment and follow-up. *AJNR Am J Neuroradiol* 2012;33:159–63.
- Sadasivan C, Dholakia R, Woo HH, *et al*. Hemodynamics of flow diverters. *J Biomech Eng* 2016;139:021002.
- Möhlenbruch MA, Herweh C, Jestaedt L, *et al*. The FRED flow-diverter stent for intracranial aneurysms: clinical study to assess safety and efficacy. *AJNR Am J Neuroradiol* 2015;36:1155–61.
- Kocer N, Islak C, Kizilkilic O, *et al*. Flow Re-direction Endoluminal Device in treatment of cerebral aneurysms: initial experience with short-term follow-up results. *J Neurosurg* 2014;120:1158–71.
- Matsuda Y, Chung J, Keigher K, *et al*. A comparison between the new Low-profile Visualized Intraluminal Support (LVIS blue) stent and the Flow Redirection Endoluminal Device (FRED) in bench-top and cadaver studies. *J Neurointerv Surg* 2018;10:274–8.
- Berg P, Iosif C, Ponsonnard S, *et al*. Endothelialization of over- and undersized flow-diverter stents at covered vessel side branches: an in vivo and in silico study. *J Biomech* 2016;49:4–12.
- Chalouhi N, Tjoumakaris SI, Gonzalez LF, *et al*. Spontaneous delayed migration/shortening of the pipeline embolization device: report of 5 cases. *AJNR Am J Neuroradiol* 2013;34:2326–30.
- Nichols W. Clinical measurement of arterial stiffness obtained from noninvasive pressure waveforms. *Am J Hypertens* 2005;18:3–10.
- O'Kelly CJ, Krings T, Fiorella D, *et al*. A novel grading scale for the angiographic assessment of intracranial aneurysms treated using flow diverting stents. *Interv Neuroradiol* 2010;16:133–7.
- Joshi MD, O'Kelly CJ, Krings T, *et al*. Observer variability of an angiographic grading scale used for the assessment of intracranial aneurysms treated with flow-diverting stents. *AJNR Am J Neuroradiol* 2013;34:1589–92.
- Killer-Oberpalzer M, Kocer N, Griessenauer CJ, *et al*. European multicenter study for the evaluation of a dual-layer flow-diverting stent for treatment of wide-neck intracranial aneurysms: the European Flow-Redirection Intraluminal Device Study. *AJNR Am J Neuroradiol* 2018;39:841–7.
- Drescher F, Weber W, Berlis A, *et al*. Treatment of intra- and extracranial aneurysms using the Flow-Redirection Endoluminal Device: multicenter experience and follow-up results. *AJNR Am J Neuroradiol* 2017;38:105–12.
- Briganti F, Leone G, Marseglia M, *et al*. Endovascular treatment of cerebral aneurysms using flow-diverter devices: a systematic review. *Neuroradiol J* 2015;28:365–75.
- Piano M, Valvassori L, Lozupone E, *et al*. FRED Italian registry: a multicenter experience with the flow re-direction endoluminal device for intracranial aneurysms. *J Neurosurg* 2019:1–8.
- Pierot L, Spelle L, Berge J, *et al*. SAFE study (safety and efficacy analysis of FRED embolic device in aneurysm treatment): 1-year clinical and anatomical results. *J Neurointerv Surg* 2019;11:184–9.
- Pierot L, Spelle L, Berge J, *et al*. Feasibility, complications, morbidity, and mortality results at 6 months for aneurysm treatment with the Flow Re-Direction Endoluminal Device: report of SAFE study. *J Neurointerv Surg* 2018;10:765–70.
- Möhlenbruch MA, Kizilkilic O, Killer-Oberpalzer M, *et al*. Multicenter experience with FRED Jr Flow Re-Direction Endoluminal Device for intracranial aneurysms in small arteries. *AJNR Am J Neuroradiol* 2017;38:1959–65.
- Rautio R, Rahi M, Katila A, *et al*. Single-center experience with six-month follow-up of FRED Jr® flow diverters for intracranial aneurysms in small arteries. *Acta Radiol* 2019;60:917–24.