

Original research

Middle meningeal artery embolization for chronic subdural hematoma: an institutional technical analysis

Joshua S Catapano,¹ Andrew F Ducruet,¹ Candice L Nguyen,¹ Jacob F Baranoski,¹ Tyler S Cole ,¹ Neil Majmundar ,² D Andrew Wilkinson,² Vance L Fredrickson,³ Daniel D Cavalcanti,¹ Felipe C Albuquerque¹

¹Department of Neurosurgery, Barrow Neurological Institute, Phoenix, Arizona, USA

²Barrow Neurological Institute, Phoenix, Arizona, USA

³Department of Neurosurgery, University of Southern California, Los Angeles, California, USA

Correspondence to

Dr Felipe C Albuquerque, Department of Neurosurgery, Barrow Neurological Institute, Phoenix, AZ 85013-4409, USA; Felipe.Albuquerque@barrowbrainandspine.com

Received 24 June 2020

Revised 29 September 2020

Accepted 1 October 2020

Published Online First

19 October 2020

ABSTRACT

Background Recently, middle meningeal artery (MMA) embolization has emerged as a potentially safe and effective method of treating chronic subdural hematoma (cSDH).

Objective To report a single-center experience with MMA embolization and examines the type of embolic material used, the extent of penetration, and the number of MMA branches embolized.

Methods A retrospective analysis of all patients with MMA embolization from 2018 through 2019 was performed. A failed outcome was defined as either surgical rescue and/or greater than 10 mm of hematoma residual or reaccumulation following embolization.

Results Of 35 patients, surgery had failed for 9 (26%) and initial conservative treatment had failed for 6 (17%). Of 41 MMA embolizations, including those in six patients with bilateral cSDH who underwent bilateral MMA embolization, 29 (72%) were performed using ethylene vinyl alcohol copolymer (Onyx), 7 (17%) using particles, and 5 (12%) using n-butyl cyanoacrylate. Both the anterior and posterior MMA divisions were embolized in 29 cases (71%); distal penetration of these branches was achieved in 25 embolizations (61%). Twenty-six (63%) cSDHs completely resolved. Complete resolution was seen in 22 of 29 hematomas (76%) in which both anterior and posterior MMA branches were occluded versus 4 of 12 (33%) following single-branch embolization ($p=0.014$). Embolization of one cSDH (2%) failed.

Conclusion MMA embolization of cSDHs appears to be both safe and efficacious. Furthermore, embolization of both the anterior and posterior MMA branches may be associated with increased odds of complete resolution.

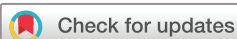INTRODUCTION

Chronic subdural hematoma (cSDH) is one of the most common neurological diseases and causes significant morbidity and mortality, especially among the elderly population.^{1–3} Surgical evacuation using bur holes or craniotomy remains the first-line treatment, especially for patients with significant brain compression, causing neurological symptoms. However, approximately 5–10% of patients require multiple procedures within 30–60 days.^{4,5} Patients without neurological symptoms and/or cerebral mass effect typically receive

conservative treatment with close follow-up for progression of hemorrhage and/or symptoms. Even patients who receive conservative treatment have conditions that progress, requiring surgical intervention, with reports that as many as 84% of patients eventually need invasive treatment.⁶ Recently, middle meningeal artery (MMA) embolization has emerged as a potentially safe and effective method of treating cSDHs.^{6–11} Pertinent literature, however, remains limited, and consists of mostly small case series and individual case reports. In addition, none of the existing studies have compared different techniques for MMA embolization. This study reports a single-center experience with MMA embolization for cSDH and provides an analysis of surgical outcome by radiographic measure on follow-up imaging and clinical measures using the modified Rankin Scale (mRS) score and procedural complications. The primary aim of the report is to analyze various techniques used, including type of access approach (femoral vs radial), embolic material used, the extent of penetration, and the MMA branches embolized.

METHODS

The endovascular treatment database at our institution (Barrow Neurological Institute, Phoenix, Arizona, USA) was retrospectively analyzed for all patients who underwent MMA embolization between January 1, 2018 and December 31, 2019. The study protocol was approved by St Joseph's Hospital and Medical Center's institutional review board in Phoenix, Arizona. The need for informed consent was waived owing to the low risk to study subjects. A total of 231 patients with a cSDH of at least 8 mm were managed at the institution during the study period. Forty patients underwent MMA embolization for cSDH. A variety of embolic agents were used for these procedures, including microspheres, n-butyl cyanoacrylate (nBCA), and ethylene vinyl alcohol copolymer (Onyx). The type of embolic agent used was based on attending preference, with a shift toward Onyx during the latter part of the study. When using Onyx, we typically establish a wedged catheter position distally and push Onyx through distal collaterals to other MMA vessels, allowing reflux back along the catheter to occlude the branch proximally. In each case, an attempt was made to achieve distal penetration and



© Author(s) (or their employer(s)) 2021. No commercial re-use. See rights and permissions. Published by BMJ.

To cite: Catapano JS, Ducruet AF, Nguyen CL, et al. *J NeuroIntervent Surg* 2021;**13**:657–660.

allow reflux of the material proximally to occlude the MMA division, taking care to avoid penetration into collaterals to the orbit as well as the petrosal branch at the skull base. Patients with less than 30 days of follow-up were excluded, leaving 35 patients with a total of 41 cSDHs who were included in the study analysis. Information such as demographic characteristics, cSDH characteristics, cSDH treatment, procedural complications, and outcome were abstracted from the electronic medical record. Patients are followed up monthly with imaging until cSDH has resolved or the patient is stable without symptoms. A failed outcome was defined as either the need for surgical rescue at any time point and/or greater than 10 mm of hematoma residual or reaccumulation after MMA embolization on last follow-up imaging at least 30 days after embolization. Secondary outcomes included complete resolution of the cSDH and change in cSDH size on last follow-up imaging. cSDH sizes were measured on 2D axial CT, with complete resolution defined as no hematoma visualized on the last follow-up CT. Furthermore, change in cSDH size was measured as the hematoma difference from last-follow up CT (or when surgical rescue occurred) from the CT immediately prior to embolization. Depth of penetration was a subjective measurement but, in general, was defined as embolization close to the apex of the artery.

Statistical analysis

Statistical analysis was performed using SPSS Statistics Windows, version 26 (IBM Corp., Armonk, New York, USA). Patient demographic characteristics, SDH characteristics, and outcomes were reported using percentage and/or frequency. Comparisons of hematoma size and change in size were performed using independent sample t-test. χ^2 test was used to analyze treatment failure and complete resolution of the hematoma. A p value less than 0.05 was considered statistically significant.

RESULTS

Thirty-five patients were included in this analysis (mean±SD age, 68±12 years). Table 1 presents the demographic and clinical characteristics of these patients. The two most common presenting symptoms were focal neurological deficit (15 patients; 43%) and headache (14 patients; 40%). Surgery had previously failed for nine patients (26%), and conservative treatment had failed for six patients (17%). Transradial access was used in 21 patients (60%), with the balance of cases treated via a transfemoral approach. The mean preoperative mRS score was 2.0±1.4, and the mean follow-up mRS score was 1.7±1.2 with a mean follow-up of 120±75 days. Ten patients (29%) had a mRS score greater than 2, and one patient (3%) had a worse mRS score on follow-up. Only one patient (3%) experienced a procedural complication occurred, a cerebrovascular accident in a patient with a type III arch who underwent transfemoral embolization.

Table 1 includes the characteristics of the 41 cSDH procedures. Embolic agents included Onyx (n=29; 71%), particles (n=7; 17%), and nBCA (n=5; 12%). Both the anterior and posterior MMA divisions were occluded in 29 cSDHs (71%). Both proximal and distal penetration of these branches was achieved in 25 (61%) hematomas. Twenty-six cSDHs (63%) were completely resolved (figure 1), and surgical evacuation was required in only a single hematoma (2%).

No statistical differences in mean preoperative versus post-operative hematoma size, or change in size, was found when examining embolic materials (Onyx vs nBCA vs particles and/or coils), branches embolized (anterior and posterior vs anterior or posterior only), and depth of embolization (distal and proximal vs proximal only) (tables 2–4). In addition, no significant

Table 1 Demographic and clinical characteristics and outcomes for 35 patients who underwent 41 middle meningeal artery embolization procedures for treatment of chronic subdural hematoma

	Patients (n=35)
Patient characteristic	
Age, years, mean±SD	68±12
Male sex	25 (71)
Previous trauma	23 (66)
Anticoagulant/antiplatelet	14 (40)
Main presenting symptom	
Headache	14 (40)
Focal neurological deficit	15 (43)
Seizures	3 (9)
Incidental	3 (9)
Altered mental status	7 (20)
Gait instability/falls	6 (17)
Surgery with adjunct embolization	2 (6)
Surgery failed	9 (26)
Conservative treatment failed	6 (17)
cSDH embolization side	
Right	16 (46)
Left	13 (37)
Bilateral	6 (17)
Acute/subacute on chronic	21 (60)
Transradial	21 (60)
mRS score at presentation, mean±SD	2.0±1.4
Embolization complication	1 (3)*
Follow-up, days, mean±SD	120±75
Follow-up mRS score, mean±SD	1.7±1.2
mRS score >2 on follow-up	10 (29)
Worse mRS score on follow-up	1 (3)
	Procedures (n=41)
Procedure characteristic	
Embolic agent	
Onyx	29 (71)
Particles and/or coils	7 (17)
nBCA	5 (12)
MMA branches embolized	
Posterior or anterior only	12 (29)
Both posterior and anterior	29 (71)
Embolization penetration	
Proximal	16 (39)
Distal and proximal	25 (61)
Complete resolution	26 (63)
Treatment failure	1 (2)

Data are no. (%) of patients or procedures unless otherwise indicated.

*Left middle cerebral artery stroke was experienced by a patient with transfemoral and particle/coil treatment.

cSDH, chronic subdural hematoma; MMA, middle meningeal artery; mRS, modified Rankin Scale; nBCA, n-butyl cyanoacrylate; Onyx, ethylene vinyl alcohol copolymer.

difference was found in the outcome measures (complete resolution vs failed treatment) between the various embolic agents or depths of penetration. However, a higher percentage of patients had complete resolution of cSDH when both MMA divisions

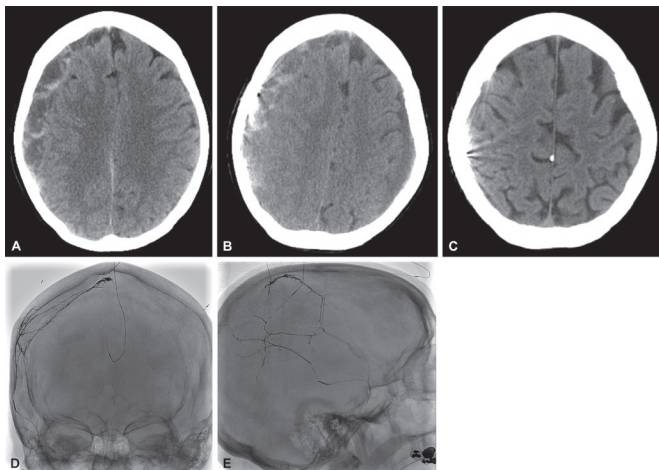


Figure 1 CT scan showing a large right subacute chronic subdural hematoma before middle meningeal artery (MMA) embolization (A), immediately after MMA embolization (B), and complete resolution (C) on 6-month follow-up. Unsubtracting posterior-anterior (D) and lateral (E) view angiography showing ethylene vinyl alcohol copolymer (Onyx) embolization of both the anterior and posterior branches of the MMA and with distal embolization of the anterior branch to the vertex. Reproduced, with permission, from Barrow Neurological Institute, Phoenix, Arizona.

(anterior and posterior) were occluded (figure 1) relative to occlusion of only one of the divisions (22/29 (76%) vs 4/12 (33%); $p=0.014$).

DISCUSSION

The incidence of cSDH is projected to increase in the coming decades as the population ages. Potentially 60000 Americans will experience a cSDH annually in the next 10 years.³ MMA embolization has emerged as an alternative treatment for cSDHs due to its minimally invasive nature and apparent efficacy. This procedure was first described by Mandai *et al* in 2000 with a single patient whose cSDH was successfully treated using MMA embolization.¹² More recently, multiple case reports and series have suggested that MMA embolization is effective in the treatment of cSDH, with a high rate of hematoma resolution and a low rate of complications.¹²⁻¹⁹ For example, Link *et al* examined 60 cSDHs in 49 patients and found 41 patients (84%) to have hemorrhages that were stable or decreased

Table 3 Preoperative hematoma size, postoperative hematoma size, change in hematoma size (mean±SD), and radiographic outcomes of chronic subdural hematoma procedures by branches embolized

	Distal and proximal (n=25)	Proximal only (n=16)	P value
Preoperative hematoma size (cm)	15.8±3.0	13.9±4.9	0.15
Postoperative hematoma size (cm)	2.5±3.5	2.1±3.4	0.75
Change in hematoma size (cm)	13.2±5.0	11.8±4.8	0.36
No. (%) of procedures with complete resolution	16 (64)	10 (63)	0.92
No. (%) of procedures with treatment failure	0 (0)	1 (6)	0.21

in size with no significant procedural complications.⁹ Similarly, Ban *et al* analyzed 72 patients with cSDHs treated via MMA embolization and found only one patient with a treatment failure (defined as either rescue surgery and/or >10mm of hemorrhage found on postoperative imaging), and no patients experienced complications.⁶ By comparison, in our study, only one patient (3%) experienced a treatment-related complication, and more than 97% of patients had successful MMA embolization with reduction of their hematoma without the need for additional interventions. Notably, the complication occurred early in our series in a patient with a type III arch for whom femoral access was used.

Given the significant vascular comorbidities often seen in this patient population, we subsequently began to assess aortic arch vessel imaging prior to these interventions and transitioned almost exclusively to a radial approach. Furthermore, of the cSDHs embolized, over 60% were completely resolved within 4–6 weeks on follow-up imaging.

Because MMA embolization for cSDHs remains a relatively novel procedure, direct comparison of techniques is lacking. Such evaluations are necessary to optimize this treatment. For instance, after entering the cranium through the foramen spinosum, the MMA courses through a groove in the greater wing of the sphenoid and divides into two branches, the anterior and posterior branches.²⁰ In the present analysis, embolization of both branches (relative to a single branch) was associated with a significantly higher frequency of complete resolution of the hematoma. In fact, none of the patients who underwent embolization of both branches experienced treatment failure. Once the MMA divides into the anterior and posterior branches, both branches continue distally to supply the dura (the anterior branch divides into small distal branches at the sphenoid

Table 2 Preoperative hematoma size, postoperative hematoma size, change in hematoma size (mean±SD), and radiographic outcomes of chronic subdural hematoma procedures by embolic material used

	Onyx (n=29)	nBCA (n=5)	Particles and/or coils (n=7)	P value
Preoperative hematoma size (cm)	15.1±3.3	13.4±5.0	15.6±5.7	0.59
Postoperative hematoma size (cm)	2.2±3.4	3.7±2.1	2.3±4.5	0.66
Change in hematoma size (cm)	13.0±4.8	9.7±5.6	13.3±5.0	0.35
No. (%) of procedures with complete resolution	20 (69)	6 (50)		0.25
No. (%) of procedures with treatment failure	0 (0)	1 (8)		0.12

nBCA, n-butyl cyanoacrylate; Onyx, ethylene vinyl alcohol copolymer.

Table 4 Preoperative hematoma size, postoperative hematoma size, change in hematoma size (mean±SD), and radiographic outcomes of chronic subdural hematoma procedures by depth of embolization.

	Anterior and posterior (n=29)	Anterior or posterior only (n=12)	P value
Preoperative hematoma size (cm)	15.2±3.6	14.5±4.7	0.61
Postoperative hematoma size (cm)	1.9±3.1	3.5±4.0	0.17
Change in hematoma size (cm)	13.3±4.9	11.0±4.8	0.17
No. (%) of procedures with complete resolution	22 (76)	4 (33)	0.01
No. (%) of procedures with treatment failure	0 (0)	1 (8)	0.12

angle of the parietal bone that eventually reach the vertex and occipital region, whereas the posterior branch arcs on the squamosal portion of the temporal bone, eventually branching into small distal arteries, at the parietal bone in front of the mastoid angle, which supply the posterior dura of the cranium).²⁰ In the current analysis, although none of the patients for whom both distal and proximal MMA embolization was accomplished experienced treatment failure, this comparison was not statistically significant.

The majority of previous studies reported the use of micro-particles.^{6,9,11,21} Our analysis found no statistically significant difference between various embolic agents. Over time, we have transitioned to using Onyx for the majority of cSDH embolizations, and we have noted neither complications nor treatment failures using this material. Additionally, nearly 70% of the cSDHs embolized with Onyx completely resolved on short-term follow-up. Similarly, Waquas *et al* performed MMA embolization with Onyx in eight patients and reported no recurrences.²¹ Onyx may allow for deeper penetration, possibly preventing collateral vessel formation.²² Furthermore, Onyx or other liquid embolic agents are permanent, and their use may avoid delayed recanalization, which might occur with particles.²² However, it should be mentioned that owing to its potential to penetrate smaller vessels, Onyx must be used with caution in the presence of dangerous anastomoses, and existing variants of the MMA origin from the ophthalmic artery are possible.^{23,24} Moreover, knowledge of cranial nerve blood supply for embolization with any embolic agent is imperative. In particular, the petrous branch of the MMA is a significant supplier to the facial nerve. Injury to the nerve may cause debilitating neurological and cosmetic complications.²³

It should be also remembered that injecting Onyx into the MMA is extremely painful, and thus general anesthesia or prior lidocaine injection is required.²⁵ In our series, we performed the vast majority of these cases with the patient under general anesthesia to improve visibility during the injection. Given the medical frailty of these patients, an approach using conscious sedation may ultimately be preferred, or at a minimum, immediate postoperative extubation should be prioritized.

Traditionally, femoral artery access has been used for neuro-endovascular procedures; however, successful treatments have been performed recently with radial artery access, which are associated with lower complication rates.²⁶ During the study, our institution moved into a radial first practice due to these lower rates of access site complications. Of the 21 patients with radial access, none experienced a complication or treatment failure. Hence, a transradial approach for MMA embolization of cSDH provides similar treatment success to that of transfemoral access but without the potentially life-threatening access site complications.

Owing to its retrospective nature, this study is subject to all of the biases inherent in retrospective analyses, as well as those inherent in studies with small sample sizes. In addition, treatment approaches and outcome measures were determined on the basis of the on-call attending physicians' preferences without a set institutional algorithm or protocols for follow-up imaging. However, in general, treatment approaches are primarily based on three categories: observation with or without medical treatment such as corticosteroids or statins in patients with small asymptomatic cSDHs <8 mm in diameter, MMA embolization or observation in patients without focal neurologic deficit with cSDHs ≥8 mm in diameter and with or without midline shift, surgery with or without MMA embolization in patients with symptomatic or large cSDH with >5 mm midline shift. Outcome

measures are based on radiographic measure on monthly follow-up imaging and clinical measure using the mRS score. These factors impose further possible selection bias to this study.

CONCLUSION

Our institution's experience with MMA embolization for cSDH has demonstrated promising outcomes and is associated with a low rate of treatment failure. In addition, as MMA embolization for cSDH has evolved, our center now favors transradial access for Onyx embolization, which is both safe and efficacious. Furthermore, embolization of both the anterior and posterior MMA branches may be associated with increased odds of complete resolution.

Acknowledgements The authors thank the Neuroscience Publications staff at Barrow Neurological Institute for assistance with manuscript preparation.

Contributors All authors made substantial contributions to the conception or design of the work; or the acquisition, analysis, or interpretation of data for the work; and drafted the work or revised it critically for important intellectual content; and provided final approval of the version to be published; and agree to be accountable for all aspects of the work in ensuring that questions related to the accuracy or integrity of any part of the work are appropriately investigated and resolved.

Funding The authors have not declared a specific grant for this research from any funding agency in the public, commercial or not-for-profit sectors.

Competing interests AFD is a consultant for Medtronic, Penumbra, Cerenovus, Stryker, and Koswire.

Patient consent for publication Not required.

Provenance and peer review Not commissioned; externally peer reviewed.

Data availability statement There are no additional data to share.

ORCID iDs

Tyler S Cole <http://orcid.org/0000-0003-3165-6048>

Neil Majmundar <http://orcid.org/0000-0001-5910-6094>

REFERENCES

- Miranda LB, Braxton E, Hobbs J, *et al*. Chronic subdural hematoma in the elderly: not a benign disease. *J Neurosurg* 2011;114:72–6.
- Uno M, Toi H, Hirai S. Chronic subdural hematoma in elderly patients: is this disease benign? *Neurol Med Chir* 2017;57:402–9.
- Balser D, Farooq S, Mehmood T, *et al*. Actual and projected incidence rates for chronic subdural hematomas in United States Veterans administration and civilian populations. *J Neurosurg* 2015;123:1209–15.
- Brennan PM, Koliass AG, Joannides AJ, *et al*. The management and outcome for patients with chronic subdural hematoma: a prospective, multicenter, observational cohort study in the United Kingdom. *J Neurosurg* 2017;1–8.
- Knopman J, Link TW, Navi BB, *et al*. Rates of repeated operation for isolated subdural hematoma among older adults. *JAMA Netw Open* 2018;1:e183737.
- Ban SP, Hwang G, Byoun HS, *et al*. Middle meningeal artery embolization for chronic subdural hematoma. *Radiology* 2018;286:992–9.
- Srivatsan A, Mohanty A, Nascimento FA, *et al*. Middle meningeal artery embolization for chronic subdural hematoma: meta-analysis and systematic review. *World Neurosurg* 2019;122:613–9.
- Kim E. Embolization therapy for refractory hemorrhage in patients with chronic subdural hematomas. *World Neurosurg* 2017;101:520–7.
- Link TW, Kamel H, Knopman J, *et al*. Middle meningeal artery embolization for chronic subdural hematoma: a series of 57 cases. *Neurosurgery* 2018;65:129.
- Nakagawa I, Park HS, Kotsugi M, *et al*. Enhanced hematoma membrane on DynaCT images during middle meningeal artery embolization for persistently recurrent chronic subdural hematoma. *World Neurosurg* 2019;126:e473–9.
- Okuma Y, Hirotsune N, Sato Y, *et al*. Midterm follow-up of patients with middle meningeal artery embolization in intractable chronic subdural hematoma. *World Neurosurg* 2019;126:e671–8.
- Mandai S, Sakurai M, Matsumoto Y. Middle meningeal artery embolization for refractory chronic subdural hematoma. *J Neurosurg* 2000;93:686–8.
- Tsukamoto Y, Oishi M, Shinbo J, *et al*. Transarterial embolisation for refractory bilateral chronic subdural hematomas in a case with dentatorubral-pallidolusian atrophy. *Acta Neurochir* 2011;153:1145–7.
- Tempaku A, Yamauchi S, Ikeda H, *et al*. Usefulness of interventional embolization of the middle meningeal artery for recurrent chronic subdural hematoma: five cases and a review of the literature. *Interv Neuroradiol* 2015;21:366–71.

- 15 Mino M, Nishimura S, Hori E, *et al.* Efficacy of middle meningeal artery embolization in the treatment of refractory chronic subdural hematoma. *Surg Neurol Int* 2010;1:78.
- 16 Mewada T, Ohshima T, Yamamoto T, *et al.* Usefulness of embolization for iatrogenic dural arteriovenous fistula associated with recurrent chronic subdural hematoma: a case report and literature review. *World Neurosurg* 2016;92:584.e7–584.e10.
- 17 Matsumoto H, Hanayama H, Okada T, *et al.* Which surgical procedure is effective for refractory chronic subdural hematoma? Analysis of our surgical procedures and literature review. *J Clin Neurosci* 2018;49:40–7.
- 18 Kang J, Whang K, Hong S-K, *et al.* Middle meningeal artery embolization in recurrent chronic subdural hematoma combined with arachnoid cyst. *Korean J Neurotrauma* 2015;11:187–90.
- 19 Ishihara H, Ishihara S, Kohyama S, *et al.* Experience in endovascular treatment of recurrent chronic subdural hematoma. *Interv Neuroradiol* 2007;13 Suppl 1:141–4.
- 20 Martins C, Yasuda A, Campero A, *et al.* Microsurgical anatomy of the dural arteries. *Neurosurgery* 2005;56:211–51.
- 21 Waqas M, Vakhari K, Weimer PV, *et al.* Safety and effectiveness of embolization for chronic subdural hematoma: systematic review and case series. *World Neurosurg* 2019;126:228–36.
- 22 Fiorella D, Arthur AS. Middle meningeal artery embolization for the management of chronic subdural hematoma. *J Neurointerv Surg* 2019;11:912–5.
- 23 Geibprasert S, Pongpech S, Armstrong D, *et al.* Dangerous extracranial-intracranial anastomoses and supply to the cranial nerves: vessels the neurointerventionalist needs to know. *AJNR Am J Neuroradiol* 2009;30:1459–68.
- 24 Kimball D, Kimball H, Tubbs RS, *et al.* Variant middle meningeal artery origin from the ophthalmic artery: a case report. *Surg Radiol Anat* 2015;37:105–8.
- 25 Ne R, Chevallier O, Falvo N, *et al.* Embolization with ethylene vinyl alcohol copolymer (Onyx®) for peripheral hemostatic and non-hemostatic applications: a feasibility and safety study. *Quant Imaging Med Surg* 2018;8:280–90.
- 26 Catapano JS, Fredrickson VL, Fujii T, *et al.* Complications of femoral versus radial access in neuroendovascular procedures with propensity adjustment. *J Neurointerv Surg* 2020;12:611–5.