Review

Management of vascular causes of pulsatile tinnitus

Kazim H Narsinh ,[1] Ferdinand Hui ,[2] Madhavi Duvvuri,[3] Karl Meisel,[4] Matthew R Amans [3]

► Additional supplemental material is published online only. To view, please visit the journal online (http://dx.doi.org/10.1136/neurintsurg-2021-018015).

[1]Neurointerventional Radiology, University of California San Francisco, San Francisco, California, USA
[2]Neurointerventional Radiology, Johns Hopkins University, Baltimore, Maryland, USA
[3]Radiology and Biomedical Imaging, University of California San Francisco, San Francisco, California, USA
[4]Neurology, University of California San Francisco, San Francisco, California, USA

Correspondence to
Dr Kazim H Narsinh, University of California San Francisco, San Francisco, California, USA; kazim.narsinh@ucsf.edu

Received 14 July 2021
Accepted 23 January 2022
Published Online First 10 February 2022

To cite: Narsinh KH, Hui F, Duvvuri M, *et al*. *J NeuroIntervent Surg* 2022;**14**:1151–1157.

ABSTRACT

Pulsatile tinnitus is a debilitating symptom affecting millions of Americans and can be a harbinger of hemorrhagic or ischemic stroke. Careful diagnostic evaluation of pulsatile tinnitus is critical in providing optimal care and guiding the appropriate treatment strategy. When a vascular cause of pulsatile tinnitus has been established, attention must be focused on the patient's risk of hemorrhagic stroke, ischemic stroke, or blindness, as well as the risks of the available treatment options, in order to guide decision-making. Herein we review our approach to management of the vascular causes of pulsatile tinnitus and provide a literature review while highlighting gaps in our current knowledge and evidence basis.

INTRODUCTION

Pulsatile tinnitus (PT) is a symptom referring to an abnormal perception of rhythmic sound without an extracorporeal source that impacts between 3 and 5 million Americans.[1–4] PT can have a tremendous impact on patients' psychological and physical health, leading to insomnia, anxiety, depression, and poor concentration.[5] Seeking an underlying cause of PT is essential because many of them pose a significant risk of hemorrhagic stroke, ischemic stroke, or blindness to the patient. Hence some of the causes of PT warrant treatment to mitigate risk of stroke or blindness, while other causes may be treated to address the symptom itself and its psychiatric comorbidities. Advances in neuroimaging and endovascular treatment have resulted in increased detection of vascular causes[6 7] and therapeutic options have burgeoned. Once a vascular etiology has been established, treatment recommendations should be based on the natural history of the disease, treatment risks, and the efficacy of treatment. This article will review the literature related to the management of vascular causes of PT, address gaps in knowledge and evidence, and provide a blueprint for future studies.

METHODS

Literature search strategy and selection criteria

For this narrative review, a literature search was performed by the authors of the PubMed and PMC databases, for peer-reviewed studies published from 1975 to 2021 in the English language using the following key words: 'pulsatile tinnitus' (Title) + '(cause of pulsatile tinnitus)' + 'management' or 'treatment'. For 'cause of pulsatile tinnitus', keywords included: 'atherosclerotic carotid artery disease', 'intracranial arterial aneurysms', 'arteriovenous malformations', 'arteriovenous fistulas', 'dural arteriovenous fistulas', 'fistula', 'internal carotid artery', 'idiopathic intracranial hypertension', 'venous abnormalities', 'jugular bulb abnormality', 'sigmoid sinus abnormality', 'sigmoid sinus dehiscence', 'emissary vein', 'glomus tumor', 'superior semicircular canal dehiscence', and 'metabolic cause' and 'systemic cause'. In addition, we performed a reverse bibliography search from previously published systematic reviews or meta-analyses. Each study was critically reviewed. Duplicates generated across multiple searches were excluded. Articles were included if pulsatile tinnitus was referenced during the pre-interventional or post-interventional period. Studies that did not specify the interventional technique or outcome of the procedure were excluded. Studies were excluded if subsequent papers looked at outcomes from the same patient group. Non-full text articles were excluded. The PRISMA (Preferred Reporting Items for Systematic Reviews and Meta-Analyses) flow diagram is shown in online supplemental figure 1).

Data extraction

Each study was analyzed by two independent reviewers (MD, KHN) to assess clinical outcomes, including improvement or resolution of symptoms (ie, clinical success), rate of complication (ie, technical success), and the limitations of the work. In cases of disagreement between the two reviewers, a third reviewer (MRA) served as adjudicator.

MANAGEMENT OF VASCULAR CAUSES OF PT

Venous

Among vascular causes of PT, a venous etiology can often be distinguished from an arterial etiology on the basis of history and physical examination. Venous PT is described as a lower pitched 'whooshing' sound that can be alleviated by neck maneuvers. In particular, compression of the ipsilateral internal jugular vein (IJV) or suboccipital venous plexus can alleviate symptoms, while compression of the contralateral IJV can exacerbate symptoms. When a venous cause of PT is suspected, we find cerebral venous manometry and balloon test occlusion to be a critical part of the diagnostic evaluation that guides subsequent management (see UCSF Cerebral Venous Disorder Testing form included as online supplemental material). This detailed evaluation is typically performed with the patient awake in order to accurately assess intracranial venous pressures and subjective PT.

Idiopathic intracranial hypertension

A common venous cause of PT is idiopathic intracranial hypertension (IIH). IIH has an incidence of 20 per 100 000 overweight women of childbearing age, with increasing prevalence due to the obesity epidemic. Multiple medications and substances have been linked to IIH, with the most evidence available for an association between IIH and hypervitaminosis A, tetracyclines, and growth hormone. Stopping these medications may result in resolution of IIH symptoms. For most IIH patients, first-line treatment consists of weight loss and acetazolamide.[8] Acetazolamide is a carbonic anhydrase inhibitor that reduces the rate of cerebrospinal fluid (CSF) production. The NORDIC (Neuro-Ophthalmology Research Disease Investigator Consortium) trial was a multicenter, randomized, double-masked, placebo-controlled study of acetazolamide with a low-sodium weight-reduction diet versus a low-sodium weight-reduction diet alone in 165 patients with IIH meeting the modified Dandy criteria and having mild visual loss.[8] The trial found that perimetric mean deviation (a measure of global visual field loss), papilledema grade, and CSF opening pressure was improved in patients taking acetazolamide versus controls at 6 months follow-up. Based on these results, first-line treatment for IIH consists of a low-sodium weight-reduction diet and acetazolamide dose-escalation until 2–4 g per day are tolerated. Relative contraindications to acetazolamide include sulfa allergy and pregnancy. Acetazolamide has multiple side effects that can make medication adherence difficult. These include, for example, oral and digital paresthesias, malaise, metallic taste, fatigue, nausea, vomiting, metabolic acidosis, and nephrolithiasis. Topiramate also inhibits carbonic anhydrase activity, and is effective in the treatment of migraine headache and facilitating weight loss. These features have made topirimate a potential alternative therapeutic option in IIH, although data supporting its efficacy for visual field improvement are limited to case series.

IIH patients who have progressive visual loss or headache, and have failed, are intolerant to, or are non-compliant with medical therapy, may benefit from operative intervention. Operations include optic nerve sheath fenestration (ONSF), CSF diversion, bariatric surgery, and venous sinus stenting.

After ONSF, the majority of patients have improved papilledema and visual fields. However, approximately 20% of ONSF patients will have deterioration after initial improvement, and most of these patients will go on to need additional surgery, typically either additional ONSF or CSF diversion.[9 10] Major vascular complications are most likely to occur during the second ONSF.[10] In most series, the complication rate from ONSF is high, ranging from 20–40%.[10 11] The most common complications are ocular motility disorders (eg, diplopia due to cranial nerve palsy) or pupillary dysfunction (eg, anisocoria) that are often transient; however, more serious complications, such as central retinal artery occlusions, orbital hematomas, orbital apex syndrome, orbital cellulitis, optic disc hemorrhage, or traumatic optic neuropathy, also occur.

After CSF diversion for IIH, most patients have improved headache, papilledema, and/or visual acuity. However, CSF diversion has a very high rate of revision surgery of up to 43%, usually due to shunt obstruction/failure or low-pressure headache.[11 12] In addition, CSF diversion has a high complication rate of up to 33%, including shunt infection, subdural hematoma, and CSF leak.[11 12]

Bariatric surgery, such as Roux-en-Y gastric bypass, sleeve gastrectomy, or gastric banding, has also been proposed as a treatment for IIH because of the strong association between obesity and IIH. In a randomized controlled trial, bariatric surgeries resulted in decreased CSF pressures and increased weight loss compared with a community weight management intervention (eg, Weight Watchers).[13] However, there were no significant differences in visual function (ie, perimetric mean deviation or papilledema grade), headache scores, or IIH symptoms between the two groups. In addition, nearly 40% of patients in the bariatric surgery arm suffered an adverse event during the 24 month follow-up period, which included hospitalization for IIH exacerbation in 18% of bariatric surgery patients during the first postoperative year. Only one patient (3%) in the bariatic surgery arm underwent reoperation for a bowel obstruction complication; none of the bariatric surgery patients underwent subsequent CSF diversion. In earlier series, complication rates of bariatric surgery were as high as 55%.[11]

In comparison to the aforementioned surgeries, venous sinus stenting (VSS) has a relatively favorable complication rate of 6.6%, with a major complication rate (which includes subdural hemorrhage, sinus or stent thrombosis, and retroperitoneal hemorrhage) of 2.3%.[14 15] Relapse rates after VSS, however, can vary between 10–26%.[16 17] In spite of this, because of the relatively low complication rate, VSS offers a favorable risk-to-benefit ratio compared with optic nerve sheath fenestration, CSF diversion, or bariatric surgery for medically refractory cases of IIH with worsening papilledema and/or vision loss (figure 1).

Apart from IIH, other causes of turbulent flow in the transverse or sigmoid sinus, emissary veins, condylar veins, or internal jugular vein can cause PT.[18–20] Various endovascular treatment strategies have been described to address these abnormalities (online supplemental table 1) with resolution of symptoms reported in most patients; however, these data are limited to case reports and small series and therefore strong conclusions are difficult to make in light of publication bias. These venous causes of PT can be separated into abnormalities of the dural venous sinuses, the jugular vein, or the emissary/condylar veins.

Dural venous sinus abnormalities

Stenosis of the transverse or sigmoid sinus is defined by a transstenotic pressure gradient and can be found without signs or symptoms of elevated intracranial pressure. Stenosis at the proximal transverse/sigmoid sinus junction is the most common location, and can be caused by chronic sinus thrombosis or arachnoid granulations. The stenosis causes altered hemodynamics and turbulence that reverberates through the temporal bone to auditory structures.[21] Venous sinus stenting has been used to alleviate symptoms in small series and case reports with acceptable morbidity.[22]

Sigmoid sinus wall abnormalities that can cause PT include sigmoid sinus diverticula and sigmoid plate dehiscence or thinning. Coil embolization of sigmoid sinus diverticula is generally well-tolerated and leads to resolution of symptoms in most small series (online supplemental table 1). A case of sigmoid sinus diverticulum is presented in figure 2. For cases of sigmoid sinus diverticula, we strongly suggest evaluating for IIH as a potential cause of the sigmoid sinus diverticula. For cases in which sigmoid sinus diverticula coexist with IIH, treatment of the IIH with VSS can cure PT, while isolated coil embolization of the diverticula without treatment of the underlying IIH can lead to symptom recurrence. Sigmoid sinus cortical plate dehiscence has been treated with surgical reconstruction of the sinus wall with resolution of symptoms in 74% of a small retrospective series of patients. Complications from sigmoid sinus resurfacing, including CSF leak or sinus thrombosis, are reported in up to 24% of patients, with major complications needing pharmacologic or surgical interventions reported in 6% of patients.[23 24] However, comparison with endovascular techniques such as VSS

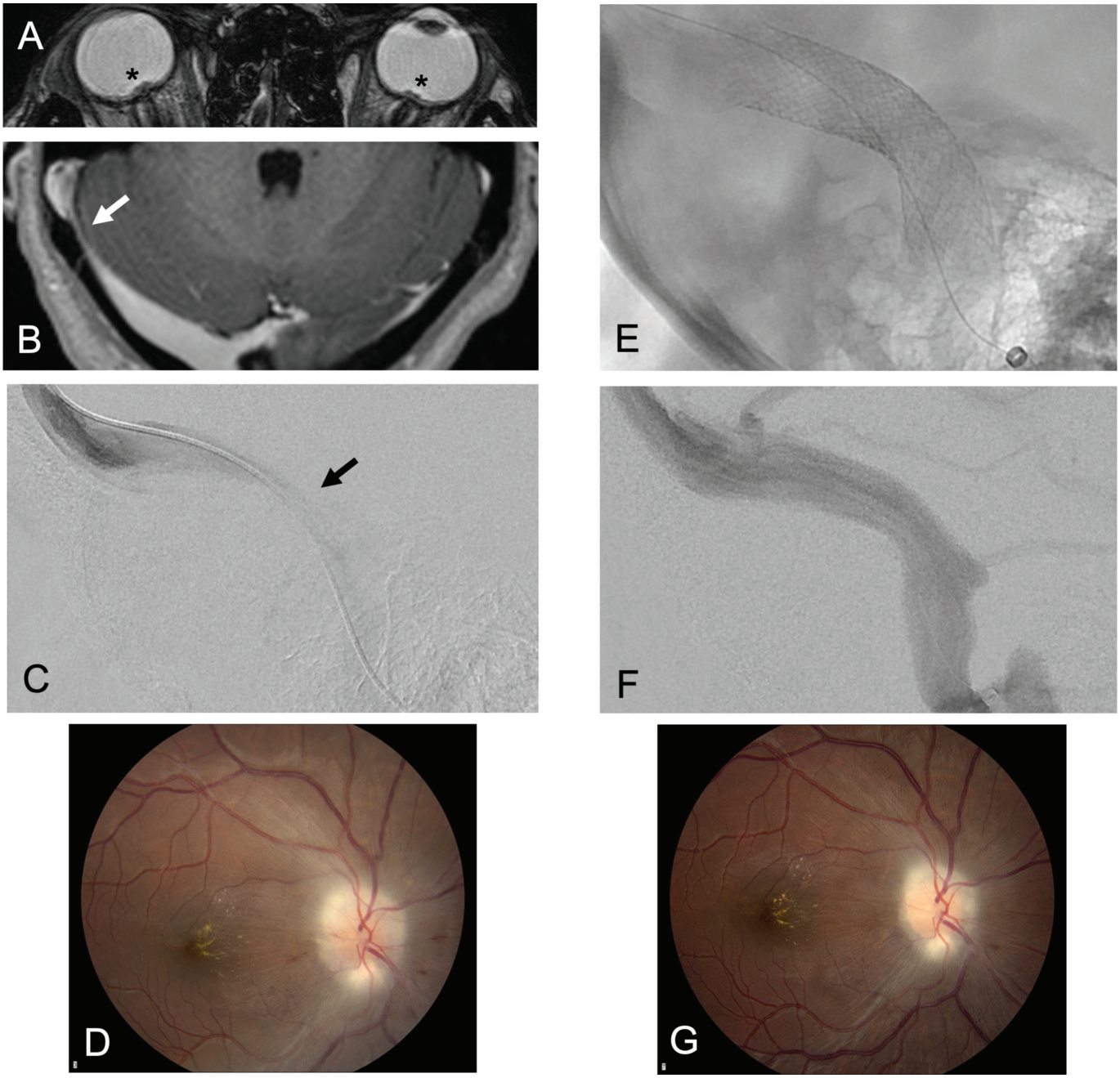

Figure 1 Idiopathic intracranial hypertension. A young woman presented with right pulse-synchronous pulsatile tinnitus, worse when laying down, exacerbated by right neck compression, with positional headaches and vision changes. (A) Axial balanced steady-state-free-precession (bSSFP; FIESTA) MRI demonstrates optic disc protrusion (asterisk). (B) Axial T1-weighted contrast-enhanced gradient-echo (FSPGR) demonstrates right transverse-sigmoid sinus junction stenosis (arrow). Lumbar puncture opening pressure was >60 cm of water and she had decreased visual acuity on the right (20/100). Venous manometry gradient was 18 mm Hg. (C) Right transverse sinus venogram in lateral projection demonstrates stenosis (arrow). (D) Fundoscopy demonstrates Frisen grade 2 papilledema. (E) Venous sinus stenting of the right transverse-sigmoid sinus in lateral projection. (F) Cerebral angiogram in venous phase and lateral projection demonstrates no residual stenosis of the right transverse-sigmoid sinus. One week after stenting, visual acuity improved to 20/25 and (G) fundoscopy demonstrates improved papilledema to Frisen grade 1. At 3 months, the lumbar puncture opening pressure was 11 cm of water and at 5 months, visual acuity had improved to 20/20 with no residual papilledema.

or coil embolization has not yet been performed.[18 25–28] Of note, if the sigmoid sinus dehiscence is due to underlying IIH, resurfacing does not address the underlying disease process, while VSS can be curative.

Emissary vein anomalies

Emissary veins connect the intracranial and extracranial venous systems and are characterized by a thin wall and a valveless structure. Three emissary veins are most commonly implicated in PT: the posterior condylar vein, the mastoid emissary vein, and the petrosquamosal vein. Turbulent flow through these emissary veins can cause PT, particularly in the setting of intracranial venous system obstruction or an arteriovenous shunt.[29 30] In the absence of an arteriovenous shunt, determining whether emissary vein flow contributes to a patient's PT can be challenging, and we find balloon test occlusion to be very helpful in these

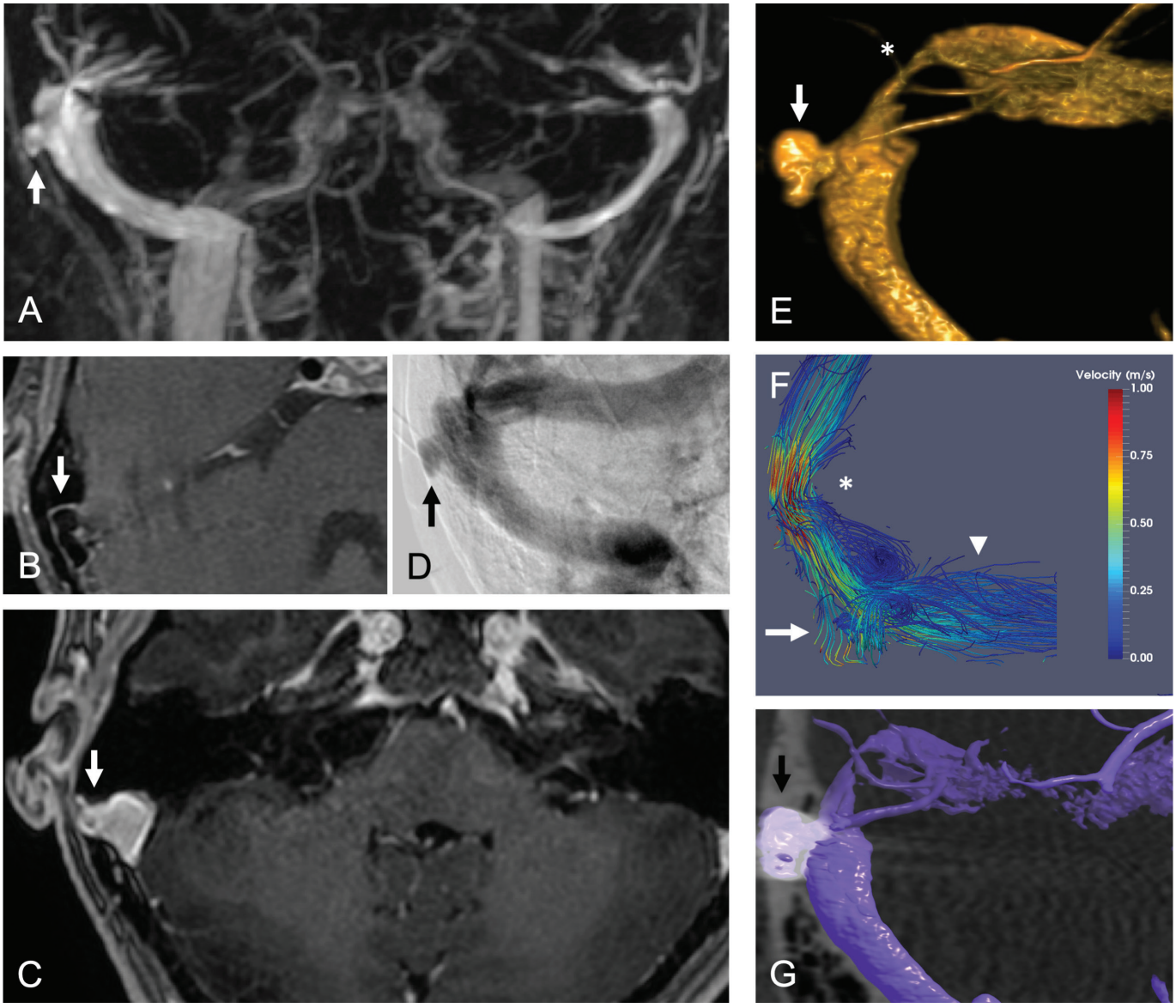

Figure 2 Sigmoid sinus diverticulum. A middle-aged woman presented with right-sided pulsatile tinnitus that was exacerbated by left neck compression and improved with right neck compression. Her lumbar puncture opening pressure was normal. (A) Coronal maximum intensity projection (MIP) reformat of time-resolved contrast-enhanced (TRICKS) MRA demonstrates right sigmoid sinus diverticulum (arrow). (B) Axial T1-weighted contrast-enhanced spin-echo (CUBE) MRI demonstrates signal void (arrow) due to flow in right sigmoid sinus diverticulum. (C) Axial T1-weighted contrast-enhanced gradient-echo (FSPGR) MRI demonstrates enhancement (arrow) of diverticulum contiguous with the right sigmoid sinus. (D) Left internal carotid arteriogram in venous phase and Townes projection demonstrates right sigmoid sinus diverticulum (arrow). (E) Volume rendering of 3D rotational cone beam CT in venous phase demonstrates sigmoid sinus diverticulum (arrow) and upstream venous stenosis (asterisk). (F) 4D flow MRI fluid dynamic modeling with streamlines demonstrates elevated velocity at the upstream venous sinus stenosis (asterisk), flow into the sigmoid sinus diverticulum (arrow), and vortex in the downstream sigmoid sinus (arrowhead). Reproduced with permission from Amans *et al*.[28] (G) Coil embolization of sigmoid sinus diverticulum (arrow) resulted in resolution of symptoms and abnormal 4D flow characteristics. 3D, three-dimensional; 4D, four-dimensional; MRA, MR angiography.

circumstances. Coil embolization of these emissary veins to treat PT has been described in small case series with good results and no morbidity.[20 31 32]

Jugular vein anomalies

Jugular vein anomalies are present in up to 10–15% of normal subjects and include high-riding jugular bulb and jugular dehiscence/diverticulum. When the jugular bulb lies abnormally at the level of the hypotympanum or more superiorly, and the jugular plate is thin, turbulent flow adjacent to the mastoid air cells and cochlea can produce venous PT. Stenosis of the internal jugular vein, due to thrombosis or compression by the styloid process, can exacerbate symptoms, particularly when the contralateral internal jugular vein is atretric. Surgical treatment such as jugular vein ligation or lowering of the jugular bulb is associated with high complication and low efficacy rates.[33 34] Endovascular treatment, such as coiling, stent-assisted coiling, or even WEB (Woven EndoBridge) embolization, have been reported as effective in case reports and small case series (online supplemental table 1). However, jugular vein stenting is generally inadvisable because of risk of stent migration, stent thrombosis, or lower cranial neuropathy.

Arterial

Arterial causes of PT include carotid artery stenosis, vertebral or carotid dissection, fibromuscular dysplasia, aneurysm, aberrant internal carotid artery, and dural arteriovenous fistula (dAVF). Treatment of the arterial causes of PT usually result in resolution of symptoms, but evidence is limited to small case series and reports (online supplemental table 1). Often, indications for treatment of the arterial causes of PT include not only the disabling symptom itself, but prevention of ischemic or hemorrhagic stroke, which form a stronger evidence basis.

A comprehensive discussion of myriad dAVFs and their preferred treatment method are beyond the scope of this review. However, some general principles regarding management of dAVF should guide treatment. First, the primary clinical goal for dAVF treatment remains reduction of the risk of future hemorrhage. Therefore, resolving cortical venous reflux takes precedence over curing PT. For low-risk dAVF (ie, without cortical venous reflux), a detailed discussion with the patient is needed to ascertain the level of disability related to PT (for example, using the Tinnitus Handicap Inventory[35]), which then guides discussion of the risks of any treatment offered to reduce that disability. If the dAVF is low-risk and symptoms are tolerable, conservative management is certainly a reasonable strategy (figure 3). Some patients may be concerned about the risk of a low-risk dAVF progressing to a higher-risk dAVF. While this is quite rare, non-invasive imaging is currently unable to reliably detect high-risk dAVF features, particularly when subtle. As such, conservative management requires detailed patient counseling regarding symptomatology. Specifically, resolution of PT in a dAVF patient may indicate disease progression rather than



Figure 3 Suggested algorithm for the treatment approach to a patient with a suspected vascular cause of pulsatile tinnitus. dAVF, dural arteriovenous fistula; FMD, fibromuscular dysplasia; IIH, idiopathic intracranial hypertension; PT, pulsatile tinnitus; VSS, venous sinus stent; .

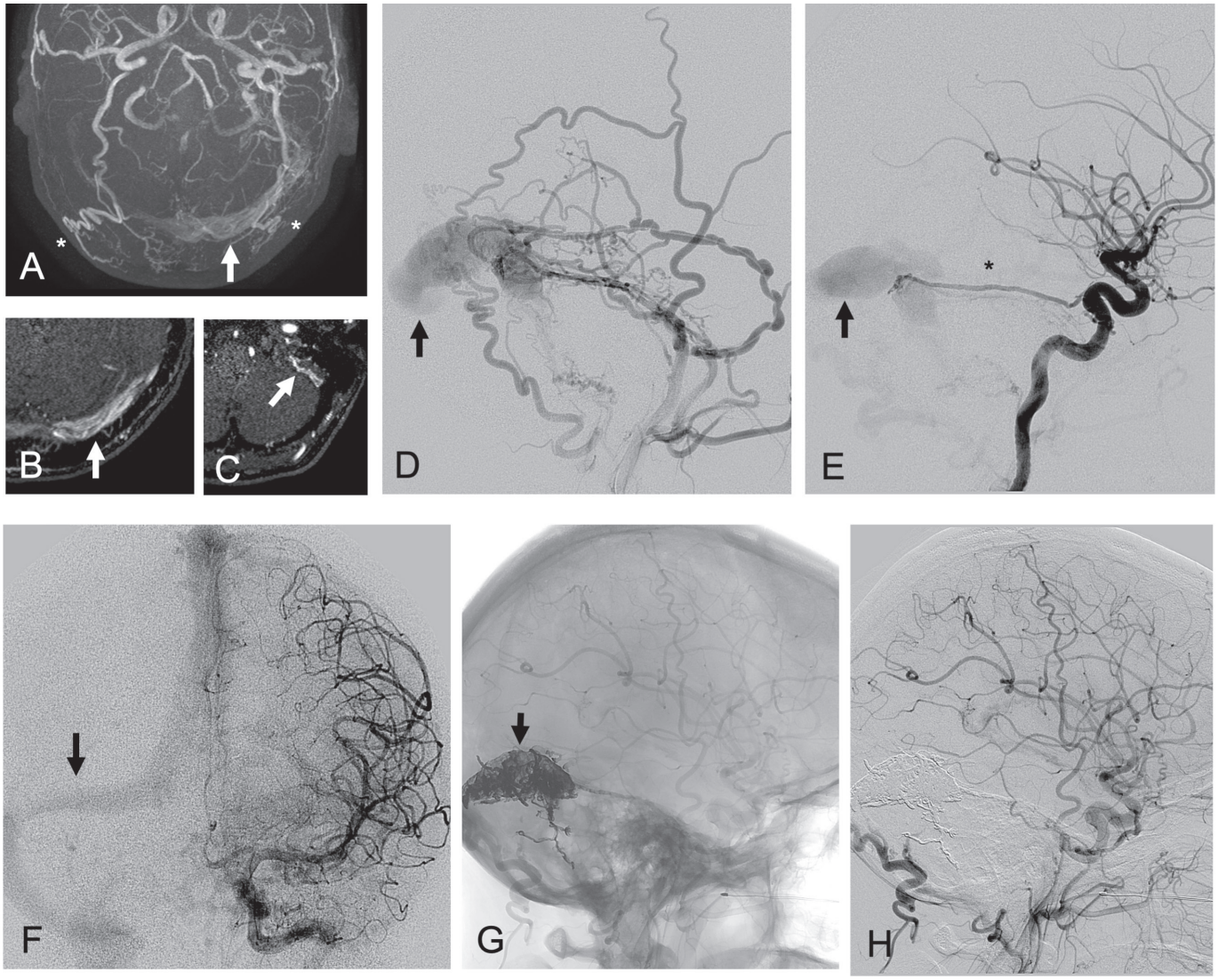

Figure 4 Left transverse-sigmoid sinus dural arteriovenous fistula. A middle-aged woman presented with left pulsatile tinnitus that resolved 1 week previously, and has now developed headache, nausea, and incoordination. (A) Axial maximum intensity projection (MIP) of time-of-flight (TOF) MRA demonstrates enlarged occipital arteries (asterisks) and flow-related enhancement in the left transverse (arrow) and sigmoid sinuses. (B) Axial TOF MRA demonstrates flow-related enhancement in the left transverse sinus (arrow) and enlarged bilateral occipital arteries. (C) Axial TOF MRA demonstrates flow-related enhancement in dural arteries of the left sigmoid sinus wall. (D) Left external carotid arteriogram in lateral projection demonstrates arteriovenous shunting into the left transverse sinus by enlarged occipital artery, middle meningeal artery, superficial temporal artery, and ascending pharyngeal artery branches. (E) Left internal carotid arteriogram in lateral projection demonstrates arteriovenous shunting into the left transverse sinus (arrow) by an enlarged lateral tentorial branch (asterisk) of the meningohypophyseal trunk. (F) Venous phase of left internal carotid arteriogram in frontal projection shows right-dominant venous system (arrow=right transverse sinus). Ethylene vinyl alcohol copolymer embolization via a left occipital artery transmastoid branch with intentional occlusion of the sinus (G) resulted in angiographic resolution of arteriovenous shunting on (H) post-embolization left common carotid arteriogram in lateral projection. MRA, MR angiography.

resolution—for instance, if the jugular vein has occluded and venous drainage is diverted retrograde into cortical veins.[36 37] If dAVF treatment is undertaken, endovascular treatment is typically first-line therapy, as determined by cervicocerebral angiography (figure 4). Transvenous embolization is our preferred approach for low-risk marginal sinus and indirect carotid-cavernous dAVFs due to external carotid artery supply to cranial nerves and extensive extracranial-to-intracranial artery anastomoses, as previously detailed.[38 39] When contemplating the risk of transvenous embolization, we always consider risk of intracranial hemorrhage, venous infarction, or intracranial venous hypertension, based on the venous drainage pattern. For example, if cortical veins are draining into the recipient venous pouch, transvenous embolization should not be performed.[40]

Non-operative treatment of tinnitus

Our diagnostic approach to a PT patient includes a complete history, physical examination, and imaging evaluation. If, after excluding all 'dangerous' causes of PT and, despite a thorough evaluation, a cause for the patient's tinnitus cannot be found, or the underlying cause cannot be safely or effectively treated surgically or medically, behavioral treatments can be therapeutic. Effective behavioral treatments for tinnitus include tinnitus retraining therapy (TRT), cognitive behavioral therapy (CBT),

acceptance and commitment therapy, and mindfulness-based stress reduction,[41–44] with the strongest evidence supporting use of TRT and CBT. However, each treatment provides patients with coping skills that allow the tinnitus to recede into the background so that patients can continue with their lives. TRT focuses on sound habituation, while CBT focuses on dysfunctional beliefs about tinnitus and associated compensation behaviors. Specifically, in a randomized controlled clinical trial of 492 patients in the Netherlands, stepped-care tinnitus management (combining elements of tinnitus retraining therapy within a CBT framework) was more effective than standard care in improving tinnitus severity, impairment, health-related quality of life, negative emotional states, tinnitus-related catastrophic thinking, and tinnitus-related fear for 4 months after treatment ended. Sound generating devices, as an isolated treatment approach, have not been proven as effective. Therefore, an integrated treatment approach which provides sustained psychoeducation and audiologic expertise should be provided rather than fragmented care for tinnitus. Transcranial magnetic stimulation may also have a role in tinnitus suppression, but additional trials are needed to demonstrate long-term reproducible efficacy.[45 46]

FUTURE PERSPECTIVE

Multiple clinical trials for patients with medically refractory IIH are underway to assess the efficacy of VSS using a variety of different stents with or without comparison to CSF diversion. New stent designs may be needed to reduce the risk of treatment failure after VSS. Endovascular treatment of other venous causes of PT are limited to case reports and series, and it is unlikely that any one center will be able to report a significantly larger case series because of the rarity of these cases and numerous potential anatomic causes. Further study of the other venous causes of PT is also limited by a paucity of objective assessment methods. We have provided our UCSF Cerebral Venous Disorder Testing form as online supplemental material, which guides our assessment of venous causes of PT currently. Development of patient-specific three-dimensional-printed flow models that mimic a patient's hemodynamic conditions also allows physicians to better narrow down the specific causes of a patient's PT, and simulate treatment before the intervention.[47] In the future, phase-contrast MRI (ie, four-dimensional flow), fluid dynamic modeling with sound simulation, and intravascular sound recordings will likely play a larger role in disease assessment, particularly as part of clinical trials. Arterial causes of PT, such as carotid stenosis and dAVF, can bear a risk of stroke in addition to causing PT, and therefore may warrant treatment for multiple reasons. A suggested algorithm to approach treatment of a patient with a suspected vascular cause of PT is outlined in figure 3.

CONCLUSION

PT can be a maddening symptom with debilitating psychiatric impact, and has myriad causes, some of which pose significant risk of ischemic or hemorrhagic stroke or possible blindness. Organizing the causes of PT into structural, metabolic, and vascular groups facilitates appropriate testing, referral, and treatment.[7] After a complete evaluation, if a vascular cause has been established, one must carefully consider the disease's natural history, degree of patient debilitation, goals and risks of treatment, and rationale for the treatment choice. Unfortunately, for many vascular causes of PT, evidence for treatment is mostly limited to case reports and series, with the notable exception of randomized controlled clinical trials for IIH. Clinical trials are needed to establish the role of VSS for IIH.

Contributors KHN wrote the manuscript and supervised the work. MD assisted with the literature review. FH and KM provided critical feedback. MRA provided critical feedback and supervised the work.

Funding This study was funded by National Institute of Biomedical Imaging and Bioengineering (5R01EB012031), National Institute of Neurological Disorders and Stroke (U54 NS065705), National Heart, Lung, and Blood Institute (R56HL149124), Congressionally Directed Medical Research Programs (W81XWH-21-1-0753).

Competing interests None declared.

Patient consent for publication Not applicable.

Ethics approval This study does not involve human participants.

Provenance and peer review Commissioned; externally peer reviewed.

ORCID iDs
Kazim H Narsinh http://orcid.org/0000-0002-2019-5461
Ferdinand Hui http://orcid.org/0000-0003-3759-7886
Matthew R Amans http://orcid.org/0000-0002-8209-0534

REFERENCES

1 Heller AJ. Classification and epidemiology of tinnitus. *Otolaryngol Clin North Am* 2003;36:239–48.
2 Bhatt JM, Lin HW, Bhattacharyya N. Prevalence, severity, exposures, and treatment patterns of tinnitus in the United States. *JAMA Otolaryngol Head Neck Surg* 2016;142:959–65.
3 Nondahl DM, Cruickshanks KJ, Wiley TL, *et al*. Prevalence and 5-year incidence of tinnitus among older adults: the epidemiology of hearing loss study. *J Am Acad Audiol* 2002;13:323–31.
4 Adams PF, Hendershot GE, Marano MA, *et al*. Current estimates from the National Health Interview Survey, 1996. *Vital Health Stat 10* 1999;10:1–203.
5 Salazar JW, Meisel K, Smith ER, *et al*. Depression in patients with tinnitus: a systematic review. *Otolaryngol–Head Neck Surg* 2019;161:28–35.
6 Cummins DD, Caton MT, Shah V, *et al*. MRI and MR angiography evaluation of pulsatile tinnitus: a focused, physiology-based protocol. *J Neuroimaging*
7 Narsinh KH, Hui F, Saloner D. Diagnostic approach to pulsatile tinnitus: a review. *JAMA Otolaryngol - Head Neck Surg* 2022.
8 Wall M, McDermott MP, NORDIC Idiopathic Intracranial Hypertension Study Group Writing Committee,. *et al*. Effect of acetazolamide on visual function in patients with idiopathic intracranial hypertension and mild visual loss: the idiopathic intracranial hypertension treatment trial. *JAMA* 2014;311:1641–51.
9 Fonseca PL, Rigamonti D, Miller NR, *et al*. Visual outcomes of surgical intervention for pseudotumour cerebri: optic nerve sheath fenestration versus cerebrospinal fluid diversion. *Br J Ophthalmol* 2014;98:1360–3.
10 Plotnik JL, Kosmorsky GS. Operative complications of optic nerve sheath decompression. *Ophthalmology* 1993;100:683–90.
11 Kalyvas AV, Hughes M, Koutsarnakis C, *et al*. Efficacy, complications and cost of surgical interventions for idiopathic intracranial hypertension: a systematic review of the literature. *Acta Neurochir* 2017;159:33–49.
12 Satti SR, Leishangthem L, Chaudry MI. Meta-analysis of CSF diversion procedures and dural venous sinus stenting in the setting of medically refractory idiopathic intracranial hypertension. *AJNR Am J Neuroradiol* 2015;36:1899–904.
13 Mollan SP, Mitchell JL, Ottridge RS, *et al*. Effectiveness of bariatric surgery vs community weight management intervention for the treatment of idiopathic intracranial hypertension: a randomized clinical trial. *JAMA Neurol* 2021;78:678.
14 Kalyvas A, Neromyliotis E, Koutsarnakis C, *et al*. A systematic review of surgical treatments of idiopathic intracranial hypertension (IIH). *Neurosurg Rev* 2021;44:773–92.
15 Townsend RK, Jost A, Amans MR, *et al*. Major complications of dural venous sinus stenting for idiopathic intracranial hypertension: case series and management considerations. *J Neurointerv Surg*;45:neurintsurg-2021-017361.
16 Kahan J, Sundararajan S, Brown K, *et al*. Predicting the need for retreatment in venous sinus stenting for idiopathic intracranial hypertension. *J Neurointerv Surg* 2021;13:574–9.
17 Garner RM, Aldridge JB, Wolfe SQ, *et al*. Quality of life, need for retreatment, and the re-equilibration phenomenon after venous sinus stenting for idiopathic intracranial hypertension. *J Neurointerv Surg* 2021;13:79–85.
18 Amans MR, Haraldsson H, Kao E, *et al*. MR venous flow in sigmoid sinus diverticulum. *AJNR Am J Neuroradiol* 2018;39:2108–13.

19 Kao E, Kefayati S, Amans MR, *et al*. Flow patterns in the jugular veins of pulsatile tinnitus patients. *J Biomech* 2017;52:61–7.
20 Alexander MD, Meisel KM, Halbach VV, *et al*. Enlarged condylar veins as a source of pulsatile tinnitus: angiographic features and confirmation with venous balloon test occlusion. *Neurographics* 2017;7:363–8.
21 Pereira VM, Cancelliere NM, Najafi M, *et al*. Torrents of torment: turbulence as a mechanism of pulsatile tinnitus secondary to venous stenosis revealed by high-fidelity computational fluid dynamics. *J Neurointerv Surg* 2021;13:732–7.
22 Lenck S, Labeyrie M-A, Vallee F, *et al*. Stent placement for disabling pulsatile tinnitus caused by a lateral sinus stenosis: a retrospective study. *Oper Neurosurg* 2017;13:560–5.
23 Liu GS, Boursiquot BC, Blevins NH, *et al*. Systematic review of temporal bone-resurfacing techniques for pulsatile tinnitus associated with vascular wall anomalies. *Otolaryngol–Head Neck Surg* 2019;160:749–61.
24 Raghavan P, Serulle Y, Gandhi D, *et al*. Postoperative imaging findings following sigmoid sinus wall reconstruction for pulse synchronous tinnitus. *AJNR Am J Neuroradiol* 2016;37:136–42.
25 Eisenman DJ, Raghavan P, Hertzano R, *et al*. Evaluation and treatment of pulsatile tinnitus associated with sigmoid sinus wall anomalies. *Laryngoscope* 2018;128:S1–13.
26 Houdart E, Chapot R, Merland JJ. Aneurysm of a dural sigmoid sinus: a novel vascular cause of pulsatile tinnitus. *Ann Neurol* 2000;48:669–71.
27 Lenck S, Mosimann PJ, Labeyrie M-A, *et al*. Pulsatile tinnitus caused by an aneurysm of the transverse-sigmoid sinus: a new case report and review of literature. *J Neuroradiol J Neuroradiol* 2012;39:276–9.
28 Amans MR, Stout C, Dowd CF. Resolution of pulsatile tinnitus after coil embolization of sigmoid sinus diverticulum. *Austin J Cerebrovasc Dis* 2014;1.
29 Hellstern V, Aguilar-Pérez M, Schob S, *et al*. Endovascular treatment of dural arteriovenous fistulas of the anterior or posterior condylar vein. *Clin Neuroradiol* 2019;29:341–9.
30 Brinjikji W, Lanzino G, Cloft HJ. Transvenous embolization of a posterior condylar canal fistula causing pulsatile tinnitus. *J Neurointerv Surg* 2021;13:680.
31 Eliezer M, Freitas RK, Fantoni M, *et al*. Selective embolization of the mastoid emissary vein for pulsatile tinnitus treatment: when is it indicated? *J Neurointerv Surg* 2020;12:999–1001.
32 Abdalkader M, Ma A, Cohen M, *et al*. Endovascular coiling of large mastoid emissary vein causing pulsatile tinnitus. *Interv Neuroradiol* 2020;26:821–5.
33 Rolffs J, Schmelzle R. Serious cerebral complications following unilateral ligation of the internal jugular vein. review of the literature and a case report. *J Maxillofac Surg* 1977;5:118–23.
34 Couloigner V, Grayeli AB, Bouccara D, *et al*. Surgical treatment of the high jugular bulb in patients with Ménière's disease and pulsatile tinnitus. *Eur Arch Otorhinolaryngol* 1999;256:224–9.
35 Newman CW, Jacobson GP, Spitzer JB. Development of the tinnitus handicap inventory. *Arch Otolaryngol Head Neck Surg* 1996;122:143–8.
36 Cognard C, Houdart E, Casasco A, *et al*. Long-term changes in intracranial dural arteriovenous fistulae leading to worsening in the type of venous drainage. *Neuroradiology* 1997;39:59–66.
37 Satomi J, van Dijk JMC, Terbrugge KG, *et al*. Benign cranial dural arteriovenous fistulas: outcome of conservative management based on the natural history of the lesion. *J Neurosurg* 2002;97:767–70.
38 Alexander MD, Halbach VV, Hallam DK, *et al*. Long-term outcomes of endovascular treatment of indirect carotid cavernous fistulae: superior efficacy, safety, and durability of transvenous coiling over other techniques. *Neurosurgery* 2019;85:E94–100.
39 Caton MT, Narsinh KH, Baker A, *et al*. Endovascular treatment strategy, technique, and outcomes for dural arteriovenous fistulas of the marginal sinus region. *J Neurointerv Surg* 2022;14:155–9.
40 Halbach VV, Higashida RT, Hieshima GB. Transvenous embolization of dural fistulas involving the cavernous sinus. *Am J Neuroradiol* 1989;10:377–83.
41 Cima RFF, Maes IH, Joore MA, *et al*. Specialised treatment based on cognitive behaviour therapy versus usual care for tinnitus: a randomised controlled trial. *Lancet* 2012;379:1951–9.
42 Hesser H, Weise C, Westin VZ, *et al*. A systematic review and meta-analysis of randomized controlled trials of cognitive–behavioral therapy for tinnitus distress. *Clin Psychol Rev* 2011;31:545–53.
43 Westin VZ, Schulin M, Hesser H, *et al*. Acceptance and commitment therapy versus tinnitus retraining therapy in the treatment of tinnitus: a randomised controlled trial. *Behav Res Ther* 2011;49:737–47.
44 Philippot P, Nef F, Clauw L, *et al*. A randomized controlled trial of mindfulness-based cognitive therapy for treating tinnitus. *Clin Psychol Psychother* 2012;19:411–9.
45 Liang Z, Yang H, Cheng G, *et al*. Repetitive transcranial magnetic stimulation on chronic tinnitus: a systematic review and meta-analysis. *BMC Psychiatry* 2020;20:547.
46 Meng Z, Liu S, Zheng Y, *et al*. Repetitive transcranial magnetic stimulation for tinnitus. *Cochrane Database Syst Rev* 2011:CD007946.
47 Valluru K, Parkhill J, Gautam A, *et al*. Sound measurement in patient-specific 3D printed bench models of venous pulsatile tinnitus. *Otol Neurotol* 2020;41:e7–14.

Supplemental Figure 1. PRISMA flow diagram of literature search.

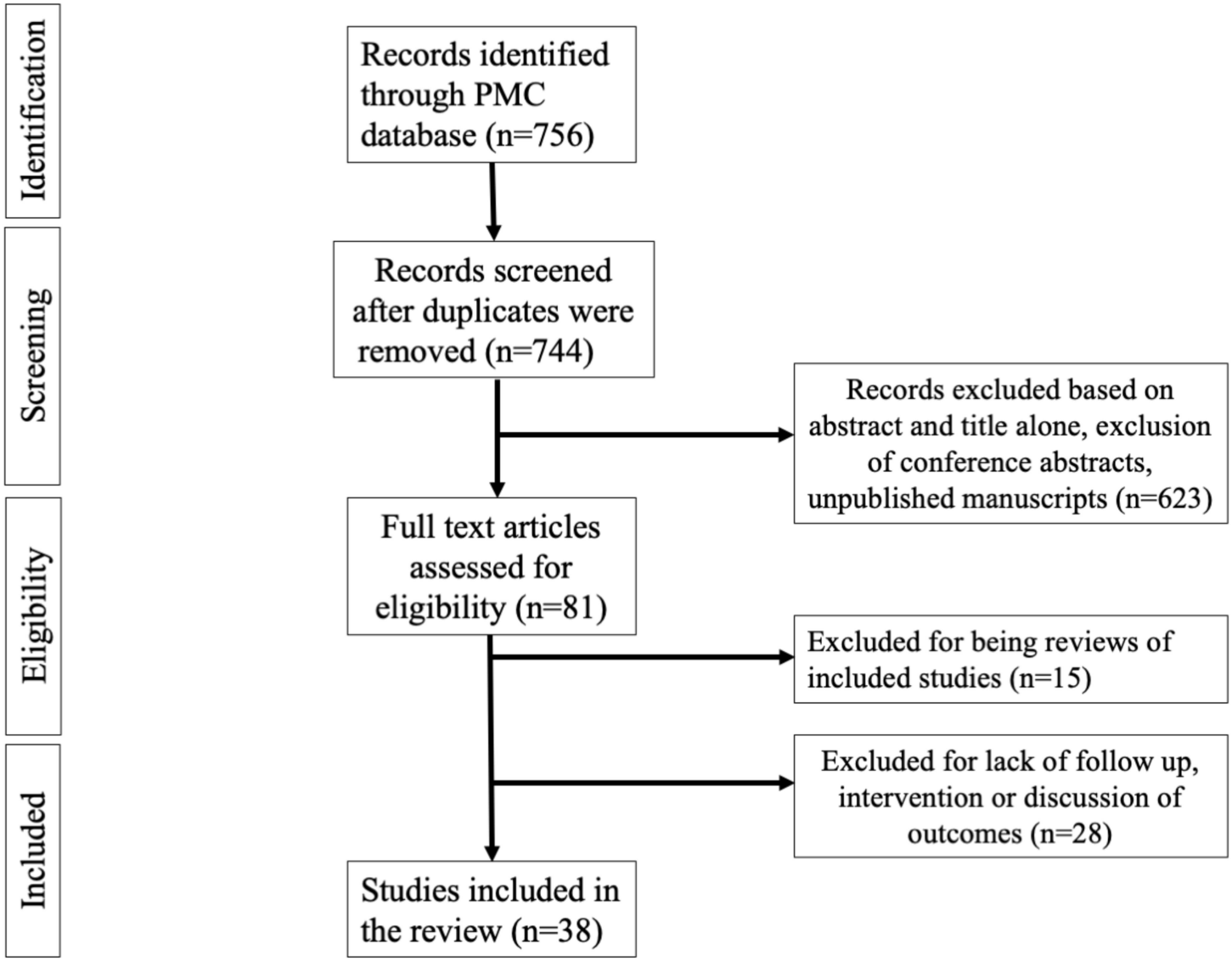

Supplemental Table 1. Literature review of treatment of pulsatile tinnitus' causes. The myriad causes of pulsatile tinnitus have been treated by different modalities with varying levels of success and duration of follow-up. Prospective randomized trials are needed to better define appropriate treatment algorithms.

	Cause	Management	Intervention	Study Size (n =)	Study Design	Results Technical Success (%) Clinical Success (%, follow up period) Complication rate (% major complication of death/stroke, follow up period)	Limitations	Reference
Vascular: Arterial	Atherosclerotic carotid artery disease	Surgery	Carotid endarterectomy	14	Case series	100% technical success 71% reported symptom relief at 6 week follow up 0% stroke/death rate	Retrospective study	Kirby-Bott and Gibbs 2004 [1]
	Atherosclerotic carotid artery disease	Endovascular Treatment	Carotid artery angioplasty and stenting	2	Case series	100% technical success 100% clinical success 0% complications	Stenotic lesions< 15 mm, small sample size	Inh et al 2013 [2]
	Atherosclerotic carotid artery disease	Endovascular treatment	Simultaneous extracranial endarterectomy and primary intrapetrous stenting	1	Case report	100% technical success 100% clinical success 0% complication rate	No follow up	Emery et al 1998 [3]
	Atherosclerotic carotid artery disease	Endovascular treatment	Simultaneous extracranial endarterectomy and primary intrapetrous stenting	1	Case report	100% technical success 100% clinical success, asymptomatic for 19 months 0% complication	Small sample size	Hartung et al 2004 [4]
	Intracranial arterial aneurysms	Endovascular Treatment	Coil embolization	1	Case report	100% technical success 100% clinical success for 4 years 0% complications	Sample size	Kim et al 2018 [5]

	Intracranial arterial aneurysm	Endovascular treatment	Coil embolization	1	Case report	100% technical success 100% clinical success up to 6 months 0% complication	Sample size	Kim et al 2012 [6]
	Intracranial arterial aneurysm	Endovascular treatment	Balloon embolization	1	Case report	100% technical success 100% clinical successs for 6 months 0% serious complication, ear pain after treatment	Sample size	Willinsky et al 1987 [7]
	Arteriovenous malformations Facial AVM	Endovascular Treatment	Coil embolization of superficial temporal artery	1	Case report	100% technical success 100% clinical success for 8 years 0% complication	Sample size	Chen et al 2018
	External ear AVM	Endovascular treatment	Preoperative embolization with surgical excision	1	Case report	100% technical success 100% clinical success 0% complication	Sample size Indirect symptom assessment at 2 year period	Woo et al 2008 [9]
	Parotid gland AVM	Surgery	Surgical ligation with partial resection of the left STA; parotidectomy	1	Case report	100% technical success 0% clinical success, persistent tinnitus after first surgery, then 100% clinical success with second 0% complication	Sample size, multiple surgeries	Selleck et al 2020 [10]
	Auricular AVM	Endovascular treatment + surgery	Pre-operative transarterial embolization with TFCA, glue and subsequent total mass exicision	1	Case report	100% technical success 100% clinical success 100% complication – with ischemic skin necrosis	Sample size	Kim et al 2017 [11]
				1	Case report		Sample size	Aslan et al 2017

	External auditory canal/temporal bone AVM	Endovascular treatment + surgery	PVA embolization and subsequent surgical excision			<100% clinical success, with subsequent 100% technical success after surgery, 100% clinical success for up to 3 years, 0% complications		[12]
	Transverse sigmoid sinus dural AVM	Endovascular treatment	Coiling with dural venous occlusions	1	Case report	100% technical success 100% clinical success, 18 mo 0% complications	Sample size	de Paula Lucas et al 2010 [13]
	Marginal sinus fistulas	Endovascular treatment (88%), surgical (4%), combined (8%)	Transvenous (76%), transarterial (14%), combined (10%)	29	Case series	96% technical success 75% resolution of symptoms, 25% partial improvement in symptoms, 12% complications	Various treatment modalities	Caton et al 2021 [14]
	Condylar vein fistulas (anterior + posterior)	Endovascular treatment	Transvenous embolization	6	Case series	100% technical success 100% clinical success, 2 y 0% complications, 2 y	Sample size	Hellstern et al 2019 [15]
	Posterior condylar canal fistula	Endovascular treatment	Transvenous embolization	1	Case report	100% technical success 100% clinical success 0% complications	Sample size	Brinjikji et al 2020 [16]
	Traumatic CCF	Endovascular treatment	Transvenous and transarterial coil embolization	1	Case report	100% technical success 100% clinical success, 7 weeks 0% complications	Sample size Short follow up	Lerut et al 2007 [17]
	Persistent primitive trigeminal artery aneurysm/CCF	Endovascular treatment	Coil and onyx embolization	1	Case report	100% technical success 100% clinical success, 3 mo 0% complications, 3 mo	Sample size Short follow up	Fan et al 2019 [18]
	CCF/Internal Carotid Artery Aneurysm	Surgery + Endovascular treatment	Embolization of cavernous sinus and fistula with superficial temporal artery + MCA anastomosis with ICA occlusion	1	Case report	100% technical success 100% clinical success, 2 months 0% complication	Sample size	Nakahara et al 2019[19]

	Rete mirabile	Conservative management	Conservative management	1	Case report	N/A technical success 0% clinical success, 6 mo 0% complications	Lack of clinical success	Mondel et al 2017[20]
	Aberrant internal carotid artery	Surgery	Endoaural approach surgical myrongoplasty	1	Case report	100% technical success 100% clinical success, 1 y follow up 0% complications, 1 y	Sample size	Honkura et al 2014 [21]
	Aberrant internal carotid artery	Surgery	Separation of aberrant ICA from promonotorium tympani and coagulation	1	Case report	100% technical success 100% clinical success, 7 mo 0% complications, 7 mo	Sample size	Song et al 2012 [22]
	Duplicated, aberrant internal carotid artery	Conservative management	Conservative management with regular follow up	1	Case report	N/A technical success 0% clinical success at 1 year N/A complications	Sample size	Anagiotos et al 2019 [23]
	Aberrant internal carotid artery	Surgery	Placement of tragal cartilage over carotid canal	1	Case report	100% technical success 100% clinical success, 3 mo 0% complications, 3 mo	Sample size, no long-term follow up	Hashim et al 2021[24]
	Aneurysm of an aberrant ICA	Endovascular treatment + Surgery	Endovascular internal trapping and common carotid artery to MCA bypass	1	Case report	100% technical success 100% clinical success, 6 months 0% complications	Sample size	Kawamura et al 2017[25]
	Persistent stapedial artery	Surgery	Resection of PSA	1	Case report	100% technical success 100% clinical success, immediate 0% complications, immediate	Lack of long term follow up	Murphy et al 1995 [26]
		Surgery	Stapedotomy	1	Case report	100% technical success 100% clinical success, immediate 0% complications, immediate	Lack of long term follow up	Pirodda et al 1994[27]
Vascular: Venous	Idiopathic intracranial hypertension	Lifestyle modifications Medications	Weight reduction and acetazolamide	165	Multicenter double blind, randomized	N/A technical success Decreased papilledema in azetazolamide + weight reduction group, 6 mo	Resolution of pulsatile tinnitus was	NORDIC Trial 2014 [28]

			versus weight reduction only			0% complications, 6 mo	not a primary outcome	
		Endovascular Treatment	Stenting	154	Systematic review	100% technical success 90% clinical success, variable follow up	Variable follow up; discussion of complications limited	Nicholson et al 2019 [29]
		Surgery	Bariatric surgery	22	Single center retrospective study	100% technical success 95% clinical success, 1 year 0% major complications, 1 years	4 patients lost to follow up, lack of control group	Sugerman et al 1999 [30]
		Endovascular treatment	Venous stenting	15	Single center retrospective analysis	100% technical success 79% clinical success, 14 mo 0% complication	Lack of control group	Fields et al 2013 [31]
		Endovascular treatment	Venous stenting	29	Single center prospective analysis	100% technical success 90% clinical success, 12 mo 0% complications, 12 mo 100% technical success 86% clinical success, 18 mo 0% complications	Lack of control group	Boddu et al 2016 [32]
		Endovascular treatment	Venous stenting	79	Single center retrospective analysis	100% technical success 46% clinical success, 10 mo 0% complications, 10 mo	Pulsatile tinnitus not a primary outcome, primary outcome was elevated opening pressure	Kahan et al 2021 [33]
		Endovascular treatment	Venous stenting	81	Single center prospective analysis	100% technical success Significant decrease in ICP in bariatric surgery group, 12 mo 0% complications, 12 mo	Pre-intervention pulsatile tinnitus scoring was not performed	Garner et al 2021 [34]
		Surgery versus weight management program	Bariatric Surgery (Roux-en-Y gastric bypass),	66	Multicenter Randomized control trial		Pulsatile tinnitus was	Mollan et al 2021 [35]

			weight management			100% technical success 80% clinical success (papilledema), 21 mo 1.5% complications, 21 mo	not a primary outcome; three different types of bariatric surgery were offered to patients; pre-dominantly female study population	
		Various	Optic nerve sheath fenestration	712	Systematic review/metana lysis	100% technical success 70% clinical success, 41 mo 7.6% complications, 41 mo		Satti et al 2015 [36]
			CSF diversion	435		100% technical success 97% clinical success, 23 mo 2.9% complications, 23 mo	Pulsatile tinnitus was not a primary outcome	
			Venous stenting	136		100% technical success 64% clinical success (visual acuity), 42 mo 0% complications, 42 mo		
		Various	Optic nerve sheath fenestration	341	Systemic review/meta-analysis	100% technical success 67% clinical success, 44 mo 0% complications, 44 mo		Kalyvas et al 2017 [37]
			CSF Diversion/Lumb operitoneal shunting	128		100% technical success 69% clinical success, 40 mo 0% complications, 40 mo	Pulsatile tinnitus was not a primary outcome	
			Ventriculoperito neal shunting	26		100% technical success 65% clinical success, 22 mo 4% complications, 22 mo		
			Venous sinus stenting	136				

	Abnormalities of the jugular bulb							
	Jugular bulb diverticulum	Endovascular treatment	Coil embolization	1	Case report	00% technical success 100% clinical success, 10 mo 0% complications, 10 months	Follow up, sample size	Mortimer et al 2015 [38]
	Jugular bulb diverticulum	Endovascular treatment	WEB	1	Case report	100% technical success, 100% clinical success, 2 mo 0% complication	Sample size	Drescher et al 2020 [39]
	High riding jugular bulb with associated sigmoid sinus stenosis and diverticulum	Endovascular treatment	Stent placement across sigmoid sinus with coil embolization of the diverticulum	1	Case report	100% technical success, 100% clinical success, 16 mo 0% complications, 16 mo	Sample size	Trivelato et al 2015 [40]
	Dehiscent high jugular bulb	Surgical	Surgical reconstruction of the middle ear floor	7	Retrospective case series	100% technical success 57% clinical success, 28 mo 0% major complications, 28 mo 14% with increased ICP	Variability in technique in reconstruction of the floor Sample size	El-Begermy et al 2010 [41]
	Dehiscent high jugular bulb	Surgical	Separate the tympanic membrane from the jugular bulb using packed Gelfoam	1	Case report	100% technical success 100% clinical success, 3 y 0% complications, 3 y	Sample size	Shaikh et al 2013 [42]
	Abnormalities of the transverse/sigmoid sinus							
	Dominant sigmoid sinus with focal dehiscence	Surgery	Transmastoid reconstruction of the sigmoid sinus	8	Retrospective analysis	100% technical success 87% clinical success, 9.5 mo 0% complications, increased ICP in 13%	Majority of study participants are female	Kim et al 2016 [43]
	Sigmoid sinus diverticulum	Endovascular treatment	Coil embolization	1	Case Report	100% technical success 100% clinical success, 6 mo 0% complications, 6 mo	Sample size	Zenteno et al 2004 [44]

	Transverse sigmoid sinus diverticulum	Endovascular Treatment	Coil embolization	1	Case Report	100% technical success 100% clinical success, 1 y 0% complication, 1y	Sample size	Gard et al 2009 [45]
	Sigmoid sinus diverticulum		Coil embolization	1	Case Report	100% technical success 100% clinical success, 8 mo 0% complication, 8 mo	Sample size	Houdart et al 2000 [46]
	Sigmoid sinus diverticulum	Endovascular Treatment	Coil embolization	1	Case Report	100% technical success 100% clinical success, 12 mo 100% complication – cerebellar ischemic stroke, 2 mo	Sample size	Sanchez et al 2002 [47]
	Sigmoid sinus diverticulum	Endovascular treatment	Balloon assisted embolization	1	Case Report	100% technical success 90% clinical success, 12 mo 0% complications, 12 mo	Sample size	Mehanna et al 2010 [48]
	Sigmoid sinus diverticulum	Endovascular treatment	Coil embolization	1	Case Report	100% technical success 100% clinical success, 6 mo 0% complications, 6 mo	Sample size, follow up interval	Amans et al 2014 [49]
	Sigmoid sinus diverticulum with sigmoid sinus wall dehiscence	Surgery, conservative management	Sigmoid sinus wall reconstruction or conservative management	28	Retrospective Case Control	100% technical success 68% clinical success in surgery versus 0% clinical success for those with conservative management, 16 mo 0% complications, 16 mo 90% technical success 90% clinical success, 1mo 0% complications, 1 mo	Variability in surgical techniques used, majority of participants are female	Wang et al 2015 [50]
	Sigmoid sinus wall abnormalities with diverticulum	Surgery	Transtemporal sinus wall reconstruction	40	Single center Retrospective	100% technical success 95% clinical success, variable 0% complications, variable	Short interval follow up	Eisenman et al 2018 [51]
	Sigmoid sinus wall anomaly	Surgery	Transmastoid sigmoid sinus	40		100% technical success		Raghavan et al 2016 [52]

			wall reconstruction		Single center retrospective	100% clinical success, 12 mo 0% complications, 12 mo	Follow up period was variable/not discussed for every patient	
	Venous sinus diverticulum at the junction of the transverse and sigmoid sinuses	Endovascular treatment	Coil embolization	2	Case series	100% technical success 93% clinical success, 12 mo 0% complications	Sample size	Shastri et al 2017 [53]
	Lateral sinus stenosis	Endovascular treatment	Venous stenting	14	Case series		Unblinded assessment, 2 patients had IIH	Lenck et al 2017 [54]
	Dilated mastoid emissary vein	Endovascular treatment	Embolization	6	Case series	100% technical success 33% clinical success, 6 mo 0% complications, 6 mo	Sample size, clinically successful only in patients with venous PT (versus neutral PT where pre-operative vascular compression did not change symptoms)	Eliezer et al 2020 [55]
	Dilated mastoid emissary vein	Endovascular treatment	Transvenous embolization of large dilated mastoid emissary vein	1	Case report	100% technical success 100% clinical success, 6 mo 0% complications, 6 mo	Sample size	Abdalkader et al 2021 [56]
	Dilated mastoid emissary vein	Surgery	Surgical clipping of mastoid emissary vein	1	Case report	100% technical success 100% clinical success, 3 y 0% complications, 3 y	Sample size	Kim et al 2021 [57]
Non-vascular - Structural	Glomus tumor	Radiation	Gamma knife	53	Multicenter-retrospective	100% technical success 49% clinical success, 50.5 mo 0% complications, 50.5	Variability in follow up (5-220 mo)	Sheehan et al 2012 [58]
	Glomus tumor	Radiation	Gamma knife	10		100% technical success		

					Single institution retrospective case series	40% clinical success, 27.6 mo 0% complications, 27.6 mo	Sample size, variable decreases in tumor size, variable follow up (mean reported)	Dobberpuhl et al 2016 [59]
	Glomus tumor	Surgery and endovascular treatment	Surgery with preoperative embolization using ethanol	6	Case series	100% technical success 100% clinical success, 21.3 0% complications, 21. 3 mo	Sample size	Devuyst et al 2016 [60]
	Superior semicircular canal dehiscence	Surgery	Plugging + resurfacing via the middle fossa	12	Case series	100% technical success 83% clinical success, 5 mo 0% complications, 0 mo	Short follow up interval	Chung et al 2016 [61]
				12	Case series	100% technical success 100% clinical success, 31.1 mo 0% complications, 31.1 m		Thomeer et al 2016 [62]
			Resurfacing	3	Case series	100% technical success 66% resolution of tinnitus, 4 mo 0% complications, 4 mo	Sample size Limited follow up	Hillman et al 2006 [63]
			Transmastoid plugging	13	Retrospective case series	100% technical success 84% clinical success (1 mo-2 y) 0% complication	Sample size Variable follow up	Haesendock et al 2016[64]
	Anemia	Medical treatment	Supplementation with Vitamin B12	1	Case report	N/a technical success 100% clinical success, 3 w 0% complications, 3 w	Sample size Short term follow up	Cochran and Kosmicki 1987 [65]
		Medical treatment	Supplementation with iron and or blood transfusions if patients had IDA	13	Single institution cross sectional study	100% technical success 75% clinical success, 1 mo 0% complications, 1 mo	Sample size Short term follow-up Female predominant population Not controlled by co-morbidities	Sunwoo et al 2018[66]

Non-vascular – Systemic	Subjective tinnitus	Cognitive behavioral therapy	Tinnitus retraining counselling + audiological rehabilitation versus usual care	492	Double blind randomized control trial	N/A technical success Decreased tinnitus severity p<0.0001) in patients with specialized care, 6 mo 0% complications	Multiple components to specialized care arm, difficult to determine which of those interventions contributed to improved patient symptoms	Cima et al 2012 [67]
	Chronic tinnitus	Repetitive transcranial magnetic stimulation	Repetitive transcranial magnetic stimulation	1228	Systematic review/ Meta-analysis	100% technical success Decreased tinnitus severity, 1 mo 0% complications	Limited number of studies included in the analysis (29)	Liang et al 2020 [68]
	Chronic tinnitus	Repetitive transcranial magnetic stimulation	Repetitive transcranial magnetic stimulation	233	Systematic review/ Meta-analysis	100% technical success No significant difference between control and treatment patients at 4 mo 0% complications	Limited number of studies used (5)	Meng et al 2011 [69]

Supplemental Figure 2. A standardized template for venous manometry and balloon test occlusion facilitates evaluation of venous causes of pulsatile tinnitus. Each position is numbered (#1-3 for the superior sagittal sinus, #4-18 even numbers for the right transverse sinus, sigmoid sinus, and jugular vein, and #5-19 odd numbers for the left transverse sinus, sigmoid sinus, and jugular vein). At particular positions, in addition to pressure measurements, we can record pulsatile tinnitus scores with and without balloon test occlusion, as indicated.

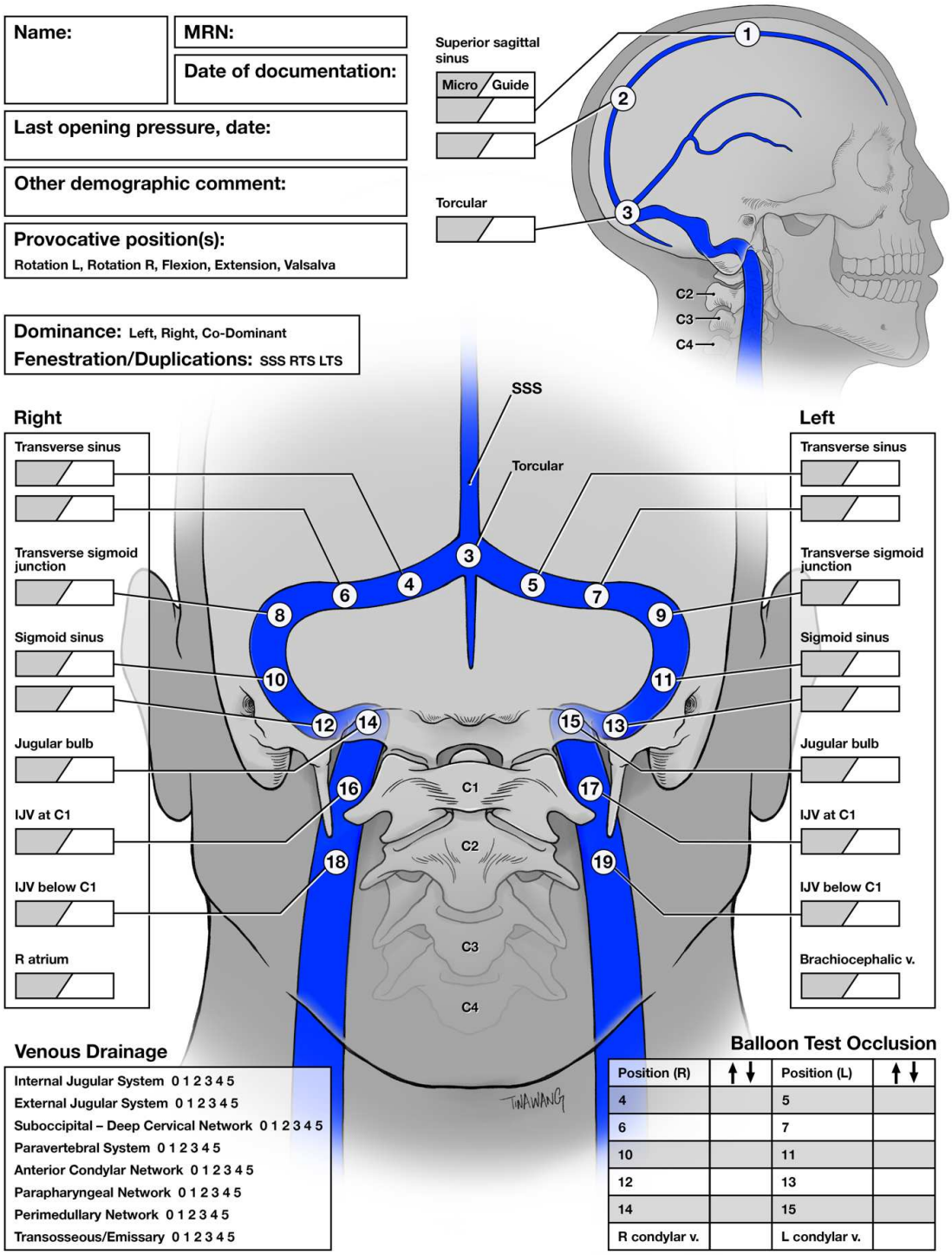

References

1 Kirkby-Bott J, Gibbs HH. Carotid endarterectomy relieves pulsatile tinnitus associated with severe ipsilateral carotid stenosis. *Eur J Vasc Endovasc Surg Off J Eur Soc Vasc Surg* 2004;**27**:651–3. doi:10.1016/j.ejvs.2004.02.025

2 Ihn YK, Jung WS, Kim B-S. Disappeared pulsatile tinnitus related to petrous segment stenosis of the ICA after relief of the stenosis by stenting. *Interv Neuroradiol J Peritherapeutic Neuroradiol Surg Proced Relat Neurosci* 2013;**19**:97–101. doi:10.1177/159101991301900115

3 Emery DJ, Ferguson RD, Williams JS. Pulsatile tinnitus cured by angioplasty and stenting of petrous carotid artery stenosis. *Arch Otolaryngol Head Neck Surg* 1998;**124**:460–1. doi:10.1001/archotol.124.4.460

4 Hartung O, Alimi YS, Juhan C. Tinnitus resulting from tandem lesions of the internal carotid artery: combined extracranial endarterectomy and intrapetrous primary stenting. *J Vasc Surg* 2004;**39**:679–81. doi:10.1016/j.jvs.2003.10.034

5 Kim S-M, Kim C-H, Lee C-Y. Petrous Carotid Aneurysm Causing Pulsatile Tinnitus: Case Report and Review of the Literature. *J Cerebrovasc Endovasc Neurosurg* 2018;**20**:35–9. doi:10.7461/jcen.2018.20.1.35

6 Kim D-K, Shin YS, Lee JH, *et al.* Pulsatile Tinnitus as the Sole Manifestation of an Internal Carotid Artery Aneurysm Successfully Treated by Coil Embolization. *Clin Exp Otorhinolaryngol* 2012;**5**:170–2. doi:10.3342/ceo.2012.5.3.170

7 Willinsky R, Lasjaunias P, Pruvost P, *et al.* Petrous internal carotid aneurysm causing epistaxis: balloon embolization with preservation of the parent vessel. *Neuroradiology* 1987;**29**:570–2. doi:10.1007/BF00350444

8 Chao Chen M, Wann Lin C. Facial Arteriovenous Malformation with Pulsatile Tinnitus: A Potentially Curable Cause of Chronic Insomnia. *Neuropsychiatry* 2018;**08**. doi:10.4172/Neuropsychiatry.1000364

9 Woo H-J, Song S-Y, Kim Y-D, *et al.* Arteriovenous malformation of the external ear: A case report. *Auris Nasus Larynx* 2008;**35**:556–8. doi:10.1016/j.anl.2007.11.005

10 Selleck AM, O'Connell B, Patel S, *et al.* Intraparotid Superficial Temporal Artery Arteriovenous Malformation Causing Persistent Pulsatile Tinnitus. *Otol Neurotol* 2020;**41**:e873. doi:10.1097/MAO.0000000000002666

11 Kim SH, Han SH, Song Y, *et al.* Arteriovenous malformation of the external ear: a clinical assessment with a scoping review of the literature. *Braz J Otorhinolaryngol* 2017;**83**:683–90. doi:10.1016/j.bjorl.2016.09.004

12 Aslan S, Yavuz H, Cagici AC, *et al.* Embolisation of an extensive arteriovenous malformation of the temporal region as an alternate treatment: case report. *J Laryngol Otol* 2008;**122**:737–40. doi:10.1017/S0022215108001977

13 de Paula Lucas C, Prandini MN, Spelle L, *et al.* Parallel transverse-sigmoid sinus harboring dural arteriovenous malformation. How to differentiate the pathological and normal sinus in order to treat and preserve patency and function. *Acta Neurochir (Wien)* 2010;**152**:523–7. doi:10.1007/s00701-009-0423-1

14 Caton MT, Narsinh KH, Baker A, *et al.* Endovascular treatment strategy, technique, and outcomes for dural arteriovenous fistulas of the marginal sinus region. *J NeuroInterventional Surg* Published Online First: 26 May 2021. doi:10.1136/neurintsurg-2021-017476

15 Hellstern V, Aguilar-Pérez M, Schob S, *et al.* Endovascular Treatment of Dural Arteriovenous Fistulas of the Anterior or Posterior Condylar Vein. *Clin Neuroradiol* 2019;**29**:341–9. doi:10.1007/s00062-018-0669-1

16 Brinjikji W, Lanzino G, Cloft HJ. Transvenous embolization of a posterior condylar canal fistula causing pulsatile tinnitus. *J NeuroInterventional Surg* Published Online First: 17 August 2020. doi:10.1136/neurintsurg-2020-016280

17 Lerut B, Vuyst CD, Ghekiere J, *et al.* Post-traumatic pulsatile tinnitus: the hallmark of a direct carotico-cavernous fistula. *J Laryngol Otol* 2007;**121**:1103–7. doi:10.1017/S0022215107005890

18 Fan Y, Li Y, Zhang T, *et al.* Carotid-Cavernous Sinus Fistula caused by Persistent Primitive Trigeminal Artery Aneurysm rupture: A case report. *J Stroke Cerebrovasc Dis Off J Natl Stroke Assoc* 2019;**28**:104306. doi:10.1016/j.jstrokecerebrovasdis.2019.104306

19 Nakahara M, Uozumi Y, Chiba Y, *et al.* Direct Carotid Cavernous Fistula Due to Rupture of a Cavernous Carotid Aneurysm Embedded Within a Prolactinoma After Cabergoline Administration. *World Neurosurg* 2019;**122**:495–9. doi:10.1016/j.wneu.2018.11.071

20 Mondel PK, Saraf R, Limaye US. Republished: Rete mirabile associated with pial arteriovenous fistula: imaging features with literature review. *J NeuroInterventional Surg* 2017;**9**:e36–e36. doi:10.1136/neurintsurg-2016-012939.rep

21 Honkura Y, Hidaka H, Ohta J, *et al.* Surgical treatment for the aberrant internal carotid artery in the middle ear with pulsatile tinnitus. *Auris Nasus Larynx* 2014;**41**:215–8. doi:10.1016/j.anl.2013.10.002

22 Song Y-S, Yuan Y-Y, Wang G-J, *et al.* Aberrant internal carotid artery causing objective pulsatile tinnitus and conductive hearing loss. *Acta Otolaryngol (Stockh)* 2012;**132**:1126–30. doi:10.3109/00016489.2012.684400

23 Anagiotos A, Kazantzi M, Tapis M. Aberrant internal carotid artery in the middle ear: the duplication variant. *BMJ Case Rep CP* 2019;**12**:e228865. doi:10.1136/bcr-2018-228865

24 Hashim ND, Jang SH, Moon IS. Endoscopic Intervention of Aberrant Carotid Artery in the Middle Ear. *Otol Neurotol* 2021;**42**:e82. doi:10.1097/MAO.0000000000002865

25 Kawamura Y, Sayama T, Maehara N, *et al.* Ruptured Aneurysm of an Aberrant Internal Carotid Artery Successfully Treated with Simultaneous Intervention and Surgery in a Hybrid Operating Room. *World Neurosurg* 2017;**102**:695.e1-695.e5. doi:10.1016/j.wneu.2017.03.133

26 Murphy null, Seidman null, Baugh null. Can a Persistent Stapedial Artery be Safely and Effectively Removed? A Case Report with Therapeutic Implications. *Int Tinnitus J* 1995;**1**:147–52.

27 Pirodda A, Sorrenti G, Marliani AF, *et al.* Arterial anomalies of the middle ear associated with stapes ankylosis. *J Laryngol Otol* 1994;**108**:237–9. doi:10.1017/s0022215100126398

28 NORDIC Idiopathic Intracranial Hypertension Study Group Writing Committee, Wall M, McDermott MP, *et al.* Effect of acetazolamide on visual function in patients with idiopathic intracranial hypertension and mild visual loss: the idiopathic intracranial hypertension treatment trial. *JAMA* 2014;**311**:1641–51. doi:10.1001/jama.2014.3312

29 Nicholson P, Brinjikji W, Radovanovic I, *et al.* Venous sinus stenting for idiopathic intracranial hypertension: a systematic review and meta-analysis. *J NeuroInterventional Surg* 2019;**11**:380–5. doi:10.1136/neurintsurg-2018-014172

30 Sugerman HJ, Felton WL, Sismanis A, *et al.* Gastric Surgery for Pseudotumor Cerebri Associated With Severe Obesity. *Ann Surg* 1999;**229**:634.

31 Fields JD, Javedani PP, Falardeau J, *et al.* Dural venous sinus angioplasty and stenting for the treatment of idiopathic intracranial hypertension. *J NeuroInterventional Surg* 2013;**5**:62–8. doi:10.1136/neurintsurg-2011-010156

32 Boddu S, Dinkin M, Suurna M, *et al.* Resolution of Pulsatile Tinnitus after Venous Sinus Stenting in Patients with Idiopathic Intracranial Hypertension. *PLOS ONE* 2016;**11**:e0164466. doi:10.1371/journal.pone.0164466

33 Kahan J, Sundararajan S, Brown K, *et al.* Predicting the need for retreatment in venous sinus stenting for idiopathic intracranial hypertension. *J NeuroInterventional Surg* 2021;**13**:574–9. doi:10.1136/neurintsurg-2020-016550

34 Garner RM, Aldridge JB, Wolfe SQ, *et al.* Quality of life, need for retreatment, and the re-equilibration phenomenon after venous sinus stenting for idiopathic intracranial hypertension. *J NeuroInterventional Surg* 2021;**13**:79–85. doi:10.1136/neurintsurg-2020-016124

35 Mollan SP, Mitchell JL, Ottridge RS, *et al.* Effectiveness of Bariatric Surgery vs Community Weight Management Intervention for the Treatment of Idiopathic Intracranial Hypertension: A Randomized Clinical Trial. *JAMA Neurol* Published Online First: 26 April 2021. doi:10.1001/jamaneurol.2021.0659

36 Satti SR, Leishangthem L, Chaudry MI. Meta-Analysis of CSF Diversion Procedures and Dural Venous Sinus Stenting in the Setting of Medically Refractory Idiopathic Intracranial Hypertension. *AJNR Am J Neuroradiol* 2015;**36**:1899–904. doi:10.3174/ajnr.A4377

37 Kalyvas AV, Hughes M, Koutsarnakis C, *et al.* Efficacy, complications and cost of surgical interventions for idiopathic intracranial hypertension: a systematic review of the literature. *Acta Neurochir (Wien)* 2017;**159**:33–49. doi:10.1007/s00701-016-3010-2

38 Mortimer AM, Harrington T, Steinfort B, *et al.* Endovascular treatment of jugular bulb diverticula causing debilitating pulsatile tinnitus. *BMJ Case Rep* 2015;**2015**. doi:10.1136/bcr-2014-011609

39 Drescher F, Maus V, Weber W, *et al.* Pulsatile tinnitus due to an aneurysmatic diverticulum of the jugular bulb treated with the Woven EndoBridge device. *Interv Neuroradiol J Peritherapeutic Neuroradiol Surg Proced Relat Neurosci* 2020;**26**:235–8. doi:10.1177/1591019919881582

40 Trivelato FP, Araújo JFS, dos Santos Silva R, *et al.* Endovascular treatment of pulsatile tinnitus associated with transverse sigmoid sinus aneurysms and jugular bulb anomalies. *Interv Neuroradiol* 2015;**21**:548–51. doi:10.1177/1591019915590367

41 El-Begermy MA, Rabie AN. A novel surgical technique for management of tinnitus due to high dehiscent jugular bulb. *Otolaryngol Neck Surg* 2010;**142**:576–81. doi:10.1016/j.otohns.2009.12.007

42 Shaikh MF, Mahboubi H, German M, *et al.* A novel approach for surgical repair of dehiscent high jugular bulb: Repair of Dehiscent High Jugular Bulb. *The Laryngoscope* 2013;**123**:1803–5. doi:10.1002/lary.23891

43 Kim CS, Kim SY, Choi H, *et al.* Transmastoid reshaping of the sigmoid sinus: preliminary study of a novel surgical method to quiet pulsatile tinnitus of an unrecognized vascular origin. *J Neurosurg* 2016;**125**:441–9. doi:10.3171/2015.6.JNS15961

44 Zenteno M, Murillo-Bonilla L, Martínez S, *et al.* Endovascular treatment of a transverse—sigmoid sinus aneurysm presenting as pulsatile tinnitus: Case report. *J Neurosurg* 2004;**100**:120–2. doi:10.3171/jns.2004.100.1.0120

45 Gard AP, Klopper HB, Thorell WE. Successful Endovascular Treatment of Pulsatile Tinnitus Caused by a Sigmoid Sinus Aneurysm. *Interv Neuroradiol* 2009;**15**:425–8.

46 Houdart E, Chapot R, Merland J-J. Aneurysm of a dural sigmoid sinus: A novel vascular cause of pulsatile tinnitus. *Ann Neurol* 2000;**48**:669–71. doi:https://doi.org/10.1002/1531-8249(200010)48:4<669::AID-ANA16>3.0.CO;2-6

47 Sanchez TG, Murao M, Kii M, *et al.* A New Therapeutic Procedure for Treatment of Objective Venous Pulsatile Tinnitus. ;:4.

48 Mehanna R, Shaltoni H, Morsi H, *et al.* Endovascular treatment of sigmoid sinus aneurysm presenting as devastating pulsatile tinnitus. A case report and review of literature. *Interv Neuroradiol J Peritherapeutic Neuroradiol Surg Proced Relat Neurosci* 2010;**16**:451–4. doi:10.1177/159101991001600413

49 Amans MR, Stout C, Dowd CF, *et al.* Resolution of pulsatile tinnitus after coil embolization of sigmoid sinus diverticulum. *Austin J Cerebrovasc Dis* 2014;**1**.https://escholarship.org/uc/item/6vq7j3x6 (accessed 17 Apr 2021).

50 Wang G-P, Zeng R, Ma X-B, *et al.* Surgical Treatment of Pulsatile Tinnitus Caused by the Sigmoid Sinus Diverticulum. *Medicine (Baltimore)* 2015;**94**. doi:10.1097/MD.0000000000000882

51 Eisenman DJ, Raghavan P, Hertzano R, *et al.* Evaluation and treatment of pulsatile tinnitus associated with sigmoid sinus wall anomalies. *The Laryngoscope* 2018;**128**:S1–13. doi:10.1002/lary.27218

52 Raghavan P, Serulle Y, Gandhi D, *et al.* Postoperative Imaging Findings following Sigmoid Sinus Wall Reconstruction for Pulse Synchronous Tinnitus. *Am J Neuroradiol* 2016;**37**:136–42. doi:10.3174/ajnr.A4511

53 Shastri RK, Chaudhary N, Pandey AS, *et al.* Venous Diverticula Causing Pulsatile Tinnitus Treated With Coil Embolization and Stent Placement With Resolution of Symptoms: Report of Two Cases and Review of the Literature. *Otol Neurotol* 2017;**38**:e302. doi:10.1097/MAO.0000000000001540

54 Lenck S, Labeyrie M-A, Vallee F, *et al.* Stent Placement for Disabling Pulsatile Tinnitus Caused by a Lateral Sinus Stenosis: A Retrospective Study. *Oper Neurosurg Hagerstown Md* 2017;**13**:560–5. doi:10.1093/ons/opx026

55 Eliezer M, Freitas RK, Fantoni M, *et al.* Selective embolization of the mastoid emissary vein for pulsatile tinnitus treatment: when is it indicated? *J Neurointerventional Surg* 2020;**12**:999.

56 Abdalkader M, Ma A, Cohen M, *et al.* Endovascular coiling of large mastoid emissary vein causing pulsatile tinnitus. *Interv Neuroradiol* 2020;**26**:821–5. doi:10.1177/1591019920926333

57 Department of Otorhinolaryngology-Head and Neck Surgery, Jeonbuk National University School of Medicine, Jeon-ju, Korea, Kim SG, Research Institute of Clinical Medicine of Jeonbuk National University-Biomedical Research Institute of Jeonbuk National University Hospital, Jeon-ju, Korea, *et al.* Surgical ligation of A Large Mastoid Emissary Vein in A Patient Complaining of Pulsatile Tinnitus. *J Int Adv Otol* 2021;**17**:84–6. doi:10.5152/iao.2020.8086

58 Sheehan JP, Tanaka S, Link MJ, *et al.* Gamma Knife surgery for the management of glomus tumors: a multicenter study: Clinical article. *J Neurosurg* 2012;**117**:246–54. doi:10.3171/2012.4.JNS11214

59 Dobberpuhl MR, Maxwell S, Feddock J, *et al.* Treatment Outcomes for Single Modality Management of Glomus Jugulare Tumors with Stereotactic Radiosurgery. *Otol Neurotol Off Publ Am Otol Soc Am Neurotol Soc Eur Acad Otol Neurotol* 2016;**37**:1406–10. doi:10.1097/MAO.0000000000001160

60 Devuyst L, Defreyne L, Praet M, *et al.* Treatment of glomus tympanicum tumors by preoperative embolization and total surgical resection. *Am J Otolaryngol* 2016;**37**:544–51. doi:10.1016/j.amjoto.2016.08.011

61 Chung LK, Ung N, Spasic M, *et al.* Clinical outcomes of middle fossa craniotomy for superior semicircular canal dehiscence repair. *J Neurosurg* 2016;**125**:1187–93. doi:10.3171/2015.8.JNS15391

62 Thomeer H, Bonnard D, Castetbon V, *et al.* Long-term results of middle fossa plugging of superior semicircular canal dehiscences: clinically and instrumentally demonstrated efficiency in a retrospective series of 16 ears. *Eur Arch Otorhinolaryngol* 2016;**273**:1689–96. doi:10.1007/s00405-015-3715-5

63 Hillman TA, Kertesz TR, Hadley K, *et al.* Reversible Peripheral Vestibulopathy: The Treatment of Superior Canal Dehiscence. *Otolaryngol Neck Surg* 2006;**134**:431–6. doi:10.1016/j.otohns.2005.10.033

64 Haesendonck GV, Heyning PV de, Rompaey VV. Retrospective cohort study on hearing outcome after transmastoid plugging in superior semicircular canal dehiscence syndrome: Our Experience. *Clin Otolaryngol* 2016;**41**:601–6. doi:https://doi.org/10.1111/coa.12539

65 Cochran JH, Kosmicki PW. Tinnitus as a Presenting Symptom in Pernicious Anemia. *Ann Otol Rhinol Laryngol* 1979;**88**:297–297. doi:10.1177/000348947908800226

66 Sunwoo W, Lee DY, Lee JY, *et al.* Characteristics of tinnitus found in anemia patients and analysis of population-based survey. *Auris Nasus Larynx* 2018;**45**:1152–8. doi:10.1016/j.anl.2018.04.001

67 Cima RF, Maes IH, Joore MA, *et al.* Specialised treatment based on cognitive behaviour therapy versus usual care for tinnitus: a randomised controlled trial. *The Lancet* 2012;**379**:1951–9. doi:10.1016/S0140-6736(12)60469-3

68 Liang Z, Yang H, Cheng G, *et al.* Repetitive transcranial magnetic stimulation on chronic tinnitus: a systematic review and meta-analysis. *BMC Psychiatry* 2020;**20**:547. doi:10.1186/s12888-020-02947-9

69 Meng Z, Liu S, Zheng Y, *et al.* Repetitive transcranial magnetic stimulation for tinnitus. *Cochrane Database Syst Rev* Published Online First: 2011. doi:10.1002/14651858.CD007946.pub2

ICMJE DISCLOSURE FORM

Date: 1/14/2022

Your Name: Matthew Amans

Manuscript Title: Management of Vascular Causes of Pulsatile Tinnitus

Manuscript Number (if known): Click or tap here to enter text.

In the interest of transparency, we ask you to disclose all relationships/activities/interests listed below that are related to the content of your manuscript. "Related" means any relation with for-profit or not-for-profit third parties whose interests may be affected by the content of the manuscript. Disclosure represents a commitment to transparency and does not necessarily indicate a bias. If you are in doubt about whether to list a relationship/activity/interest, it is preferable that you do so.

The author's relationships/activities/interests should be defined broadly. For example, if your manuscript pertains to the epidemiology of hypertension, you should declare all relationships with manufacturers of antihypertensive medication, even if that medication is not mentioned in the manuscript.

In item #1 below, report all support for the work reported in this manuscript without time limit. For all other items, the time frame for disclosure is the past 36 months.

		Name all entities with whom you have this relationship or indicate none (add rows as needed)	**Specifications/Comments (e.g., if payments were made to you or to your institution)**
Time frame: Since the initial planning of the work			
1	All support for the present manuscript (e.g., funding, provision of study materials, medical writing, article processing charges, etc.) **No time limit for this item.**	☐ **None**	
		NIH – National Heart, Lung and Blood Institute	R56HL149124 Grant
		Department of Defense	Investigator Initiated Grant
			Click the tab key to add additional rows.
Time frame: past 36 months			
2	Grants or contracts from any entity (if not indicated in item #1 above).	☐ **None**	
		NIH – National Institute on Deafness and other Communication Disorders	R21DC016087 Grant
3	Royalties or licenses	☐ **None**	

Narsinh KH, *et al. J NeuroIntervent Surg* 2022;0:1–8. doi: 10.1136/neurintsurg-2021-018015

		Name all entities with whom you have this relationship or indicate none (add rows as needed)	Specifications/Comments (e.g., if payments were made to you or to your institution)
4	Consulting fees	☐ **None**	
5	Payment or honoraria for lectures, presentations, speakers bureaus, manuscript writing or educational events	☐ **None**	
6	Payment for expert testimony	☐ **None**	
7	Support for attending meetings and/or travel	☐ **None**	
8	Patents planned, issued or pending	☐ **None**	
		System and method for diagnosing pulsatile tinnitus and other blood vessels disorders	
		Cerebral dural venous sinus stent	
		Cerebral blood flow reorganization	
9	Participation on a Data Safety Monitoring Board or Advisory Board	☐ **None**	
10	Leadership or fiduciary role in other board, society, committee or advocacy group, paid or unpaid	☐ **None**	

Narsinh KH, *et al. J NeuroIntervent Surg* 2022;0:1–8. doi: 10.1136/neurintsurg-2021-018015

		Name all entities with whom you have this relationship or indicate none (add rows as needed)	**Specifications/Comments (e.g., if payments were made to you or to your institution)**
11	Stock or stock options	☐ **None**	
12	Receipt of equipment, materials, drugs, medical writing, gifts or other services	☐ **None**	
13	Other financial or non-financial interests	☒ **None**	

Please place an "X" next to the following statement to indicate your agreement:

☒ I certify that I have answered every question and have not altered the wording of any of the questions on this form.

Narsinh KH, *et al. J NeuroIntervent Surg* 2022;0:1–8. doi: 10.1136/neurintsurg-2021-018015

ICMJE DISCLOSURE FORM

Date: 1/14/2022

Your Name: Madhavi Duvvuri

Manuscript Title: Management of Vascular Causes of Pulsatile Tinnitus

Manuscript Number (if known): Click or tap here to enter text.

In the interest of transparency, we ask you to disclose all relationships/activities/interests listed below that are related to the content of your manuscript. "Related" means any relation with for-profit or not-for-profit third parties whose interests may be affected by the content of the manuscript. Disclosure represents a commitment to transparency and does not necessarily indicate a bias. If you are in doubt about whether to list a relationship/activity/interest, it is preferable that you do so.

The author's relationships/activities/interests should be defined broadly. For example, if your manuscript pertains to the epidemiology of hypertension, you should declare all relationships with manufacturers of antihypertensive medication, even if that medication is not mentioned in the manuscript.

In item #1 below, report all support for the work reported in this manuscript without time limit. For all other items, the time frame for disclosure is the past 36 months.

		Name all entities with whom you have this relationship or indicate none (add rows as needed)	**Specifications/Comments (e.g., if payments were made to you or to your institution)**
Time frame: Since the initial planning of the work			
1	All support for the present manuscript (e.g., funding, provision of study materials, medical writing, article processing charges, etc.) **No time limit for this item.**	☒ None	
			Click the tab key to add additional rows.
Time frame: past 36 months			
2	Grants or contracts from any entity (if not indicated in item #1 above).	☒ **None**	
3	Royalties or licenses	☒ **None**	

Narsinh KH, *et al. J NeuroIntervent Surg* 2022;0:1–8. doi: 10.1136/neurintsurg-2021-018015

		Name all entities with whom you have this relationship or indicate none (add rows as needed)	**Specifications/Comments (e.g., if payments were made to you or to your institution)**
4	Consulting fees	☒ **None**	
5	Payment or honoraria for lectures, presentations, speakers bureaus, manuscript writing or educational events	☒ **None**	
6	Payment for expert testimony	☒ **None**	
7	Support for attending meetings and/or travel	☒ **None**	
8	Patents planned, issued or pending	☒ **None**	
9	Participation on a Data Safety Monitoring Board or Advisory Board	☒ **None**	
10	Leadership or fiduciary role in other board, society, committee or advocacy group, paid or unpaid	☒ **None**	

Narsinh KH, *et al. J NeuroIntervent Surg* 2022;0:1–8. doi: 10.1136/neurintsurg-2021-018015

		Name all entities with whom you have this relationship or indicate none (add rows as needed)	**Specifications/Comments (e.g., if payments were made to you or to your institution)**
11	Stock or stock options	☒ **None**	
12	Receipt of equipment, materials, drugs, medical writing, gifts or other services	☒ **None**	
13	Other financial or non-financial interests	☒ **None**	

Please place an "X" next to the following statement to indicate your agreement:

☒ I certify that I have answered every question and have not altered the wording of any of the questions on this form.

ICMJE DISCLOSURE FORM

Date: 1/14/2022

Your Name: Ferdinand Hui

Manuscript Title: Management of Vascular Causes of Pulsatile Tinnitus

Manuscript Number (if known): Click or tap here to enter text.

In the interest of transparency, we ask you to disclose all relationships/activities/interests listed below that are related to the content of your manuscript. "Related" means any relation with for-profit or not-for-profit third parties whose interests may be affected by the content of the manuscript. Disclosure represents a commitment to transparency and does not necessarily indicate a bias. If you are in doubt about whether to list a relationship/activity/interest, it is preferable that you do so.

The author's relationships/activities/interests should be defined broadly. For example, if your manuscript pertains to the epidemiology of hypertension, you should declare all relationships with manufacturers of antihypertensive medication, even if that medication is not mentioned in the manuscript.

In item #1 below, report all support for the work reported in this manuscript without time limit. For all other items, the time frame for disclosure is the past 36 months.

		Name all entities with whom you have this relationship or indicate none (add rows as needed)	**Specifications/Comments (e.g., if payments were made to you or to your institution)**
Time frame: Since the initial planning of the work			
1	All support for the present manuscript (e.g., funding, provision of study materials, medical writing, article processing charges, etc.) **No time limit for this item.**	☒ **None**	
			Click the tab key to add additional rows.
Time frame: past 36 months			
2	Grants or contracts from any entity (if not indicated in item #1 above).	☒ **None**	
3	Royalties or licenses	☒ **None**	

Narsinh KH, *et al. J NeuroIntervent Surg* 2022;0:1–8. doi: 10.1136/neurintsurg-2021-018015

		Name all entities with whom you have this relationship or indicate none (add rows as needed)	**Specifications/Comments (e.g., if payments were made to you or to your institution)**
4	Consulting fees	☒ **None**	
5	Payment or honoraria for lectures, presentations, speakers bureaus, manuscript writing or educational events	☒ **None**	
6	Payment for expert testimony	☒ **None**	
7	Support for attending meetings and/or travel	☒ **None**	
8	Patents planned, issued or pending	☒ **None**	
9	Participation on a Data Safety Monitoring Board or Advisory Board	☒ **None**	
10	Leadership or fiduciary role in other board, society, committee or advocacy group, paid or unpaid	☒ **None**	

Narsinh KH, *et al. J NeuroIntervent Surg* 2022;0:1–8. doi: 10.1136/neurintsurg-2021-018015

		Name all entities with whom you have this relationship or indicate none (add rows as needed)	**Specifications/Comments (e.g., if payments were made to you or to your institution)**
11	Stock or stock options	☒ **None**	
12	Receipt of equipment, materials, drugs, medical writing, gifts or other services	☒ **None**	
13	Other financial or non-financial interests	☒ **None**	

Please place an "X" next to the following statement to indicate your agreement:

☒ I certify that I have answered every question and have not altered the wording of any of the questions on this form.

ICMJE DISCLOSURE FORM

Date: 1/14/2022

Your Name: Karl Meisel

Manuscript Title: Management of Vascular Causes of Pulsatile Tinnitus

Manuscript Number (if known): Click or tap here to enter text.

In the interest of transparency, we ask you to disclose all relationships/activities/interests listed below that are related to the content of your manuscript. "Related" means any relation with for-profit or not-for-profit third parties whose interests may be affected by the content of the manuscript. Disclosure represents a commitment to transparency and does not necessarily indicate a bias. If you are in doubt about whether to list a relationship/activity/interest, it is preferable that you do so.

The author's relationships/activities/interests should be defined broadly. For example, if your manuscript pertains to the epidemiology of hypertension, you should declare all relationships with manufacturers of antihypertensive medication, even if that medication is not mentioned in the manuscript.

In item #1 below, report all support for the work reported in this manuscript without time limit. For all other items, the time frame for disclosure is the past 36 months.

		Name all entities with whom you have this relationship or indicate none (add rows as needed)	**Specifications/Comments (e.g., if payments were made to you or to your institution)**
Time frame: Since the initial planning of the work			
1	All support for the present manuscript (e.g., funding, provision of study materials, medical writing, article processing charges, etc.) **No time limit for this item.**	☒ **None**	
			Click the tab key to add additional rows.
Time frame: past 36 months			
2	Grants or contracts from any entity (if not indicated in item #1 above).	☒ **None**	
3	Royalties or licenses	☒ **None**	

Narsinh KH, *et al. J NeuroIntervent Surg* 2022;0:1–8. doi: 10.1136/neurintsurg-2021-018015

		Name all entities with whom you have this relationship or indicate none (add rows as needed)	**Specifications/Comments (e.g., if payments were made to you or to your institution)**
4	Consulting fees	☒ **None**	
5	Payment or honoraria for lectures, presentations, speakers bureaus, manuscript writing or educational events	☒ **None**	
6	Payment for expert testimony	☒ **None**	
7	Support for attending meetings and/or travel	☒ **None**	
8	Patents planned, issued or pending	☒ **None**	
9	Participation on a Data Safety Monitoring Board or Advisory Board	☒ **None**	
10	Leadership or fiduciary role in other board, society, committee or advocacy group, paid or unpaid	☒ **None**	

Narsinh KH, *et al. J NeuroIntervent Surg* 2022;0:1–8. doi: 10.1136/neurintsurg-2021-018015

		Name all entities with whom you have this relationship or indicate none (add rows as needed)	**Specifications/Comments (e.g., if payments were made to you or to your institution)**
11	Stock or stock options	☒ **None**	
12	Receipt of equipment, materials, drugs, medical writing, gifts or other services	☒ **None**	
13	Other financial or non-financial interests	☒ **None**	

Please place an "X" next to the following statement to indicate your agreement:

☒ I certify that I have answered every question and have not altered the wording of any of the questions on this form.

ICMJE DISCLOSURE FORM

Date: 1/14/2022

Your Name: Kazim Narsinh

Manuscript Title: Management of Vascular Causes of Pulsatile Tinnitus

Manuscript Number (if known): Click or tap here to enter text.

In the interest of transparency, we ask you to disclose all relationships/activities/interests listed below that are related to the content of your manuscript. "Related" means any relation with for-profit or not-for-profit third parties whose interests may be affected by the content of the manuscript. Disclosure represents a commitment to transparency and does not necessarily indicate a bias. If you are in doubt about whether to list a relationship/activity/interest, it is preferable that you do so.

The author's relationships/activities/interests should be defined broadly. For example, if your manuscript pertains to the epidemiology of hypertension, you should declare all relationships with manufacturers of antihypertensive medication, even if that medication is not mentioned in the manuscript.

In item #1 below, report all support for the work reported in this manuscript without time limit. For all other items, the time frame for disclosure is the past 36 months.

		Name all entities with whom you have this relationship or indicate none (add rows as needed)	**Specifications/Comments (e.g., if payments were made to you or to your institution)**
Time frame: Since the initial planning of the work			
1	All support for the present manuscript (e.g., funding, provision of study materials, medical writing, article processing charges, etc.) **No time limit for this item.**	☒ **None**	
			Click the tab key to add additional rows.
Time frame: past 36 months			
2	Grants or contracts from any entity (if not indicated in item #1 above).	☒ **None**	
3	Royalties or licenses	☒ **None**	

Narsinh KH, *et al. J NeuroIntervent Surg* 2022;0:1–8. doi: 10.1136/neurintsurg-2021-018015

		Name all entities with whom you have this relationship or indicate none (add rows as needed)	**Specifications/Comments (e.g., if payments were made to you or to your institution)**
4	Consulting fees	☒ **None**	
5	Payment or honoraria for lectures, presentations, speakers bureaus, manuscript writing or educational events	☒ **None**	
6	Payment for expert testimony	☒ **None**	
7	Support for attending meetings and/or travel	☒ **None**	
8	Patents planned, issued or pending	☒ **None**	
9	Participation on a Data Safety Monitoring Board or Advisory Board	☒ **None**	
10	Leadership or fiduciary role in other board, society, committee or advocacy group, paid or unpaid	☒ **None**	

Narsinh KH, *et al. J NeuroIntervent Surg* 2022;0:1–8. doi: 10.1136/neurintsurg-2021-018015

		Name all entities with whom you have this relationship or indicate none (add rows as needed)	**Specifications/Comments (e.g., if payments were made to you or to your institution)**
11	Stock or stock options	☒ **None**	
12	Receipt of equipment, materials, drugs, medical writing, gifts or other services	☒ **None**	
13	Other financial or non-financial interests	☒ **None**	

Please place an "X" next to the following statement to indicate your agreement:

☒ I certify that I have answered every question and have not altered the wording of any of the questions on this form.