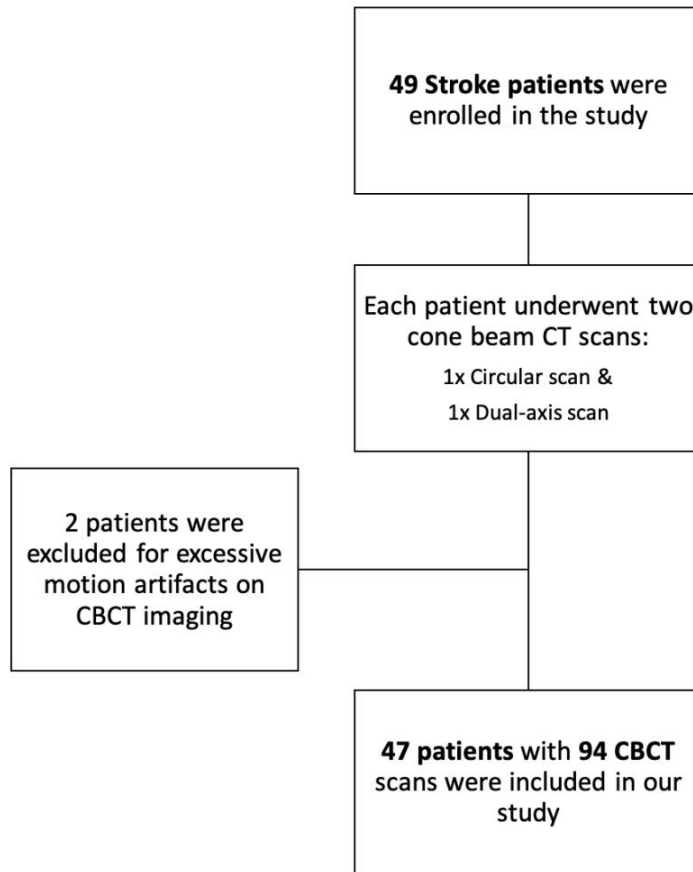


SUPPLEMENTAL MATERIAL



Supplemental Figure 1. Patient flow diagram

Supplemental Video 1. Butterfly trajectory demonstrated with incorporation of cranial and caudal angulation along the rotational cone beam CT imaging scan acquisition.