



Original research

Endosaccular flow disruption with the Contour Neurovascular System: angiographic and clinical results in a single-center study of 60 unruptured intracranial aneurysms

Alessandra Biondi ^{1,2}, Panagiotis Primikiris,¹ Giovanni Vitale,¹ Guillaume Charbonnier ^{1,2}

► Additional supplemental material is published online only. To view, please visit the journal online (<http://dx.doi.org/10.1136/jnis-2022-019271>).

¹Department of Interventional Neuroradiology, University Hospital Centre Besancon, Besancon, France
²Laboratoire de Recherches Intégratives en Neurosciences et Psychologie Cognitive - UR 481, Université de Franche-Comté, Besancon, France

Correspondence to

Professor Alessandra Biondi, Department of Interventional Neuroradiology, University Hospital Centre Besancon, Besancon 25030, France; biondi.alessandra@gmail.com

Received 13 June 2022
Accepted 6 August 2022
Published Online First
22 August 2022

ABSTRACT

Background The Contour Neurovascular System is a novel device designed to treat intracranial aneurysms by intrasaccular flow disruption. We report our experience and mid-term follow-up in a series of patients treated with the Contour.

Methods The patients were divided into an intention to treat and a per protocol population, the latter defined by the successful implantation of the Contour device. The intention to treat population included 53 patients (30 women, mean age 56 years) with 60 unruptured intracranial aneurysms (53 in the anterior circulation and seven in the posterior circulation). There was clinical and angiographic follow-up immediate postoperatively and at 24 hours, 3 months and 1 year using the Raymond–Roy classification and the O’Kelly–Marotta grading scale.

Results The Contour was successfully implanted in 54/60 (90%) aneurysms. With regard to the angiographic follow-up, there was adequate occlusion (defined as complete occlusion or presence of a neck remnant) in 31.5% of 54 aneurysms immediately postoperatively, 62.3% (in 53/54 aneurysms) at 24 hours, 81.4% (in 43/54 aneurysms) at 3 months, and 89.3% (in 28/54 aneurysms) at 1 year. Technical complications in 60 aneurysms of the intention to treat population included two (3.3%) inadvertent detachments of the device. Thromboembolic events were observed in four of the 60 aneurysms (6.7%), with no clinical symptoms in three patients and transient morbidity in one (1.7%). No aneurysm bleeding was observed and no patient was retreated during the 1-year follow-up period. There was no permanent morbidity or mortality.

Conclusions The Contour device is effective and safe in the treatment of intracranial aneurysms. However, more experience and long-term follow-up are needed.

WHAT IS ALREADY KNOWN ON THIS TOPIC

⇒ There is to date limited clinical experience regarding intrasaccular flow disruption with the novel Contour device.

WHAT THIS STUDY ADDS

⇒ We present the largest clinical series to date reporting angiographic and clinical results as well as complications and technical pearls.

HOW THIS STUDY MIGHT AFFECT RESEARCH, PRACTICE OR POLICY

⇒ The Contour is a promising device but further studies are needed, especially regarding the long-term follow-up.

flow disruption. The first device was the Luna Aneurysm Embolization System (LUNA AES; Medtronic, Irvine, California, USA), followed by the Woven EndoBridge (WEB) device (Microvention, Aliso Viejo, California, USA) and finally the Contour Neurovascular System (Cerus Endovascular, Fremont, California, USA).^{5–8} These devices, constructed of a tightly braided wire mesh, are placed inside the aneurysm promoting flow disruption and intrasaccular thrombosis while the proximal mesh of the device, between the aneurysm neck and parent artery, favors neo-endothelial growth and aneurysm occlusion.⁷ Among the devices for endosaccular flow disruption, there is limited literature on the Contour Neurovascular System as it has been more recently introduced to clinical practice. The objective of our study is to report our experience with the Contour device in what we believe to be the largest clinical series to date.

INTRODUCTION

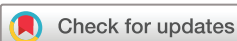Since the advent of endovascular treatment of intracranial aneurysms, different techniques including balloon remodeling, stent-assisted coiling and flow-diverting stents have evolved in order to treat more complex and wide-necked aneurysms, expanding indications and improving results.^{1–4} Over the past decade an innovative endovascular treatment has been developed for wide-necked bifurcation aneurysms using devices achieving intrasaccular

MATERIALS AND METHODS

Study population

This is a retrospective single-arm study based on a prospective single-center registry of a consecutive series of patients treated for intracranial aneurysm with the Contour Neurovascular System. The clinical and imaging records of all patients included from June 2020 to March 2022 were reviewed.

We collected demographic and clinical data, angiographic characteristics of the aneurysm



© Author(s) (or their employer(s)) 2023. No commercial re-use. See rights and permissions. Published by BMJ.

To cite: Biondi A, Primikiris P, Vitale G, et al. *J NeuroIntervent Surg* 2023;**15**:838–843.

(location, maximal dimension, size of the dome and neck and their ratio), angiographic and clinical results and follow-up. Postoperative angiographic controls were reviewed independently by two senior interventional neuroradiologists and were classified according to the Raymond–Roy (RR) classification and the O’Kelly–Marotta (OKM) grading scale. In case of disagreement, the angiographic classification was defined by consensus among all the authors. We considered as an adequate occlusion the complete occlusion of the aneurysm or the presence of a neck remnant. Clinical evaluation including the modified Rankin Scale was performed before, immediately after the procedure and at 1 month postoperatively, as well as at each angiographic control during follow-up. Follow-up DSA was performed at 24 hours and at 3 and 12 months.

In order to have a homogeneous series, we excluded ruptured aneurysms. The patients were divided into an intention to treat population and a per protocol population, the latter defined by the successful implantation of the Contour. We present the procedural complications of the Contour in both populations and the results of the per protocol population.

The indication for treatment and the technique (endovascular or surgery) was decided in our center on a case-by-case basis by a multidisciplinary team including interventional neuroradiologists, neurosurgeons and neurologists. The decision for treatment specifically with the Contour device was made by the interventional neuroradiologist based on the anatomic characteristics of the aneurysm.

The characteristics of the patients and the aneurysms are shown in [table 1](#).

Procedure

All patients underwent endovascular treatment under general anesthesia using a triaxial system.

The microcatheter to deliver the device was initially a Headway 27 (Microvention). After the introduction of the 0.021 Contour device, a Headway 21 (Microvention), a Via 21 (Microvention) or, more rarely, a Phenom 21 (Medtronic) were used.

The Contour targets the proximal half and the neck of the aneurysmal lesion. Consequently, the operator has to consider the neck and the widest diameter at the equatorial plane. Careful measurements of the aneurysm at the level of the equatorial plane and the neck were performed in at least two orthogonal projections on three-dimensional DSA. After deployment of the device, an angiogram was performed to evaluate the positioning as well as the intrasaccular stagnation of contrast. Whenever the result was not considered satisfactory, the device was re-sheathed and re-deployed. In case of inappropriate sizing, the device was removed and another with a different size was deployed. The correct deployment of the Contour was evaluated on DSA and no-subtracted images paying attention to the position of the device in relation to the aneurysm as well as the patency of the adjacent vessels while evaluating the exact location of the Contour marker in the parent artery. A flat-panel CT was systematically performed in the angiosuite at the end of the procedure. In some cases it was performed before the detachment when the DSA was not sufficient for a precise evaluation of the Contour deployment.

When the patients were not receiving chronic antithrombotic therapy, the procedure was done under IV heparin while 250 mg aspirin were administered intravenously after deployment of the Contour device. The postoperative protocol was oral aspirin 75 mg twice a day for 1 month.

Table 1 Patient and aneurysm population

No of patients	53
Women	57% (30/53)
Age, median (IQR)	55.0 (51.0; 62.0)
Hypertension	53% (28/53)
Diabetes	1.9% (1/53)
Dyslipidemia	15% (8/53)
Smoker	34% (18/53)
Former smoker	19% (10/53)
Baseline mRS 0	89% (47/53)
mRS 1	9% (5/53)
mRS 2	2% (1/53)
No of aneurysms	60
Recanalization	13% (8/60)
Previously ruptured	8.3% (5/60)
Aneurysm location:	
Anterior circulation	88% (53/60)
Posterior circulation	12% (7/60)
Maximal size, mm, median (IQR)	5.0 (4.3; 6.1)
Neck size, mm, median (IQR)	3.7 (3.0; 4.3)
Dome, mm, median (IQR)	4.7 (4.2; 5.6)
D/N ratio, median (IQR)	1.3 (1.1; 1.5)
Size of Contour implanted:	
5	31% (17/54)
7	43% (23/54)
9	20% (11/54)
11	4% (2/54)
14	2% (1/54)
Mean (range) duration of procedure, min	78,9 (27–208)
Contour failed implantation	10% (6/60)
D/N, dome to neck ratio; mRS, modified Rankin Scale.	

Statistical methods

We performed a descriptive analysis of the intention to treat population with quantitative variables as median and IQR and qualitative variables as percentages. We then tested all the variables listed in [table 1](#) for prediction of the occlusion rate in the per protocol population. For this analysis, quantitative variables were evaluated with the Mann–Whitney test and qualitative variables with the Fisher test. A p value <0.05 was considered statistically significant. We also performed a univariate analysis to evaluate an association with thromboembolic events.

RESULTS

The center registry included a consecutive series of 56 patients with 63 intracranial aneurysms in the intention to treat population. There were 32 women and 24 men. The mean age was 55.5 years (range 32–81). Fifty-three aneurysms were unruptured, eight recanalized (four unruptured and four ruptured in the past and previously treated with coils) and two acutely ruptured.

Three of the 63 aneurysms in three patients were excluded from the study. Two of these excluded aneurysms were ruptured and the third was an off-label use in a large partially thrombosed dissecting M1 aneurysm in which, at the end of the coiling procedure, we deployed a Contour device at the entry point as a ‘cork’.

Among the 60 included aneurysms, 53 were located in the anterior circulation and seven in the posterior circulation. Locations included 23 aneurysms of the anterior communicating artery complex (two in the A2 segment), 16 in the middle cerebral artery (MCA) (two in the M1 segment, 12 in the MCA bifurcation, and two in a branch beyond the bifurcation), four in the carotid-ophthalmic segment, five in the posterior communicating artery, three in the anterior choroidal artery, one superior hypophyseal aneurysm, one in the internal carotid artery bifurcation, four at the basilar artery tip, two in the superior cerebellar artery and one in the posterior inferior cerebellar artery.

Regarding size, 48 aneurysms were <7 mm and 12 were in the range of 7–9.5 mm. The mean aneurysm size was 5.5 mm (range 2.9–9.5 mm) and the mean neck size was 3.9 mm (range 2.2–9 mm). The mean dome to neck ratio was 1.4 (range 0.9–2.5). Thirty-nine aneurysms were on the left side, 15 on the right, and side was not applicable in six.

Clinical follow-up was assessed by the modified Rankin Scale (mRS). The pre-procedural mRS score was 0 in 47 patients, 1 in five patients and 2 in one patient.

Catheterization of the aneurysms and deployment of the Contour were performed in all 60 aneurysms in the intention to treat population. The Contour was detached in 54/60 aneurysms (90%) and it was not implanted in six (10%) because of inappropriate placement or size of the device resulting in inadequate occlusion of the aneurysm and/or a protrusion in the parent artery. No periprocedural complications were observed in the six patients in which the Contour was not implanted, five of whom were treated with a WEB device in the same intervention and one patient was scheduled later for a flow diverter stent.

The mean duration of the procedure from the first angiographic run to the last run after the deployment of the Contour was 78.9 min (range 27–208 min).

We report the angiographic (table 2) and clinical results in a series of 54 unruptured or recanalized saccular aneurysms in 50 patients.

Immediate angiographic results

Seventeen out of 54 aneurysms were treated with the 5 mm Contour device, 23 with the 7 mm, 11 with the 9 mm, two with the 11 mm, and one with the 14 mm device.

Immediate angiographic results in 54 implanted Contour devices showed complete occlusion in 9/54 (16.7%) cases, neck remnant in 8/54 (14.8%) and residual aneurysms in 37/54 (68.5%), which resulted in 31.5% of immediate adequate occlusion. In four of the 37 (10.8%) residual aneurysms intrasaccular contrast stasis was not observed.

Angiographic results at 24 hours

Angiographic control at 24 hours was available for 53 of the 54 aneurysms (98.1%), showing complete occlusion in 15/53 (28.3%) cases, neck remnant in 18/53 (34%) and residual aneurysm in 20/53 (37.7%), which resulted in 62.3% with adequate occlusion at 24 hours. Compared with the results observed immediately after the procedure, the occlusion rate at the 24-hour angiographic follow-up improved in 29/53 (54.7%) aneurysms, was not changed in 22/53 (41.5%), and worsened in 2/53 (3.8%).

Analysis of the variables listed in table 1 showed no statistical association with adequate 24-hour occlusion.

Angiographic follow-up at 3 months

Angiographic follow-up at 3 months was available in 43/54 (79.6%) aneurysms. Total occlusion was seen in 20/43 (46.5%) aneurysms, neck remnant in 15/43 (34.9%) and residual aneurysms in 8/43 (18.6%), resulting in 81.4% adequate occlusion at 3 months. In one patient we observed an asymptomatic occlusion of the posterior communicating artery due to slight modification in the position of the Contour. Immediate postoperative OKM grade was predictive of the 3-month adequate occlusion (p=0.042).

At the 3-month angiographic follow-up, larger dome (p=0.023) and neck size (p<0.01) were associated with a worse outcome regarding adequate occlusion.

Angiographic follow-up at 1 year

The 1-year angiographic follow-up was available in 28/54 (51.8%) aneurysms, showing complete occlusion in 13/28 cases (46.4%), neck remnant in 12/28 (42.9%) and residual aneurysm in 3/28 (10.7%), resulting in 89.3% adequate occlusion at 1 year. The sample was considered not sufficient for statistical analysis at 1-year follow-up.

Illustrative cases of progressive aneurysm occlusion during DSA follow-up are shown in figure 1.

Complications and clinical follow-up

Technical complications in the 60 aneurysms in the intention to treat population included two (3.3%) inadvertent detachments of the device. In one case the detachment of the Contour occurred during the maneuvers of deployment and an Atlas stent (Stryker, Kalamazoo, Michigan, USA) was deployed in order to adjust the protrusion of the device in the parent artery (figure 2). In the other case the device was already correctly implanted.

Thromboembolic events were observed in 4/60 (6.7%) aneurysms in the intention to treat population with no clinical

Table 2 Angiographic results

Contour implanted (n=54)	Raymond–Roy			O’Kelly–Marotta									
	I	II	III	A1	A2	A3	B1	B2	B3	C1	C2	C3	D
Postoperative follow-up	17% (9/54)	15% (8/54)	68% (37/54)	5.6% (3/54)	5.6% (3/54)	28% (15/54)	–	9.3% (5/54)	24% (13/54)	7.4% (4/54)	1.9% (1/54)	5.6% (3/54)	13% (7/54)
24-hour follow-up	28% (15/53)	34% (18/53)	38% (20/53)	2% (1/53)	5.6% (3/53)	11% (6/53)	4% (2/53)	6% (3/53)	11% (6/53)	23% (12/53)	2% (1/53)	8% (4/53)	28% (15/53)
3-month follow-up	47% (20/43)	35% (15/43)	18% (8/43)	2.3% (1/43)	2.3% (1/43)	–	9.3% (4/43)	–	9.3% (4/43)	27.9% (12/43)	–	–	48.8% (21/43)
1-year follow-up	46% (13/28)	43% (12/28)	11% (3/28)	3.6% (1/28)	–	–	3.6% (1/28)	3.6% (1/28)	7.1% (2/28)	36% (10/28)	–	–	46% (13/28)

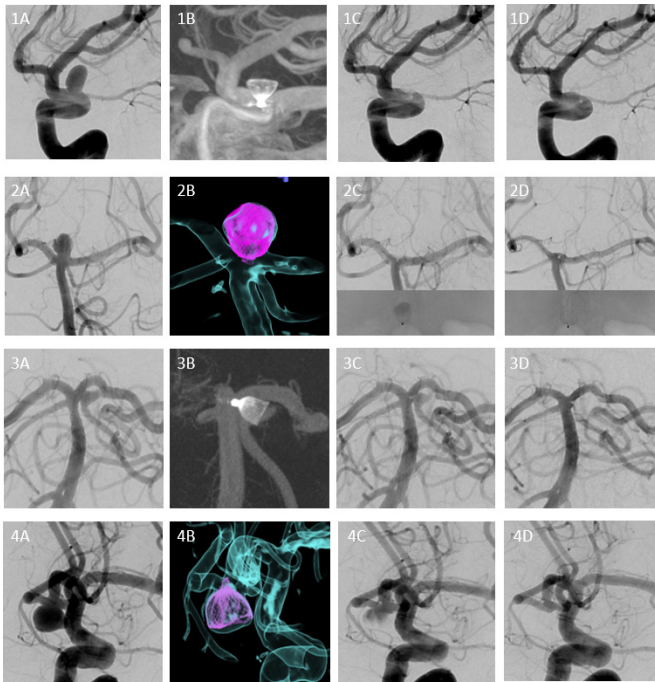


Figure 1 Illustrative cases of progressive aneurysm occlusion during DSA follow-up. Case 1: carotid-ophthalmic aneurysm (1A) treated with a Contour 7 allowing immediate complete occlusion assessed by postoperative DynaCT (1B) and DSA (1C). Persistent occlusion at 24 hours and 3 months (not shown) and at 1-year follow-up (1D). Case 2: basilar tip aneurysm (2A) treated with a Contour 9 with immediate occlusion and contrast stasis seen on no-subtracted angiogram (2B). Persistent complete occlusion at 24 hours (2C). At 1-year follow-up, a slight flattening of the Contour at the level of the neck is observed (2D). Case 3: superior cerebellar artery aneurysm (3A) treated with a Contour 5 with persistent aneurysm opacification on the postoperative DynaCT (3B) and DSA (3C). At 24-hour follow-up complete occlusion is observed (3D). Case 4: anterior communicating artery aneurysm on DSA (4A) with successful deployment of the Contour 11 on three-dimensional fusion imaging (4B). Partial persistent aneurysm opacification is seen on the postoperative DSA (not shown) and at 24-hour follow-up (4C). Complete occlusion is observed at 4-month DSA (4D).

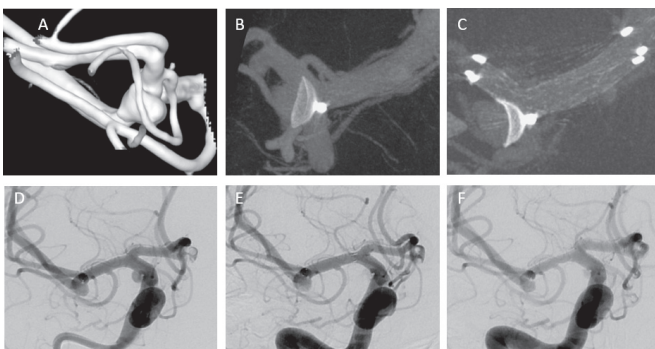


Figure 2 Irregular middle cerebral artery aneurysm on three-dimensional angiogram (A). Inadvertent detachment of the Contour 5 led to protrusion of the device on the superior branch with significant stenosis assessed by DynaCT (B). The deployment of a Neuroform Atlas stent in the superior branch extending to the M1 segment allowed the repositioning of the device inside the aneurysm with complete permeability of the parent artery (C). Immediate postoperative (D), 24-hour (E) and 3-month DSA follow-up (F) show a residual aneurysm. The patient was still under dual antiplatelet therapy (aspirin and ticagrelor).

symptoms in three patients and transient morbidity in one (1.7%). Regarding these four cases, asymptomatic small thrombotic fragments adjacent to the Contour were observed in two cases, one at the end of the procedure and one at the 24-hour DSA. Both patients were receiving a prophylactic dose of aspirin according to our protocol and no additional treatment was needed. In the third case we observed the formation of thrombus at the Contour marker during treatment of an anterior communicating artery aneurysm, necessitating an intraprocedural administration of tirofiban. There was complete resolution of the thrombus and the patient was asymptomatic. Finally, the fourth patient, treated for a carotid-ophthalmic aneurysm, had a postoperative transient mild hemiparesis which was completely regressive within 24 hours. The MRI scan showed small frontal cortical ischemic lesions on diffusion sequences. The lesions were attributed to a thrombus at the level of a cervical carotid diaphragm, aspirated during the intervention.

We analyzed every baseline variable for prediction of thromboembolic complications but no statistical association was found.

One patient (1.7%) had a regressive contrast-induced encephalopathy responsible for a transient aphasia.

The 1-month clinical follow-up was available for all 50 patients who were treated for 54 aneurysms. Five (10%) patients treated for five aneurysms complained of unusual headache which appeared within the first 2 weeks after the procedure and completely regressed in a few days.

The 3-month clinical follow-up was available for 40/50 (80%) patients treated for 43 aneurysms and the 1-year clinical follow-up was available for 26/50 (52%) patients treated for 28 aneurysms. At the 3-month and 1-year follow-ups, the mRS score in relation to the pretreatment state was unmodified in all patients.

No bleeding was observed during the periprocedural and follow-up period. No delayed adverse events were observed and no patient was retreated during the 1-year follow-up. There was no permanent morbidity or mortality.

DISCUSSION

In this single-center series, we report our experience with the Contour device in the treatment of 60 intracranial unruptured aneurysms. The device was successfully implanted in 54/60 (90%) cases with a 62% rate of adequate occlusion at 24-hour follow-up (available in 53/54 aneurysms), 81% at 3 months (in 43/54 aneurysms) and 89.3% at 1-year follow-up (in 28/54 aneurysms). Technical complications included 2/60 cases (3.3%) in whom there was an inadvertent detachment of the Contour which, in one case, was probably caused by multiple maneuvers of deployment and the tension in the angled microcatheter. Thromboembolic events were observed in 4/60 aneurysms (6.6%) and were asymptomatic in three cases and with transient morbidity in one case (1.7%). There was no permanent morbidity or mortality.

There is to date limited literature reporting the clinical experience with the Contour device.^{8–13} Among these studies there is a series of 11 patients reporting adequate occlusion (RR I–II) in 9/11 patients (two patients were lost to follow-up) and two thromboembolic events with no clinical sequelae.⁸ In three other patients the device was not implanted.⁸ Studies on the Contour device include also a case report with good results at 3-month follow-up using the new 0.021 inch compatible device,¹⁰ a case report of a combined (coils and Contour) treatment of a ruptured posterior communicating artery aneurysm,¹² and a small series of three cases which reported complete occlusion in 2/3 aneurysms.⁹ The combination of

coiling and the Contour device has been reported in a series of eight patients (three of whom presented with rupture), with immediate complete occlusion in five of the eight cases.¹³ The largest published study is the multicenter CERUS study which reported the results in a series of 34 aneurysms with successful implantation in 32/34 (94%) aneurysms and adequate occlusion (RR I–II) in 19/21 (90%) aneurysms at 1-year follow-up and two patients being retreated during follow-up.¹¹ Our study, which includes a larger series of patients, reports similar results to the multicenter CERUS study.

Historically, regarding devices used for intrasaccular flow disruption, the LUNA Aneurysm Embolization System was evaluated in a prospective multicenter study of 63 patients with 64 aneurysms.⁵ Adequate occlusion (RR I or II) was reported in 78% (46/59) of aneurysms at 12 months and 79.2% (42/53) at 36-month follow-up.⁵ It is currently not available for clinical use.

With regard to flow disruption, the WEB has been extensively studied and it is currently a well-established treatment for wide-necked intracranial aneurysms. Bhogal *et al*⁷ have reported all the data combined from WEBCAST, WEBCAST 2 and French Observatory studies^{14–16} in which 168 patients with 169 aneurysms were included. They reported adequate occlusion in 121/153 (79.1%) aneurysms at 1-year follow-up and adjunctive devices were used in 12/163 (7.4%) aneurysms. There were thromboembolic events in 24 patients (14.4%) at 1 month, with 8/24 patients being symptomatic but without clinical sequelae. All-cause mortality was 3.3%, with 3/5 deaths being unrelated to the aneurysm or the procedure.⁷

The US WEB-IT study, a prospective trial conducted at 27 centers, has reported successful deployment of the WEB in 98.7% of patients with 121/143 (84.6%) patients presenting adequate occlusion at 1-year follow-up while retreatment was performed in 14 patients (9.8%).^{7,17}

Finally, Lv *et al*,¹⁸ in their meta-analysis of 935 patients with 967 aneurysms treated with the WEB, reported a success rate for deployment of 97% (95% CI 96% to 98%) and the use of adjunctive devices in 11% (95% CI 7% to 14%) of patients, with lower rates being reported after 2013 as experience was gained. The rate of thromboembolism was 8% (95% CI 6% to 11%), with lower rates in studies published after 2013 (6%). The hemorrhagic rate was 2% (95% CI 1% to 3%). The morbidity rate was 5% (95% CI 2% to 9%) before 2013 and 1% (95% CI 0% to 2%) after 2013 with an adequate occlusion rate of 81% (95% CI 76% to 85%).

From 2012 to March 2022, we have treated in our center a total of 235 aneurysms using a flow disrupter, initially the Luna Aneurysm Embolization System and, after 2015, the WEB device.^{4,5,19} Considering the studies reported above and based on our experience, the results in our series regarding the safety and efficacy of the Contour device are comparable to those reported in the literature for the WEB. Additionally, considering the learning curve, it becomes evident that this novel device seems to be a promising treatment in intrasaccular flow disruption. This applies especially in cases where there is no WEB available for the specific dimensions of the aneurysm as well as in those where the shape of the proximal half of the aneurysm resembles the cup-like form of the Contour.

Overall, the greatest advantage of the Contour is the simple sizing approach as it targets only the proximal half and neck of the aneurysm. Consequently, the operator has to consider the neck and the widest diameter at the equatorial plane. When possible, based also on our experience with other flow disruptors, we tend to oversize the device although always respecting the sizing indications. Excessive angulation of the aneurysm in

relation to the parent artery results in a technically more challenging deployment, as in the case of the WEB.

The Contour adopts a cup-like shape when deployed, and that form is not always appropriate for complete neck occlusion in aneurysms presenting with an orthogonal proximal half as there is a risk of a residual ‘dog ear’ after deployment of the device. On the contrary, a narrowing towards the parent artery proximal half of the aneurysmal lesion is much more favorable. Additionally, the cup-like shape of the Contour can, in our experience, be an advantage in the treatment of coiled aneurysms presenting a ‘Contour-shape’ proximal recanalization and in which the targeted retreatment by coiling may be more technically challenging as well as time-consuming.

A major breakthrough for the Contour has been the improvement of the delivery system through a 0.021 inch microcatheter as it expands the feasibility of treatment. There is a similar precedent with the WEB, in which the evolution of the device and delivery system has led to an expansion of indications establishing it as a safe and effective alternative to balloon-remodeling, stent-assisted coiling, flow diversion and clipping in selected cases.¹⁹ Each of these techniques presents well-known disadvantages, with balloon remodelling being less effective and difficult for bifurcation aneurysms¹ while stent-assisted coiling and flow diversion require double antiplatelet treatment and present a risk of occlusion for covered branches.²⁰

The Contour could be initially considered an alternative to the WEB in cases in which the dimensions of the aneurysmal lesion and the shape of its neck are not favorable for the latter. As with the WEB, the Contour has the advantage of one-step occlusion of the aneurysm thus potentially limiting the time of the procedure.

With regard to antiplatelet prophylaxis in elective cases, we have applied the same protocol established in our center for the WEB device—namely, a single antiplatelet prophylactic loading dose of 250 mg aspirin immediately after deployment and oral treatment interrupted 1 month after. To our knowledge there is no consensus to premedicate patients treated electively with double antiplatelet therapy, and we consider that double antiplatelet prophylaxis has risks that do not outweigh the benefits and could possibly negatively affect the intrasaccular thrombosis. In their systematic review, Lv *et al*¹⁸ reported adjunctive techniques (remodelling, stenting or coiling) after WEB deployment in 11% of cases (95% CI 7% to 14%). In this series we applied the stent deployment rescue technique in a single case for a middle cerebral artery bifurcation aneurysm. The device presented a post-detachment protrusion on the M2 branch probably caused by excessive pre-detachment tension of the microcatheter. An Atlas stent was deployed under a loading dose of double antiplatelet therapy (aspirin and cangrelor). The stent deployment allowed the Contour to be repositioned inside the aneurysm, maintaining an excellent permeability of the artery. The patient remained under prophylactic treatment with aspirin and ticagrelor the latter interrupted after the angiographic follow-up at 3 months.

Limitations of the study

This study has several limitations. It is a single-center study and includes all the cases treated at the beginning of our learning curve. Not being randomized, it is difficult to compare with other techniques for the treatment of wide-necked aneurysms. Finally, despite being the largest study to date in the literature to the best of our knowledge, it is relatively small with mid-term follow-up.

CONCLUSION

The Contour is a safe and effective treatment of wide-necked intracranial aneurysms. In anticipation of further clinical studies, the Contour seems a valid alternative to the WEB in cases in which the dimensions of the aneurysmal lesion and the shape of its neck are not favorable for the latter. We hope that this series can contribute to the literature in the evaluation of this relatively novel device.

Twitter Guillaume Charbonnier @gcharbonnier

Contributors AB, PP and GC contributed to conception and design of the study, analysis of data and drafting the text. GC performed the statistical analysis. AB prepared the figures. All co-authors contributed to acquisition of data, provided significant input to interpretation of data, reviewed the paper and revised it for important intellectual content. AB is responsible for the overall content as guarantor.

Funding The authors have not declared a specific grant for this research from any funding agency in the public, commercial or not-for-profit sectors.

Competing interests AB received consulting fees, payments for lectures and support for attending meetings from Balt, Cerus Endovascular, Medtronic, Microvention and Stryker Neurovascular.

Patient consent for publication Not applicable.

Ethics approval This study involves human participants but Local Research Department of University Hospital approved the study. According to local legislation, approval of an Ethics Committee was not necessary. exempted this study. According to local legislation for retrospective studies, formal consent was not necessary. Every patient had written information about the use of their medical data and had the option to oppose it.

Provenance and peer review Not commissioned; externally peer reviewed.

Data availability statement Data are available upon reasonable request.

Supplemental material This content has been supplied by the author(s). It has not been vetted by BMJ Publishing Group Limited (BMJ) and may not have been peer-reviewed. Any opinions or recommendations discussed are solely those of the author(s) and are not endorsed by BMJ. BMJ disclaims all liability and responsibility arising from any reliance placed on the content. Where the content includes any translated material, BMJ does not warrant the accuracy and reliability of the translations (including but not limited to local regulations, clinical guidelines, terminology, drug names and drug dosages), and is not responsible for any error and/or omissions arising from translation and adaptation or otherwise.

ORCID iDs

Alessandra Biondi <http://orcid.org/0000-0002-3185-0740>

Guillaume Charbonnier <http://orcid.org/0000-0002-4425-3849>

REFERENCES

- Pierot L, Cognard C, Spelle L, et al. Safety and efficacy of balloon remodeling technique during endovascular treatment of intracranial aneurysms: critical review of the literature. *AJNR Am J Neuroradiol* 2012;33:12–15.
- Mokin M, Primiani CT, Ren Z, et al. Stent-assisted coiling of cerebral aneurysms: multicenter analysis of radiographic and clinical outcomes in 659 patients. *J Neurointerv Surg* 2020;12:289–97.
- Brinjikji W, Murad MH, Lanzino G, et al. Endovascular treatment of intracranial aneurysms with flow diverters: a meta-analysis. *Stroke* 2013;44:442–7.
- Pierot L, Biondi A. Endovascular techniques for the management of wide-neck intracranial bifurcation aneurysms: a critical review of the literature. *J Neuroradiol* 2016;43:167–75.
- Piotin M, Biondi A, Sourour N, et al. The LUNA aneurysm embolization system for intracranial aneurysm treatment: short-term, mid-term and long-term clinical and angiographic results. *J Neurointerv Surg* 2018;10:e34.
- Pierot L, Spelle L, Molyneux A, et al. Clinical and anatomical follow-up in patients with aneurysms treated with the web device: 1-year follow-up report in the cumulated population of 2 prospective, multicenter series (WEBCAST and French Observatory). *Neurosurgery* 2016;78:133–41.
- Bhogal P, Udani S, Cognard C, et al. Endosaccular flow disruption: where are we now? *J Neurointerv Surg* 2019;11:1024–5.
- Akhunbay-Fudge CY, Deniz K, Tyagi AK, et al. Endovascular treatment of wide-necked intracranial aneurysms using the novel contour neurovascular system: a single-center safety and feasibility study. *J Neurointerv Surg* 2020;12:987–92.
- Bhogal P, Lylyk I, Chudyk J, et al. The Contour: early human experience of a novel aneurysm occlusion device. *Clin Neuroradiol* 2021;31:147–54.
- Thormann M, Mpotsaris A, Behme D. Treatment of a middle cerebral artery bifurcation aneurysm with the novel Contour Neurovascular System compatible with 0.021" catheters. *Neuroradiol J* 2022;35:396–8.
- Liebig T, Killer-Oberpalfer M, Gal G, et al. The safety and effectiveness of the Contour Neurovascular System (Contour) for the treatment of bifurcation aneurysms: the CERUS study. *Neurosurgery* 2022;90:270–277.
- Cavasin N, Gava UA, Magrini S, et al. Treatment of a ruptured fetal-type posterior communicating aneurysm with a combined approach using the new Contour Neurovascular System. *BMJ Case Rep* 2022;15. doi:10.1136/bcr-2021-248065. [Epub ahead of print: 19 Apr 2022].
- Wodarg F, Ozpeynirci Y, Hensler J. Contour-assisted coiling with jailed microcatheter may result in better occlusion (CoCoJaMBO) in wide-necked intracranial aneurysms: proof of principle and immediate angiographic results. *Interv Neuroradiol* 2022;15910199211069782.
- Pierot L, Costalat V, Moret J, et al. Safety and efficacy of aneurysm treatment with WEB: results of the WEBCAST study. *J Neurosurg* 2016;124:1250–6.
- Pierot L, Gubucz I, Buhk JH, et al. Safety and efficacy of aneurysm treatment with the WEB: results of the WEBCAST 2 study. *AJNR Am J Neuroradiol* 2017;38:1151–5.
- Pierot L, Moret J, Turjman F, et al. WEB treatment of intracranial aneurysms: clinical and anatomic results in the French Observatory. *AJNR Am J Neuroradiol* 2016;37:655–9.
- Fiorella D, Molyneux A, Coon A, et al. Demographic, procedural and 30-day safety results from the WEB Intra-saccular Therapy Study (WEB-IT). *J Neurointerv Surg* 2017;9:1191–6.
- Lv X, Zhang Y, Jiang W. Systematic review of Woven EndoBridge for wide-necked bifurcation aneurysms: complications, adequate occlusion rate, morbidity, and mortality. *World Neurosurg* 2018;110:20–5.
- Pierot L, Biondi A, Narata A-P, et al. Should indications for WEB aneurysm treatment be enlarged? Report of a series of 20 patients with aneurysms in "atypical" locations for WEB treatment. *J Neuroradiol* 2017;44:203–9.
- Gory B, Berge J, Bonafé A, et al. Flow diverters for intracranial aneurysms: the DIVERSION national prospective cohort study. *Stroke* 2019;50:3471–80.

ICMJE DISCLOSURE FORM

Date: 6/13/2022

Your Name: Alessandra Biondi

Manuscript Title: Endosaccular Flow Disruption with the Contour Neurovascular System: Angiographic and Clinical results in a single center study of 60 unruptured intracranial aneurysms.

Manuscript Number (if known): 2022-019103.

In the interest of transparency, we ask you to disclose all relationships/activities/interests listed below that are related to the content of your manuscript. "Related" means any relation with for-profit or not-for-profit third parties whose interests may be affected by the content of the manuscript. Disclosure represents a commitment to transparency and does not necessarily indicate a bias. If you are in doubt about whether to list a relationship/activity/interest, it is preferable that you do so.

The author's relationships/activities/interests should be defined broadly. For example, if your manuscript pertains to the epidemiology of hypertension, you should declare all relationships with manufacturers of antihypertensive medication, even if that medication is not mentioned in the manuscript.

In item #1 below, report all support for the work reported in this manuscript without time limit. For all other items, the time frame for disclosure is the past 36 months.

		Name all entities with whom you have this relationship or indicate none (add rows as needed)	Specifications/Comments (e.g., if payments were made to you or to your institution)
Time frame: Since the initial planning of the work			
1	All support for the present manuscript (e.g., funding, provision of study materials, medical writing, article processing charges, etc.) No time limit for this item.	<input checked="" type="checkbox"/> None	
		<input type="text"/>	<input type="text"/>
		<input type="text"/>	<input type="text"/>
		<input type="text"/>	<input type="text"/>
		<small>Click the tab key to add additional rows.</small>	
Time frame: past 36 months			
2	Grants or contracts from any entity (if not indicated in item #1 above).	<input checked="" type="checkbox"/> None	
		<input type="text"/>	<input type="text"/>
		<input type="text"/>	<input type="text"/>
		<input type="text"/>	<input type="text"/>
3	Royalties or licenses	<input checked="" type="checkbox"/> None	
		<input type="text"/>	<input type="text"/>
		<input type="text"/>	<input type="text"/>
		<input type="text"/>	<input type="text"/>

		Name all entities with whom you have this relationship or indicate none (add rows as needed)	Specifications/Comments (e.g., if payments were made to you or to your institution)
4	Consulting fees	<input type="checkbox"/> None	
		Balt Cerus Endovascular Medtronic Microvention Stryker Neurovascular	Both Me Both Both Both
5	Payment or honoraria for lectures, presentations, speakers bureaus, manuscript writing or educational events	<input type="checkbox"/> None	
		Balt Cerus Endovascular Medtronic Microvention Stryker Neurovascular	
6	Payment for expert testimony	<input checked="" type="checkbox"/> None	
7	Support for attending meetings and/or travel	<input type="checkbox"/> None	
		Balt Cerus Endovascular Medtronic Microvention Stryker Neurovascular	
8	Patents planned, issued or pending	<input checked="" type="checkbox"/> None	
9	Participation on a Data Safety Monitoring Board or Advisory Board	<input checked="" type="checkbox"/> None	

		Name all entities with whom you have this relationship or indicate none (add rows as needed)	Specifications/Comments (e.g., if payments were made to you or to your institution)
10	Leadership or fiduciary role in other board, society, committee or advocacy group, paid or unpaid	<input checked="" type="checkbox"/> None	
11	Stock or stock options	<input checked="" type="checkbox"/> None	
12	Receipt of equipment, materials, drugs, medical writing, gifts or other services	<input checked="" type="checkbox"/> None	
13	Other financial or non-financial interests	<input checked="" type="checkbox"/> None	
<p>Please place an "X" next to the following statement to indicate your agreement:</p> <p><input checked="" type="checkbox"/> I certify that I have answered every question and have not altered the wording of any of the questions on this form.</p>			

ICMJE DISCLOSURE FORM

Date: 8/26/2021

Your Name: CHARBONNIER Guillaume

Manuscript Title: Endosaccular Flow Disruption with the Contour Neurovascular System: Angiographic and Clinical results in a single center study of 60 unruptured intracranial aneurysms.

Manuscript Number (if known): [Click or tap here to enter text.](#)

In the interest of transparency, we ask you to disclose all relationships/activities/interests listed below that are related to the content of your manuscript. "Related" means any relation with for-profit or not-for-profit third parties whose interests may be affected by the content of the manuscript. Disclosure represents a commitment to transparency and does not necessarily indicate a bias. If you are in doubt about whether to list a relationship/activity/interest, it is preferable that you do so.

The author's relationships/activities/interests should be defined broadly. For example, if your manuscript pertains to the epidemiology of hypertension, you should declare all relationships with manufacturers of antihypertensive medication, even if that medication is not mentioned in the manuscript.

In item #1 below, report all support for the work reported in this manuscript without time limit. For all other items, the time frame for disclosure is the past 36 months.

		Name all entities with whom you have this relationship or indicate none (add rows as needed)	Specifications/Comments (e.g., if payments were made to you or to your institution)
Time frame: Since the initial planning of the work			
1	All support for the present manuscript (e.g., funding, provision of study materials, medical writing, article processing charges, etc.) No time limit for this item.	<input checked="" type="checkbox"/> None	
			<small>Click the tab key to add additional rows.</small>
Time frame: past 36 months			
2	Grants or contracts from any entity (if not indicated in item #1 above).	<input checked="" type="checkbox"/> None	
3	Royalties or licenses	<input checked="" type="checkbox"/> None	

		Name all entities with whom you have this relationship or indicate none (add rows as needed)	Specifications/Comments (e.g., if payments were made to you or to your institution)
4	Consulting fees	<input checked="" type="checkbox"/> None	
5	Payment or honoraria for lectures, presentations, speakers bureaus, manuscript writing or educational events	<input checked="" type="checkbox"/> None	
6	Payment for expert testimony	<input checked="" type="checkbox"/> None	
7	Support for attending meetings and/or travel	<input checked="" type="checkbox"/> None	
8	Patents planned, issued or pending	<input checked="" type="checkbox"/> None	
9	Participation on a Data Safety Monitoring Board or Advisory Board	<input checked="" type="checkbox"/> None	
10	Leadership or fiduciary role in other board, society, committee or advocacy group, paid or unpaid	<input checked="" type="checkbox"/> None	

		Name all entities with whom you have this relationship or indicate none (add rows as needed)	Specifications/Comments (e.g., if payments were made to you or to your institution)
11	Stock or stock options	<input checked="" type="checkbox"/> None	
12	Receipt of equipment, materials, drugs, medical writing, gifts or other services	<input checked="" type="checkbox"/> None	
13	Other financial or non-financial interests	<input checked="" type="checkbox"/> None	
<p>Please place an "X" next to the following statement to indicate your agreement:</p> <p><input checked="" type="checkbox"/> I certify that I have answered every question and have not altered the wording of any of the questions on this form.</p>			

ICMJE DISCLOSURE FORM

Date: 8/26/2021

Your Name: VITALE Giovanni

Manuscript Title: Endosaccular Flow Disruption with the Contour Neurovascular System: Angiographic and Clinical results in a single center study of 60 unruptured intracranial aneurysms.

Manuscript Number (if known): [Click or tap here to enter text.](#)

In the interest of transparency, we ask you to disclose all relationships/activities/interests listed below that are related to the content of your manuscript. "Related" means any relation with for-profit or not-for-profit third parties whose interests may be affected by the content of the manuscript. Disclosure represents a commitment to transparency and does not necessarily indicate a bias. If you are in doubt about whether to list a relationship/activity/interest, it is preferable that you do so.

The author's relationships/activities/interests should be defined broadly. For example, if your manuscript pertains to the epidemiology of hypertension, you should declare all relationships with manufacturers of antihypertensive medication, even if that medication is not mentioned in the manuscript.

In item #1 below, report all support for the work reported in this manuscript without time limit. For all other items, the time frame for disclosure is the past 36 months.

		Name all entities with whom you have this relationship or indicate none (add rows as needed)	Specifications/Comments (e.g., if payments were made to you or to your institution)						
Time frame: Since the initial planning of the work									
1	All support for the present manuscript (e.g., funding, provision of study materials, medical writing, article processing charges, etc.) No time limit for this item.	<input checked="" type="checkbox"/> None <table border="1" style="width: 100%; border-collapse: collapse;"> <tr><td style="width: 50%; height: 20px;"></td><td style="width: 50%;"></td></tr> <tr><td style="height: 20px;"></td><td></td></tr> <tr><td style="height: 20px;"></td><td style="text-align: right; font-size: small;">Click the tab key to add additional rows.</td></tr> </table>						Click the tab key to add additional rows.	
	Click the tab key to add additional rows.								
Time frame: past 36 months									
2	Grants or contracts from any entity (if not indicated in item #1 above).	<input checked="" type="checkbox"/> None <table border="1" style="width: 100%; border-collapse: collapse;"> <tr><td style="width: 50%; height: 20px;"></td><td style="width: 50%;"></td></tr> <tr><td style="height: 20px;"></td><td></td></tr> <tr><td style="height: 20px;"></td><td></td></tr> </table>							
3	Royalties or licenses	<input checked="" type="checkbox"/> None <table border="1" style="width: 100%; border-collapse: collapse;"> <tr><td style="width: 50%; height: 20px;"></td><td style="width: 50%;"></td></tr> <tr><td style="height: 20px;"></td><td></td></tr> <tr><td style="height: 20px;"></td><td></td></tr> </table>							

		Name all entities with whom you have this relationship or indicate none (add rows as needed)	Specifications/Comments (e.g., if payments were made to you or to your institution)
4	Consulting fees	<input checked="" type="checkbox"/> None	
5	Payment or honoraria for lectures, presentations, speakers bureaus, manuscript writing or educational events	<input checked="" type="checkbox"/> None	
6	Payment for expert testimony	<input checked="" type="checkbox"/> None	
7	Support for attending meetings and/or travel	<input checked="" type="checkbox"/> None	
8	Patents planned, issued or pending	<input checked="" type="checkbox"/> None	
9	Participation on a Data Safety Monitoring Board or Advisory Board	<input checked="" type="checkbox"/> None	
10	Leadership or fiduciary role in other board, society, committee or advocacy group, paid or unpaid	<input checked="" type="checkbox"/> None	

		Name all entities with whom you have this relationship or indicate none (add rows as needed)	Specifications/Comments (e.g., if payments were made to you or to your institution)
11	Stock or stock options	<input checked="" type="checkbox"/> None	
12	Receipt of equipment, materials, drugs, medical writing, gifts or other services	<input checked="" type="checkbox"/> None	
13	Other financial or non-financial interests	<input checked="" type="checkbox"/> None	
<p>Please place an "X" next to the following statement to indicate your agreement:</p> <p><input checked="" type="checkbox"/> I certify that I have answered every question and have not altered the wording of any of the questions on this form.</p>			

ICMJE DISCLOSURE FORM

Date: 6/13/2022

Your Name: Panagiotis PRIMIKIRIS

Manuscript Title: Endosaccular Flow Disruption with the Contour Neurovascular System: Angiographic and Clinical results in a single center study of 60 unruptured intracranial aneurysms

Manuscript Number (if known): [Click or tap here to enter text.](#)

In the interest of transparency, we ask you to disclose all relationships/activities/interests listed below that are related to the content of your manuscript. "Related" means any relation with for-profit or not-for-profit third parties whose interests may be affected by the content of the manuscript. Disclosure represents a commitment to transparency and does not necessarily indicate a bias. If you are in doubt about whether to list a relationship/activity/interest, it is preferable that you do so.

The author's relationships/activities/interests should be defined broadly. For example, if your manuscript pertains to the epidemiology of hypertension, you should declare all relationships with manufacturers of antihypertensive medication, even if that medication is not mentioned in the manuscript.

In item #1 below, report all support for the work reported in this manuscript without time limit. For all other items, the time frame for disclosure is the past 36 months.

	Name all entities with whom you have this relationship or indicate none (add rows as needed)	Specifications/Comments (e.g., if payments were made to you or to your institution)						
Time frame: Since the initial planning of the work								
1	All support for the present manuscript (e.g., funding, provision of study materials, medical writing, article processing charges, etc.) No time limit for this item.	<input checked="" type="checkbox"/> None <table border="1" style="width: 100%; border-collapse: collapse;"> <tr><td style="width: 60%; height: 20px;"></td><td style="width: 40%;"></td></tr> <tr><td style="height: 20px;"></td><td></td></tr> <tr><td style="height: 20px;"></td><td style="text-align: right; font-size: small;">Click the tab key to add additional rows.</td></tr> </table>						Click the tab key to add additional rows.
	Click the tab key to add additional rows.							
Time frame: past 36 months								
2	Grants or contracts from any entity (if not indicated in item #1 above).	<input checked="" type="checkbox"/> None <table border="1" style="width: 100%; border-collapse: collapse;"> <tr><td style="width: 60%; height: 20px;"></td><td style="width: 40%;"></td></tr> <tr><td style="height: 20px;"></td><td></td></tr> <tr><td style="height: 20px;"></td><td></td></tr> </table>						
3	Royalties or licenses	<input checked="" type="checkbox"/> None <table border="1" style="width: 100%; border-collapse: collapse;"> <tr><td style="width: 60%; height: 20px;"></td><td style="width: 40%;"></td></tr> <tr><td style="height: 20px;"></td><td></td></tr> <tr><td style="height: 20px;"></td><td></td></tr> </table>						

		Name all entities with whom you have this relationship or indicate none (add rows as needed)	Specifications/Comments (e.g., if payments were made to you or to your institution)
4	Consulting fees	<input checked="" type="checkbox"/> None	
5	Payment or honoraria for lectures, presentations, speakers bureaus, manuscript writing or educational events	<input checked="" type="checkbox"/> None	
6	Payment for expert testimony	<input checked="" type="checkbox"/> None	
7	Support for attending meetings and/or travel	<input checked="" type="checkbox"/> None	
8	Patents planned, issued or pending	<input checked="" type="checkbox"/> None	
9	Participation on a Data Safety Monitoring Board or Advisory Board	<input checked="" type="checkbox"/> None	
10	Leadership or fiduciary role in other board, society, committee or advocacy group, paid or unpaid	<input checked="" type="checkbox"/> None	

		Name all entities with whom you have this relationship or indicate none (add rows as needed)	Specifications/Comments (e.g., if payments were made to you or to your institution)
11	Stock or stock options	<input checked="" type="checkbox"/> None	
12	Receipt of equipment, materials, drugs, medical writing, gifts or other services	<input checked="" type="checkbox"/> None	
13	Other financial or non-financial interests	<input checked="" type="checkbox"/> None	
<p>Please place an "X" next to the following statement to indicate your agreement:</p> <p><input checked="" type="checkbox"/> I certify that I have answered every question and have not altered the wording of any of the questions on this form.</p>			