



OPEN ACCESS

Original research

# Prevention of in-stent restenosis with drug-eluting balloons in patients with postirradiated carotid stenosis accepting percutaneous angioplasty and stenting

Chia-Hung Wu,<sup>1,2,3</sup> Te-Ming Lin,<sup>1,2</sup> Chih-Ping Chung,<sup>2,4</sup> Kai-Wei Yu,<sup>1,2</sup> Wei-An Tai,<sup>1,2</sup> Chao-Bao Luo,<sup>1,2,5,6</sup> Jiing-Feng Linrg,<sup>1,2</sup> Feng-Chi Chang <sup>1,2</sup>

► Additional supplemental material is published online only. To view, please visit the journal online (<http://dx.doi.org/10.1136/jnis-2022-019957>).

<sup>1</sup>Department of Radiology, Taipei Veterans General Hospital, Taipei, Taiwan

<sup>2</sup>School of Medicine, National Yang Ming Chiao Tung University, Taipei, Taiwan

<sup>3</sup>Institute of Clinical Medicine, National Yang Ming Chiao Tung University, Taipei, Taiwan

<sup>4</sup>Department of Neurology, Neurological Institute, Taipei Veterans General Hospital, Taipei, Taiwan

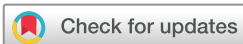<sup>5</sup>Department of Radiology, National Defense Medical Center, Taipei, Taiwan

<sup>6</sup>Department of Biomedical Engineering, Yuanpei University of Medical Technology, Hsinchu, Taiwan

## Correspondence to

Dr Feng-Chi Chang, Department of Radiology, Taipei Veterans General Hospital, Taipei, 11217, Taiwan; [fcchang374@gmail.com](mailto:fcchang374@gmail.com)

Received 6 December 2022  
Accepted 19 February 2023  
Published Online First  
13 March 2023



© Author(s) (or their employer(s)) 2024. Re-use permitted under CC BY-NC. No commercial re-use. See rights and permissions. Published by BMJ.

**To cite:** Wu C-H, Lin T-M, Chung C-P, et al. *J NeuroIntervent Surg* 2024;**16**:73–80.

## ABSTRACT

**Objective** To investigate the technical safety and outcome of in-stent restenosis (ISR) prevention with drug-eluting balloon (DEB) in patients with postirradiated carotid stenosis (PIRCS) undergoing percutaneous angioplasty and stenting (PTAS).

**Methods** Between 2017 and 2021, we prospectively recruited patients with severe PIRCS for PTAS. They were randomly separated into two groups based on endovascular techniques performed with and without DEB. Preprocedural and early postprocedural (within 24 hours) MRI, short-term ultrasonography (6 months after PTAS), and long-term CT angiography (CTA)/MR angiography (MRA), 12 months after PTAS, were performed. Technical safety was evaluated based on periprocedural neurological complications and the number of recent embolic ischemic lesions (REIL) in the treated brain territory on diffusion-weighted imaging of early postprocedural MRI.

**Results** Sixty-six (30 with and 36 without DEB) subjects were enrolled, with one failure in techniques. For 65 patients in the DEB versus conventional groups, technical neurological symptoms within 1 month (1/29 (3.4%) vs 0/36;  $P=0.197$ ) and REIL numbers within 24 hours ( $1.0\pm 2.1$  vs  $1.3\pm 1.5$ ;  $P=0.592$ ) after PTAS showed no differences. Peak systolic velocity (PSVs) on short-term ultrasonography was significantly higher in the conventional group ( $104.13\pm 42.76$  vs  $81.95\pm 31.35$ ;  $P=0.023$ ). The degree of in-stent stenosis ( $45.93\pm 20.86$  vs  $26.58\pm 8.75$ ;  $P<0.001$ ) was higher, and there were more subjects ( $n=8$ , 38.9% vs 1, 3.4%;  $P=0.029$ ) with significant ISR ( $\geq 50\%$ ) in the conventional group than in the DEB group on long-term CTA/MRA.

**Conclusions** We observed similar technical safety of carotid PTAS with and without DEBs. The number of cases of significant ISR were fewer and the degree of stenosis of ISR was less in primary DEB-PTAS of PIRCS than for conventional PTAS in the 12-month follow-up.

## INTRODUCTION

Carotid stenosis (CS) is one of the major complications after radiation therapy, which is one of the standard treatments for patients with head and neck cancer (HNC).<sup>1</sup> Previously, HNC was considered to have a higher prevalence in Asia, but recent studies revealed its increasing incidence in the United States

## WHAT IS ALREADY KNOWN ON THIS TOPIC

⇒ A drug-eluting balloon (DEB) is one of the treatment modalities in known carotid in-stent restenosis (ISR). Patients with postirradiated carotid stenosis are more likely to develop future ISR after percutaneous angioplasty and stenting (PTAS) than those with atherosclerosis.

## WHAT THIS STUDY ADDS

⇒ This is the first study to investigate and successfully demonstrate the preventive effects of DEBs in primary PTAS in patients with postirradiated carotid stenosis. The study also demonstrated similar technical safety in PTAS with and without DEBs.

## HOW THIS STUDY MIGHT AFFECT RESEARCH, PRACTICE OR POLICY

⇒ This study provided solid evidence that DEBs could effectively prevent ISR, at least within 12 months, in patients with postirradiated carotid stenosis, with safety similar to that of conventional PTAS. This finding might add the roles of DEBs in primary PTAS to prevent relatively higher rates of ISR in patients with postirradiated carotid stenosis.

and Europe.<sup>2,3</sup> Although the pathophysiologies of postirradiated carotid stenosis (PIRCS) are complicated, it is believed that endothelial dysfunction is the primary mechanism after radiation.<sup>4</sup> PIRCS may occur in unusual locations and may involve multiple segments of the carotid arteries and further create cerebral ischemic symptoms.<sup>4,5</sup>

One of two major treatments, including surgical endarterectomy and percutaneous transluminal angioplasty and stenting (PTAS), is usually performed to restore vascularization of severe CS if it is refractory to medical treatment. However, surgical endarterectomy is usually associated with higher technical risks in patients with PIRCS due to relatively more skin scarring and fibrotic tissues than other CS etiologies.<sup>1</sup> PTAS of PIRCS can effectively recanalize cerebral blood flow and reduce local turbulence, which achieves stroke prevention in these patients.<sup>6</sup> However, in-stent restenosis (ISR) after successful PTAS is especially high in patients

with PIRCS, who often require closer postprocedural surveillance.<sup>7</sup> In previous studies, researchers stated that the ISR rates were significantly higher in PIRCS (25.7%) than in CS owing to atherosclerosis (4.2%;  $P < 0.001$ ).<sup>8</sup> Furthermore, ISR was considered an independent risk factor for combined stroke and death.<sup>9</sup> Our previous study<sup>10</sup> showed that patients with PIRCS had even shorter restenosis-free survival (median time 38 months) than patients with other CS etiologies, and postirradiation itself served as a major predictor for significant restenosis ( $\geq 50\%$ ).<sup>10</sup> Previous literature indicated that the rates of significant restenosis after conventional PTAS were commonly 5.7% in most subjects at 12 months,<sup>11</sup> but 15.8% in subjects with PIRCS at 36 months.<sup>12</sup> Treatments for ISR vary, including surgical bypass, repeated PTAS, external brachytherapy, and plain or drug-eluting balloon (DEB) angioplasty.<sup>13</sup> Even though these approaches are effective in the management of ISR, patients would be exposed to additional risks of repeated management. Some patients with poor compliance during regular follow-up may have recurrent cerebral ischemic insult or stroke if their diagnosis and re-treatment are not performed in a timely manner.

A DEB is an emerging effective technique for treating ISR.<sup>14</sup> The balloon is coated with chemotherapeutic agents that prevent endothelial proliferation.<sup>14</sup> In previous studies, researchers demonstrated its potential in preventing ISR in coronary and peripheral arteries.<sup>15,16</sup> Several advanced studies indicated the safe and effective applications of DEBs in treating intracranial ISR.<sup>17,18</sup> However, primary angioplasty with DEB (PADEB)—DEB angioplasty before stenting, to prevent carotid ISR has never been discussed in the literature. In this prospective study, we aimed to evaluate the potential of PADEB in preventing ISR of PTAS of PIRCS—that is, the patient group with shorter restenosis-free survival, by comparing the safety and outcomes of the conventional and DEB techniques. An open-label study with matched groups was performed with at least 1 year of radiological and clinical follow-up after PTAS.

## METHODS

### Ethics

This study was approved by the institutional review board of our hospital (code: 2017-07-006AC & 2020-07-019ACF). The study was conducted in accordance with the Declaration of

Helsinki, and all participants provided written informed consent before enrollment.

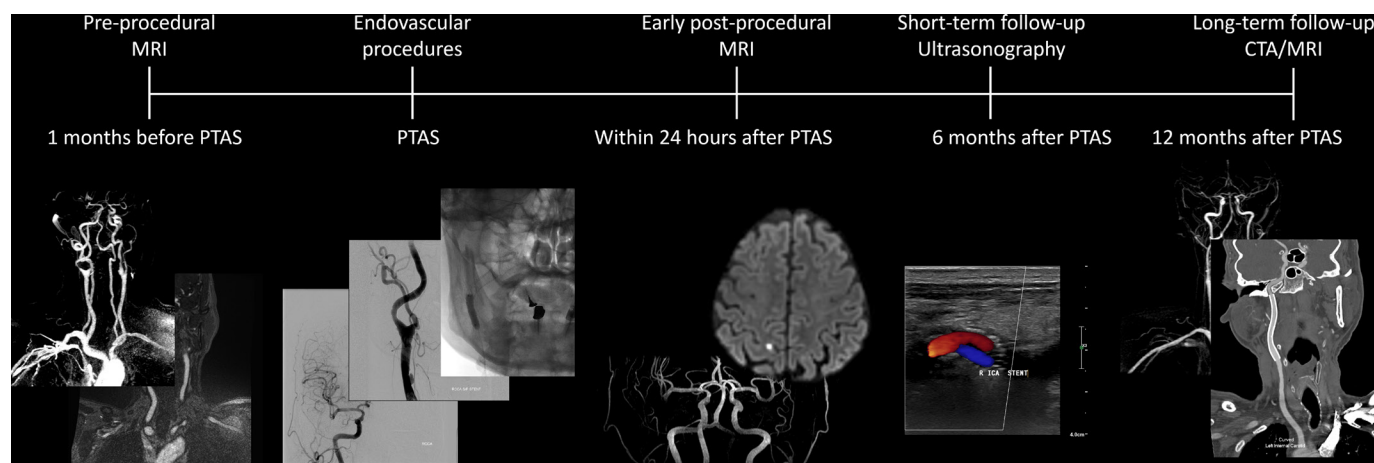
### Study subjects

Patients with HNC after radiation therapy and associated with severe PIRCS who were indicated for carotid stenting were approached in our clinics between July 2017 and July 2021. The enrolled subjects were randomly divided into two groups: PTAS with and without DEB. Patients were informed of the grouping and the procedures being performed since this was an open-label study. Subjects were informed of the potential risks of both groups before enrollment. The randomized grouping was based on the last digit of each subject's chart number since the digit was randomly distributed in our hospital. The subjects with an even number (including zero) were distributed to the conventional group (without DEB) and the odd numbers were distributed to the DEB group (with DEB).

### Imaging protocols

This study consisted of five standardized steps of imaging evaluations before and after PTAS (figure 1). Preprocedural MRI of the brain and neck, including contrast-enhanced magnetic resonance angiography (CE-MRA), was performed to confirm the diagnosis before enrollment. The endovascular procedures, described in detail in the next subsection, were then performed within 1 month after the preprocedural MRI. We performed early postprocedural MRI and MRA of the brain within 24 hours to evaluate the periprocedural technical safety by imaging. Recent embolic ischemic lesions (REILs) were defined as restricted diffusion lesions in the treated vascular territories on early postprocedural MRI regardless of the presence or absence of neurological symptoms.

The periprocedural safety was evaluated by both REILs within 24 hours and neurological complications within 1 month after PTAS. Short-term outcomes were evaluated with early postprocedural follow-up ultrasonography at 6 months. Long-term outcomes were evaluated by delayed postprocedural CT angiography (CTA) and/or contrast-enhanced MRA of the neck 1 year after PTAS.



**Figure 1** Imaging protocols in this study. Five standardized imaging evaluations were arranged in this study. Preprocedural MRI was performed, and the endovascular procedures were arranged within 1 month after the preprocedural MRI. The endovascular procedures, including percutaneous transluminal angioplasty and stenting (PTAS), were performed with preprocedural digital subtractive angiography (DSA) in the same session. Early postprocedural MRI was conducted within 24 hours after PTAS to evaluate periprocedural safety. Short-term follow-up ultrasonography was performed 6 months after PTAS, and long-term postprocedural CT angiography (CTA) and MRI were performed 12 months after PTAS.

All MRI scans (preprocedural, early postprocedural, and long-term follow-up MRI) were performed on the same 3-tesla (T) MR machine (MR750, GE Healthcare, Milwaukee, Wisconsin, USA). The preprocedural CE-MRA was a T1-based sequence with three-dimensional reformation (echo time/repetition time=1.5/5.0 ms). The slice thickness was 1.5 mm. Diffusion-weighted imaging (DWI; b value=1000, echo time/repetition time=75/5000 ms) was performed with apparent diffusion coefficient maps. Other conventional sequences, including time-of-flight MRA (echo time/repetition time=2.5/20.0 ms) and T2-weighted, fluid-attenuated inversion recovery (echo time/repetition/inversion time=95/9000/2250 ms), were also performed before administration of a gadolinium-based contrast agent to exclude other potential intracranial vascular or space-occupying lesions. The gadolinium-based contrast agent (gadobutrol, 0.1 mmol/kg) was administered (2 mL/s) via a 22-gauge intravenous catheter, followed by a 20 mL saline flush. Administration of the agent was achieved via a power injector (Optistar LE, Mallinckrodt Pharmaceuticals, Dublin, Ireland).

Follow-up ultrasonography was performed on an Aplio i800 (Canon Medical Systems Corporation). Since the DEBs had not been used in the primary PTAS before, multiple imaging modalities were planned in the follow-up periods to avoid any potential negligence of vascular and non-vascular complications. Ultrasonography was adopted owing to its characteristics of real-time vascular inspection and outstanding small part resolutions. A previous study indicated that the peak systolic velocities (PSVs) may determine the carotid ISR after PTAS. The criteria of PSVs we adopted in this study for ISR  $\geq 30\%$ ,  $\geq 50\%$ , and  $\geq 80\%$  were 154, 224, and 325 cm/s, respectively.<sup>19</sup> F-CC and C-HW performed the ultrasonographic examinations in all subjects.

Long-term follow-up CTA was performed on a CT machine (Aquillion Prime, Canon Medical Systems Corporation, Tochigi, Japan) with curved multiplanar reconstruction to clearly delineate the in-stent vascular conditions. The iodinated contrast agents were administered via a 20-gauge intravenous catheter at an injection rate of 5.0 mL/s. The bolus tracking technique was applied to optimize vascular opacification.

### Endovascular procedures

Patients with symptomatic CS  $\geq 50\%$  (stroke, transient ischemic attacks, or amaurosis fugax) or asymptomatic CS  $\geq 80\%$  were indicated for carotid PTAS. Several parameters, including degree of stenosis,<sup>20</sup> lesion length, lesion morphology (concentric vs eccentric), and laterality, were measured by digital subtraction angiography (DSA). Lesion length was defined as the distance between the proximal and distal shoulders of the stenosis. We also carefully measured the degree of stenosis on preprocedural MRI to avoid unnecessary DSA radiation to patients without proper indications. The degree of stenosis measured by DSA, served as the gold standard of stenosis in this study, and was based on the North American Symptomatic Carotid Endarterectomy Trial (NASCET) criteria.<sup>20</sup> Two experienced neurointerventionalists, F-CC and C-HW, performed all the endovascular procedures together in all subjects. The endovascular procedures were well standardized (online supplemental figure 1) and conducted on either one of the two biplane angiographic machines (Artis Q, Siemens Healthineers AG, Erlangen, Germany, and Allura Xper FD20 Biplane, Koninklijke Philips N.V., Amsterdam, Netherlands) in our hospital.

All subjects received oral premedication with dual antiplatelet therapy (300 mg aspirin and 75 mg clopidogrel daily) at least 3 days before PTAS, and the regimen was continued for 3 months

after PTAS. After 3 months, the medication was then changed to a single antiplatelet regimen (100 mg aspirin daily) indefinitely.

Subjects in the DEB group underwent general anesthesia due to prolonged intraprocedural dilatation (30–60 s) of the DEBs, while PTAS in the conventional group was conducted under local anesthesia. An intravenous bolus of 3000 to 5000 IU of heparin was administered before PTAS in all subjects to keep the active clotting time of more than 250 s. We introduced a 5-French (Fr) angiocatheter to bilateral common carotid arteries and vertebral arteries to obtain a complete DSA scan. Shuttle guiding sheath (Cook Medical, Bloomington, Indiana, USA) to target the common carotid arteries to secure the vascular route. A distal embolic protection device (FilterWire EZ, Boston Scientific Co, Middlesex County, Massachusetts, USA) was carefully introduced and deployed at the distal cervical internal carotid artery (ICA).

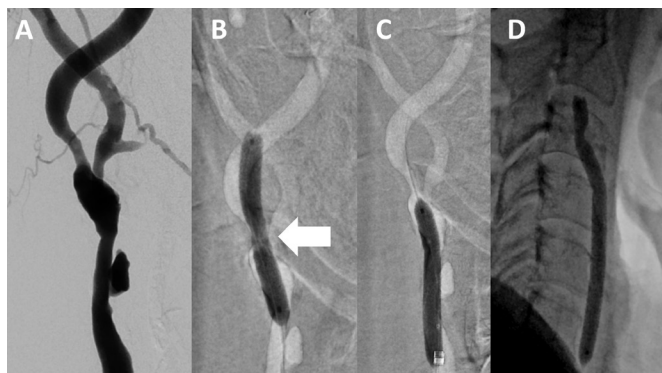
In both groups (conventional and DEB groups), all subjects underwent pre-dilatation angioplasty with a non-compliant coronary or peripheral artery balloon (EMERGE PTCA Dilatation Catheter or Sterling balloon, Boston Scientific Corporation, Middlesex County, Massachusetts, USA). The diameters of the pre-dilatation balloons were approximately 80–100% of the adjacent normal segments. In the conventional group, after pre-dilatation, carotid stents (Wallstent, Boston Scientific Co) were then meticulously deployed. In selected subjects in the conventional group, post-dilatation was performed to further dilate the diseased vessels after stenting. In the DEB group, PADEB was performed after pre-dilatation and before the carotid stent deployment. PADEB was performed with a peripheral paclitaxel-coated PTA balloon catheter (Ranger, Boston Scientific Corporation) of the same diameter as the pre-dilatation balloon. In cases with more than 95% PIRCS, we used a coronary DEB (AGENT, Boston Scientific Corporation) of smaller diameter to prevent overdilatation, which may increase the risk of hyperperfusion syndrome. AGENT is also a paclitaxel-coated DEB balloon catheter. The application of DEB after complete pre-dilatation by plain balloon catheters was to avoid incomplete drug delivery in a vascular channel that was not fully opened, which is a recommended preparation order in DEB applications in coronary artery diseases.<sup>21</sup> The length of the DEB was chosen to obtain full coverage of the stenotic carotid segments. After DEB angioplasty, carotid stents were deployed carefully. No post-dilatation was performed in any of the DEB subjects to avoid mechanical detachment of the coated drug layers. After PTAS, a control DSA scan was performed. We defined technical success as effective stent placement and  $< 30\%$  residual stenosis on the control DSA scan.

### Clinical and imaging follow-up

Clinical and imaging follow-ups were scheduled every 3–6 months after the treatment. Any recurrent neurological symptoms were recorded. All imaging analyses were performed on the picture archiving and communication system (PACS) developed in our hospital (SmartIris, version 2.1.0.11, The Taiwan Electronic Data Processing Co., Taipei, Taiwan). Since the long-term outcomes (12 months after PTAS) were evaluated by two different modalities (long-term postprocedural CTA and MRI), the degree of restenosis was defined as that with higher values. C-HW and F-CC performed the imaging analysis, and the final results were based on their consensus if discrepancies existed.

### Statistical analysis

Descriptive statistics were reported as percentages and means  $\pm$  standard deviations (SDs) or medians with interquartile ranges



**Figure 2** Technical failure due to difficult expansion of the drug-eluting balloon (DEB). An adult patient with 75.5% stenosis at the right internal carotid artery (ICA). (A) Preprocedural digital subtraction angiography revealed multisegmental stenosis from the right common carotid artery (CCA) to the ICA. Pre-dilatation was performed with a Sterling balloon (3.5×30 mm) at the (B) ICA and (C) CCA stenosis. The balloons were expanded until no narrowed waists were noted. However, a hard stenotic lesion and strong elastic recoil made the ICA stenosis not fully dilated (arrow in B) (D) The DEB failed to be introduced to the ICA owing to its significant residual stenosis by elastic recoil. We performed angioplasty with DEB in the CCA stenosis only. The case was excluded due to potential failure to deliver paclitaxel to the endothelium of ICA stenosis but was counted as technical failure in the statistics.

when appropriate. Differences in the demographics between the DEB and conventional groups were tested by  $X^2$  tests or t-tests when applicable. The number of restricted diffusions in the treated territories, the PSV differences, examination durations (operation to early MRI, follow-up ultrasonography, delayed CTA, and MRI times), and degrees of stenosis and restenosis between both groups were tested by t-tests. The inter-rater agreements of the degrees of stenosis on preprocedural MRI, preprocedural DSA, control DSA, delayed postprocedural CTA, and MRI were tested by single measures of the intraclass correlation coefficients.

All analyses were performed with the Statistical Product and Service Solutions (IBM Corporation, Armonk, New York, USA) statistics software package, version 25.0. Statistical significance in this study was defined by a P value <0.05.

## RESULTS

### Study subjects

A detailed flow diagram is shown in online supplemental figure 2. Sixty-nine patients were approached after radiation therapy. Two patients refused to enter the study, and the remaining 67 patients were enrolled for preprocedural CE-MRA. After one subject refused to continue the study, 66 subjects were separated into two groups (n=30 for the DEB group and 36 for the conventional group). Failure to complete PADEB occurred in one patient in the DEB group. This patient had focal tortuosity of the carotid bifurcation, and a very hard stenotic lesion caused elastic recoil, which made it difficult for the DEB to pass the stenotic lesions (figure 2). He was excluded from the DEB group before further analysis due to incomplete procedures but was included in the calculation of the technical success rate (65/66, 98.5%). Finally, 65 subjects after PTAS (n=29 for DEB and 36 for conventional groups) completed the early postprocedural MR and follow-up imaging studies. The number of female subjects (P=0.366), age (P=0.632), etiologies for radiation therapies (P=0.449),

stenotic locations for treatments (P=0.905), lesion lateralities (P=0.847), and ischemic symptoms before PTAS (P=0.123) were not significantly different between the groups. Detailed demographics of both groups are summarized in table 1.

### Degrees of stenosis

The differences between the conventional and DEB groups for the degrees of stenosis on preprocedural DSA (P=0.845, figures 3A and 4A) were not significant. Residual stenosis on the control DSA was  $17.69\% \pm 4.36\%$  in the conventional group (figure 3B) and  $16.46\% \pm 3.85\%$  in the DEB group (figure 4C), without significant differences (P=0.237). The intraclass correlation coefficients for stenosis measurements on preprocedural DSA, control DSA, delayed postprocedural CTA, and MRI in all subjects were 0.901, 0.892, 0.821 and 0.791, respectively.

### Periprocedural technical safety

The number of REILs on early postprocedural MR was  $1.0 \pm 2.1$  in the DEB group and  $1.3 \pm 1.5$  in the conventional group (table 2). The numbers of REILs were not different between the groups (P=0.592). One subject in the DEB group (transient ischemic attack) and none in the conventional group experienced neurological symptoms within 1 month after PTAS. No major strokes were identified in any of the subjects 1 month after PTAS.

### Short-term and long-term outcomes

The PSVs 6 months after PTAS were higher in the conventional group ( $104.13 \pm 42.76$  cm/s) than in the DEB group ( $81.95 \pm 31.35$  cm/s; P=0.023). The numbers of subjects experiencing minor stroke within 6 months were not statistically significantly different (P=0.550).

On the delayed CTA/MRI scan 12 months after PTAS the degree of restenosis was higher in the conventional group ( $45.93 \pm 20.86\%$ ; figure 3D,E) than in the DEB group ( $26.58 \pm 8.75\%$ ; P<0.001; figure 4D,E). More subjects had a significant ISR in the conventional group (8; 38.9%) than in the DEB group (1; 3.4%; P=0.029; online supplemental figure 3). Similar numbers of subjects experienced minor stroke within 12 months after PTAS (2 (6.9%) in DEB and 5 (13.9%) in conventional groups; P=0.171.) No subjects experienced major stroke within 12 months of follow-up.

## DISCUSSION

This is the first prospective study in which PADEB was applied to prevent ISR in patients with PIRCS. We compared the endovascular treatment of PIRCS between the DEB and conventional groups by assessing technical safety and outcome in a 1-year follow-up. We successfully demonstrated similar technical safety and periprocedural outcomes in both groups using clinical and MRI evaluations. We also showed significantly less ISR in those patients who underwent PIRCS with PTAS in combination with PADEB than in the patients who underwent PIRCS with conventional PTAS alone.

It was proposed that the mechanism of ISR in PIRCS was accelerated atherosclerosis, vasa vasorum injury, and potential endothelial dysfunction.<sup>10 22 23</sup> Furthermore, in previous studies, researchers discovered higher activation of nuclear factor- $\kappa$ B and oxidative stress,<sup>24 25</sup> which are considered inflammatory vascular injuries, after radiation. The combined effects of these changes and even persistent influences in the damaged vessels<sup>10</sup> after radiation therapies may contribute to the higher rates of ISR than with atherosclerosis. The mechanism of paclitaxel was mainly based on suppression of smooth muscle proliferation,<sup>26</sup> which

**Table 1** Demographics of the conventional and drug-eluting balloon groups

| Demographics  | DEB group                  | Conventional group         | P value |
|---|----------------------------|----------------------------|---------|
| Number  | 29                         | 36                         | N/A     |
| Female sex  | 0                          | 1 (2.8%)                   | 0.366   |
| Age (mean)  | 64.7±9.4 (47–88)           | 63.6±7.6 (48–78)           | 0.632   |
| NIHSS score before PTAS   | 6±2 (2–10)                 | 7±2 (0–12)                 | 0.356   |
| NIHSS score 7 days after PTAS   | 4±2 (1–8)                  | 3±1 (0–6)                  | 0.111   |
| mRS score before PTAS   | 1±1 (0–2)                  | 1±1 (0–2)                  | 0.351   |
| mRS score 7 days after PTAS   | 1±1 (0–2)                  | 1±1 (0–2)                  | 0.351   |
| Etiology for radiation therapy (nasopharyngeal or oropharyngeal cancer/larynx or hypopharyngeal cancer) | 24/5 (82.8%/17.2%)         | 27/9 (75.0%/25.0%)         | 0.449   |
| Stenotic location (ICA only/CCA only/ICA+CCA)   | 20/6/3 (69.0%/20.7%/10.3%) | 23/9/4 (63.9%/25.0%/11.1%) | 0.905   |
| Treated lesion laterality (right/left)  | 16/13                      | 19/17                      | 0.847   |
| Presence of neurological symptoms* before PTAS  | 20 (69.0%)                 | 18 (50.0%)                 | 0.123   |
| Risk factors  |                            |                            |         |
| Hypertension  | 20 (69.0%)                 | 26 (72.2%)                 | 0.774   |
| Diabetes mellitus   | 10 (34.5%)                 | 10 (27.8%)                 | 0.560   |
| Smoking   | 23 (79.3%)                 | 26 (72.2%)                 | 0.510   |
| Hyperlipidemia  | 15 (51.7%)                 | 21 (58.3%)                 | 0.594   |
| Preprocedural DSA   |                            |                            |         |
| DSA stenosis (%)  | 79.28±10.56 (60.9–94.5)    | 78.85±7.32 (65.2–94.3)     | 0.845   |
| Lesion length (cm)  | 2.77±1.74 (0.86–7.73)      | 2.40±0.95 (1.03–5.41)      | 0.286   |
| DEB diameter (mm)   | 4.93±1.20 (3.5–7)          | N/A                        | N/A     |
| DEB length (cm)   | 6.00±1.67 (3–8)            | N/A                        | N/A     |
| Postprocedural DSA and periprocedural neurological complications  |                            |                            |         |
| Residual stenosis on control DSA (%)  | 16.46±3.85 (11.6–24.1)     | 17.69±4.36 (10.4–28.4)     | 0.237   |

The degrees of stenosis were calculated based on the North American Symptomatic Carotid Endarterectomy Trial (NASCET) method.<sup>20</sup> Results are shown as number (%) or mean±SD (range).

\*Neurological symptoms before PTAS were referred to amaurosis, transient ischemic attack, or minor or major stroke.

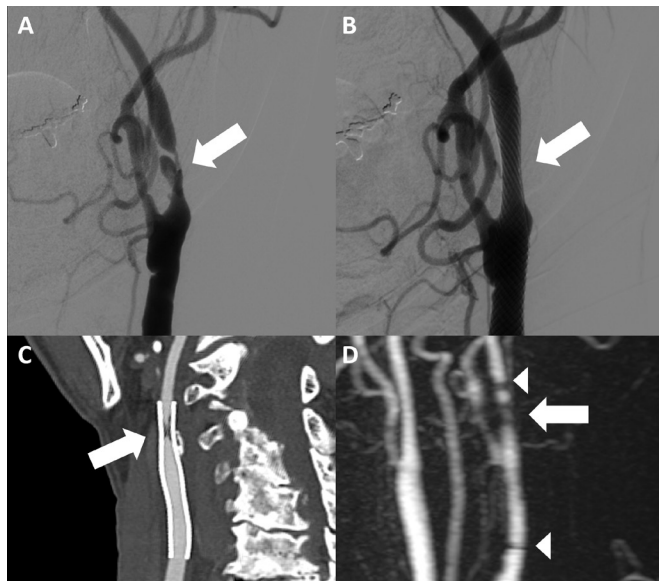
CCA, common carotid artery; DEB, drug-eluting balloon; DSA, digital subtraction angiography; ICA, internal carotid artery; mRS, modified Rankin Scale; NIHSS, National Institutes of Health Stroke Scale; PTAS, percutaneous angioplasty and stenting.

was a crucial role in ISR neointimal hyperplasia.<sup>27</sup> Suppression of vascular inflammation by paclitaxel was also reported in a recent animal study.<sup>28</sup> Furthermore, the lipophilic nature of paclitaxel may also enhance infiltration into the radiation-injured endothelium.<sup>29</sup> We speculated that these characteristics of paclitaxel may, at least partially, result in fewer cases of significant ISR in the DEB group in the 12-month follow-up in this study.

The significant ISR 12 months after PTAS was higher in the conventional group (n=8, 38.9%) than in the DEB group (n=1, 3.4%; P=0.029). This result suggested that the use of PADEB during PTAS plays a significant role in preventing or at least delaying carotid ISR in PIRCS within 1 year. Our findings were supportive of previous human<sup>15 21</sup> and animal<sup>16 30</sup> studies in which researchers focused on the primary prevention of coronary artery restenosis with DEBs, stating that DEB was effective in preventing neointimal formation and ISR.<sup>15 16 21 30</sup> The presence of an additional step of angioplasty with DEB in the DEB group compared with the conventional group did not contribute to the changes in the stenotic lumen diameters since the residual stenosis on the control DSA was similar in both groups (P=0.237). Therefore, we speculated that the relatively weak but existent mechanical force of the DEB might not have an effect, or had very little effect, on the significant differences of 6-month and 12-month outcomes between the two groups. In

fact, the mechanisms of ISR prevention by DEB were based on the antiproliferative drugs and fast delivery and sustained drug release of the drugs after direct contact.<sup>21 30</sup>

Despite the successful prevention of neointimal proliferation in coronary artery diseases, studies in which researchers focus on the prevention of ISR in PTAS of CS have never been conducted before. However, the prevention of ISR in patients with CS undergoing PTAS were of clinical significance, especially in patients with PIRCS, who had over five times more significant ISR risks than the patients with atherosclerotic CS.<sup>8</sup> Although surgical endarterectomy may be an alternative treatment for CS, it is limited by its higher technical risk for patients with PIRCS due to skin fibrosis and scarring after irradiation.<sup>1</sup> Therefore, the prevention of significant ISR of PTAS, with essentially higher rates in patients with PIRCS, is crucial. Our short-term (6 months) ultrasonographic findings were consistent with the long-term (12 months) CTA/MRA findings. PSVs in the stents were higher in the conventional group (104.13±42.76) than in the DEB group (81.95±31.35; P=0.023). Although the PSV values in both groups were not evidence of significant ISR (ISR≥50%; PSV≥224 cm/s) at 6 months,<sup>19</sup> the higher PSV in the conventional group than in the DEB group suggested that the process of focal intimal reaction/proliferation of PIRCS may start early, at least 6 months, after conventional PTAS. This

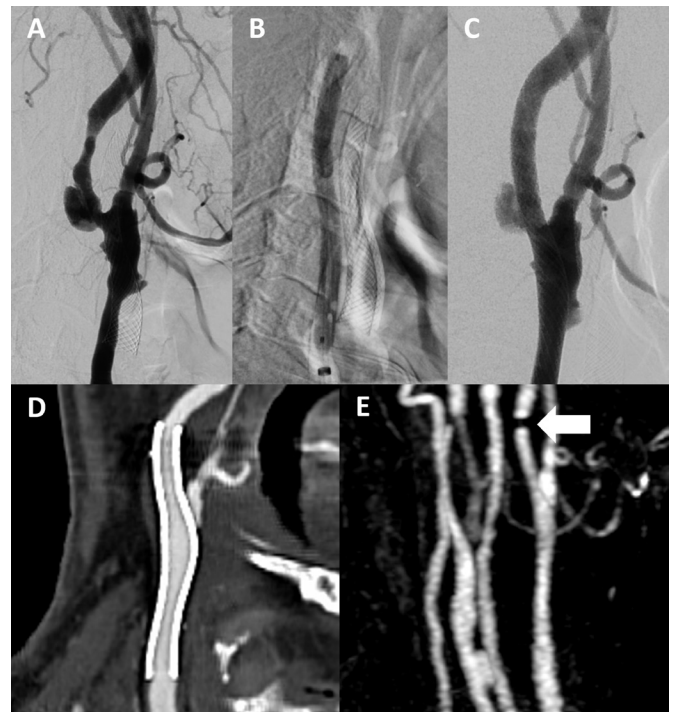


**Figure 3** Conventional group with in-stent restenosis (ISR). An adult patient with left internal carotid artery stenosis. (A) Preprocedural digital subtraction angiography (DSA) revealed a stenosis of 84.9% (arrow). (B) The control DSA demonstrated a residual 15.11%, indicating technical success ( $\leq 30\%$ ). (C) Long-term postprocedural CT angiography (CTA) with curved multiplanar construction performed 350 days after stenting revealed an ISR of approximately 83.5% (arrow). (D) Long-term postprocedural contrast-enhanced magnetic resonance angiography performed 361 days after stenting demonstrates similar high-grade ISR (arrow) to the findings on delayed postprocedural CTA. The signal cancellations at both ends of the stents were due to metallic artifacts (arrowheads).

ISR showed progressive change, becoming more apparent in a 12-month long-term follow-up. As significant ISR in the conventional group was 38.9% at the 12-month follow-up, we suggest that PTAS of PIRCS should be followed closely. These results also justified the application of PADEB in the prevention of ISR in these patients.

The periprocedural safety of PADEB was similar to that of conventional treatments. Similar REIL numbers ( $P=0.592$ ) within 24 hours and the presence of neurological symptoms ( $P=0.197$ ) at 6 months after PTAS were observed in both groups. The REILs on DWI within the first 24 hours after PTAS in this study may detect other subclinical infarction, and we believe the combined investigations of neurological symptoms and DWI numbers were more rigorous than judgments of safety by clinical symptoms alone. Overall, the rate of periprocedural neurological symptoms was 1.5% ( $n=1$  out of 65), similar to results from previous studies.<sup>31</sup>

The endovascular procedures in the DEB groups in this study were performed under general anesthesia. Although most carotid endovascular interventions were performed without general anesthesia, the prolonged expansion (30–60 s; [table 3](#)) of the DEB may cause fatal bradycardia or hemodynamic instability. Previous studies of carotid stenting found higher rates of cardiac complications and hospital stay in patients with general anesthesia.<sup>32</sup> Therefore, robust preprocedural evaluations and postprocedural care by the anesthesiologists were inevitable. The causative effects of general anesthesia on the development of hyperperfusion syndrome remain controversial.<sup>33</sup> However, with continuous arterial line monitoring of blood pressure, reperfusion injury may be more easily controlled in our experience. To



**Figure 4** Primary angioplasty with a drug-eluting balloon (DEB) for postirradiated carotid stenosis showed no evidence of in-stent restenosis (ISR). An adult patient with left internal carotid artery and common carotid artery stenosis. (A) Preprocedural digital subtraction angiography (DSA) revealed a stenosis of 79.5%. (B) DEB angioplasty was successfully performed via a 5×60 mm Ranger balloon. (C) The control DSA demonstrated a residual of 10.8%, indicating technical success ( $\leq 30\%$ ). (D) Long-term postprocedural CT angiography with curved multiplanar construction performed 366 days and (E) contrast-enhanced magnetic resonance angiography performed 367 days after stenting revealed no significant ISR. The signal cancellation at the distal end was due to metallic artifacts (arrow).

successfully deploy the antiproliferative agents onto the endothelium, in this study, general anesthesia was applied to reduce potential intolerance and fatal complications due to prolonged DEB expansion. In the conventional groups, however, we performed the procedures under local anesthesia to avoid the potentially higher rates of cardiac complications and hospital stay by general anesthesia.<sup>32</sup> The differences in the use of anesthesia were designed to keep the subjects in both groups as safe as possible. Since there were few discussions about anesthesia choices in carotid DEBs, operators may need to weigh up the different costs and benefits of different anesthetic procedures.

With prolonged angioplasty with DEB, distal emboli may occur, which may be catastrophic if the procedures are performed without protective devices. Theoretically, longer procedure durations<sup>34</sup> (30–60 s for DEBs plus usually less than 20 s<sup>35</sup> for conventional angioplasties) and more complicated steps for DEB angioplasty may result in even higher risks of distal emboli. However, REILs within 24 hours, which may overestimate the ischemic insults by detecting more subclinical infarction,<sup>36</sup> remained unchanged between the groups ( $P=0.592$ ). In view of this observation, We speculated that the use of distal protection devices might have been beneficial. Indeed, we observed dropped emboli large enough to cause middle cerebral artery infarction in some DEB subjects, and the emboli were effectively captured by the distal protection devices (online supplemental

**Table 2** Periprocedural safety and postprocedural outcomes

|  | DEB group (n=29)         | Conventional group (n=36) | P value |
|--|--------------------------|---------------------------|---------|
| Periprocedural neurological complications* (within 1 month after PTAS) | 1 (3.4%)†                | 0                         | 0.197   |
| Early postprocedural MRI within 24 hours after PTAS                    |                          |                           |         |
| Numbers of REIL‡   | 1.0±2.1 (0–8)            | 1.3±1.5 (0–7)             | 0.592   |
| Ultrasonography 6 months after PTAS (short-term outcome)               |                          |                           |         |
| PSV (cm/s)   | 81.95±31.35 (26.3–185.2) | 104.13±42.76 (50.1–301.2) | 0.023   |
| CTA/MRI 12 months after PTAS (long-term outcome)                       |                          |                           |         |
| Operation to delayed CTA/MRI time (days)                               | 364±6 (346–376)          | 363±5 (340–370)           | 0.264   |
| Delayed in-stent restenosis (%)  | 26.58±8.75 (8.8–51.0)    | 45.93±20.86 (17.1–97.4)   | < 0.001 |
| Significant in-stent restenosis (≥50%)                                 | 1 (3.4%)                 | 8 (22.2%)                 | 0.029   |

Results are shown as number (%) or mean±SD (range).  
 \*Neurological complications within 1 month after PTAS were referred to amaurosis, transient ischemic attack, or minor or major stroke.  
 †This subject experienced transient ischemic attack at 23 days after PTAS. Although the exact causes of this event were difficult to investigate, this event was counted as periprocedural neurological complications based on the common definitions (neurological events within 30 days after procedures).  
 ‡REIL was defined as restricted diffusion in the treated vascular territory of the brain parenchyma.  
 CTA, CT angiography; DEB, drug-eluting balloon; PSV, peak systolic velocity; PTAS, percutaneous angioplasty and stenting; REIL, recent embolin ischemic lesion.

figure 4). Therefore, the use of protection devices may be inevitable in DEB angioplasty.

In cases with multisegmental, hard stenotic lesions and focal tortuosity of the carotid arteries, the 0.014 inch microwire of the distal protection device (FilterWire) might not be strong enough to support passage of the DEB through the stenotic lesions (figure 2). This is especially difficult when we used a peripheral DEB (Ranger with a 0.018 inch wire system). We suggest placing the distal protection device (FilterWire) at a higher cervical-petrous level with care, and a simultaneous 0.018 inch microwire may be introduced through the stenotic lesions to straighten the vessels and to provide a route for DEB passage. Alternatively, a proximal protection device may be considered in such cases to straighten the tortuous vessels via a stiffer or thicker (0.018 inch) microwire to further allow passage of the DEB.<sup>37</sup>

Our investigations indicated that the subclinical REILs were similar in both groups with applications of embolic protection devices. Although early postprocedural MRI is not a regular follow-up modality in cases of PIRCS undergoing PTAS, it provided a solid evidence of technical feasibility and safety in the applications of DEB in the present study. We suggest applying early postprocedural MRI and MRA in those cases with a difficult approach or for operators who are not familiar with the PADEB procedures.

Our data disclosed similar periprocedural safety in both DEB and conventional groups. However, the extra interventional steps and prolonged halted vascular flow created by DEB angioplasty seemed to bring technical challenges. Previous studies have proposed the application of drug-eluting stents (DES) to prevent ISR.<sup>38–39</sup> Regardless of the suboptimal availability of

**Table 3** Technical comparison of PTAS of postirradiated carotid stenosis between DEB and conventional groups

|   | DEB group   | Conventional group  | Comments   |
|---|---|---|--|
| Anesthesia                                | General   | Local   | The balloon-inflation time of PADEB is approximately 30–60 s. Patients under local anesthesia may sometimes be intolerant to severe bradycardia and cerebral ischemia during the procedure   |
| Guiding sheath (French)                   | 6   | 6   | 90 cm, Shuttle guiding sheath (Cook Medical)   |
| Embolic protection device (FilterWire Ez) | 190/300 cm  | 190 cm  | Ranger's DEB is an over-the-wire system for peripheral vessels which accommodates a 300 cm FilterWire EZ (Boston Scientific Co.). For the coronary monorail system of AGENT DEB (Boston Scientific Co.), we used 190 cm FilterWire EZ  |
| Pre-dilatation balloon                    | Coronary or peripheral balloon system (EMERGE or Sterling balloon, Boston Sci Co.). | Coronary or peripheral balloon system (EMERGE or Sterling balloon, Boston Sci Co.). | The pre-dilatation balloon was approximately 80–100% diameter of the adjacent normal segment   |
| DEB                                       | Yes   | None  | As DEB is not used to dilate the lesions of PIRCS, we use a diameter of DEB the same as that of the pre-dilatation balloon. A peripheral DEB (Ranger) can provide adequate balloon length and diameter to cover the multisegmental, long lesions and unusual location of PIRCS (such as in CCAs). In cases of more than 95% stenosis or cases with near occlusion, we used the coronary DEB (AGENT, Boston Sci Co.) to prevent overdilatation of the target artery and to reduce the risk of hyperperfusion syndrome |
| Stents                                    | Wallstent   | Wallstent   |  |
| Post-dilatation balloon                   | None  | Conditional   | Technical success was defined as <30% residual stenosis on control DSA. For the patients with PIRCS >95% or near occlusion, we did not perform post-dilatation to reduce the risk of hyperperfusion syndrome   |

CCAs, common carotid arteries; DEB, drug-eluting balloon; PADEB, primary angioplasty with drug-eluting balloon; PIRCS, postirradiated carotid stenosis; PTAS, percutaneous angioplasty and stenting.

adequate sizes of extracranial carotid DES, these DES devices were balloon-mounted. The balloon-mounted stents were more vulnerable to compression than the self-expandable stents.<sup>40</sup> Therefore, the seemingly fewer interventional steps in DES may still create other complications in extracranial carotid arteries, which are located at a frequently movable anatomical region.

Currently, the US Food and Drug Administration (FDA) indications for AGENT DEBs are limited to coronary arteries and the FDA indications for Ranger DEBs are limited to peripheral artery diseases in the thigh and knee. Thus, the applications of both devices in the carotid angioplasty in this study were off-label. Some animal studies revealed potential distal paclitaxel embolism after use of a peripheral DEB.<sup>41,42</sup> Although the embolism profiles may not be identical for different DEBs,<sup>41</sup> and a recent human study found similar clinical outcomes for subjects with and without DEB applications,<sup>43</sup> careful patient selection and thorough explanations for patients of possible complications were necessary.

### Strengths and limitations

This study has several strengths. This is the first study in which researchers investigate the potential of DEBs for primary prevention of carotid ISR. Similar safety (both clinically and subclinically) was observed and the effects of PIRCS on the prevention of ISR was significant among the patients—that is, the patient group was relatively prone to ISR and surgical endarterectomy was relatively contraindicated. The study was performed using a sophisticated protocol, with complete and standardized imaging investigations 1 month before, within 24 hours after, 6 months after, and 12 months after PTAS. The endovascular procedures were performed in a standardized protocol in all subjects (online supplemental figure 1) by two neurointerventionalists (C-HW and F-CC) together, which eliminated potential procedure-related differences between operators. Furthermore, all the subjects underwent early postprocedural MRI within 24 hours after PTAS to examine early complications, including subclinical infarction. This has rarely been examined in previous studies. All MR examinations in this study were performed on the same 3T MR machine with the same imaging protocols.

However, this study had some limitations. Since this was an open-label study with non-blinded randomization, selection bias and observer bias cannot be completely excluded. Second, we did not perform an extra session of DSA to confirm the DSA degrees of stenosis in the early and delayed follow-up periods. Although DSA was considered the gold standard, we tended to use other non-invasive imaging modalities (ultrasonography, CTA, and CE-MRA) to reduce unnecessary diagnostic risks to the patients. Multiple non-invasive follow-up imaging modalities were used to avoid missing any potential complications. Ultrasonography was outstanding for inspection of small parts and provided real-time vascular information. CTA and MRA demonstrated clearer depiction of vascular lesions in higher anatomical positions, including lesions above spinal C2 level or mid-cervical ICA, than were shown by ultrasonography. Also, CTA and MRA were less operator-dependent than ultrasonography. However, diagnostic differences between modalities may exist.

Another important limitation was the difference in approach to the use of anesthesia in DEB (general anesthesia) and conventional (local anesthesia) groups. Although different concerns about DEB (prolonged expansion time) and conventional (general anesthesia potentially rendering more cardiac complications and a longer hospital stay)<sup>32</sup> groups in this study existed, the different choices of anesthesia in these two groups might have influenced peri-interventional outcomes.

Finally, the follow-up time after PTAS was only 12 months in this study. Since there was no consensus on the follow-up period after carotid primary DEB-PTAS, this study design adopted the alternative concepts from the reports of coronary DEBs.<sup>44,45</sup> However, delayed significant ISR in carotid arteries may occur even after 32 months,<sup>46</sup> and the ISR rates may reach a relatively stable plateau after 36 to 48 months.<sup>47</sup> Although the reported data were based on conventional carotid PTAS, we recommend a study with a longer follow-up interval of at least 48 months in the future to examine the true ISR-free survival in the DEB and conventional groups.

### CONCLUSION

We observed similar technical safety of carotid PTAS with and without DEBs. The number of cases of significant ISR and degrees of stenosis of ISR were less with primary DEB-PTAS of PIRCS than with conventional PTAS in the 12-month follow-up.

**Contributors** F-CC, C-PC, C-BL, and J-FL conceived, designed, and supervised the work. C-HW and T-ML analyzed the data. C-HW, F-CC, T-ML, K-WY, and W-AT wrote the manuscript. F-CC is responsible for the overall content as guarantor.

**Funding** This study was supported by grants from Taipei Veterans General Hospital, Taiwan (V111B-032, V112B-007 (to C-HW); V110C-037, V111C-028, V112C-059, V112D67-002-MY3-1 (to F-CC)), Veterans General Hospitals and University System of Taiwan Joint Research Program (VGHUST 109V1-5-2 and VGHUST 110-G1-5-2 (to F-CC)), Ministry of Science and Technology (National Science and Technology Council) of Taiwan (MOST 110-2314-B-075-005 and 111-2314-B-075-025-MY3 (to C-HW) and MOST 109-2314-B-075-036 and 110-2314-B-075-032 (to F-CC)), Yen Tjing Ling Medical Foundation, Taiwan [CI-109-3, CI-111-2, CI-112-2 (to C-HW)], Professor Tsuen Chang's Scholarship Program from Medical Scholarship Foundation In Memory Of Professor Albert Ly-Young Shen (to C-HW) and Vivian W Yen Neurological Foundation (to C-HW and F-CC).

**Competing interests** None declared.

**Patient consent for publication** Not applicable.

**Ethics approval** This study involves human participants and was approved by the institutional review board of Taipei Veterans General Hospital (code: 2017-07-006AC and 2020-07-019ACF). Participants gave informed consent to participate in the study before taking part.

**Provenance and peer review** Not commissioned; externally peer reviewed.

**Data availability statement** Data are available upon reasonable request.

**Supplemental material** This content has been supplied by the author(s). It has not been vetted by BMJ Publishing Group Limited (BMJ) and may not have been peer-reviewed. Any opinions or recommendations discussed are solely those of the author(s) and are not endorsed by BMJ. BMJ disclaims all liability and responsibility arising from any reliance placed on the content. Where the content includes any translated material, BMJ does not warrant the accuracy and reliability of the translations (including but not limited to local regulations, clinical guidelines, terminology, drug names and drug dosages), and is not responsible for any error and/or omissions arising from translation and adaptation or otherwise.

**Open access** This is an open access article distributed in accordance with the Creative Commons Attribution Non Commercial (CC BY-NC 4.0) license, which permits others to distribute, remix, adapt, build upon this work non-commercially, and license their derivative works on different terms, provided the original work is properly cited, appropriate credit is given, any changes made indicated, and the use is non-commercial. See: <http://creativecommons.org/licenses/by-nc/4.0/>.

### ORCID iD

Feng-Chi Chang <http://orcid.org/0000-0001-7267-6497>

### REFERENCES

- Trojanowski P, Sojka M, Trojanowska A, *et al*. Management of radiation induced carotid stenosis in head and neck cancer. *Transl Oncol* 2019;12:1026–31.
- Jakobsen KK, Grønhoj C, Jensen DH, *et al*. Increasing incidence and survival of head and neck cancers in Denmark: a nation-wide study from 1980 to 2014. *Acta Oncol* 2018;57:1143–51.
- Thompson-Harvey A, Yetukuri M, Hansen AR, *et al*. Rising incidence of late-stage head and neck cancer in the United States. *Cancer* 2020;126:1090–101.
- Hsu HM, Kuo YS, Hsu HL, *et al*. Subacute carotid stent thrombosis managed with sandwich stenting technique: a case report. *J Radiol Sci* 2019;44:173–6.



- 5 Kamtchum-Tatuene J, Noubiap JJ, Wilman AH, et al. Prevalence of high-risk plaques and risk of stroke in patients with asymptomatic carotid stenosis: a meta-analysis. *JAMA Neurol* 2020;77:1524–35.
- 6 von Reutern G-M, Goertler M-W, Bornstein NM, et al. Grading carotid stenosis using ultrasonic methods. *Stroke* 2012;43:916–21.
- 7 Protack CD, Bakken AM, Saad WE, et al. Radiation arteritis: a contraindication to carotid stenting? *J Vasc Surg* 2007;45:110–7.
- 8 Yu SCH, Zou WXY, Soo YOY, et al. Evaluation of carotid angioplasty and stenting for radiation-induced carotid stenosis. *Stroke* 2014;45:1402–7.
- 9 Wasser K, Schnaudigel S, Wohlfahrt J, et al. Clinical impact and predictors of carotid artery in-stent restenosis. *J Neurointerv Surg* 2012;259:1896–902.
- 10 Chen J-H, Wu M-H, Luo C-B, et al. Long-term imaging follow-up to evaluate restenosis in patients with carotid stenosis after angioplasty and stenting. *J Chin Med Assoc* 2021;84:87–94.
- 11 Clavel P, Hebert S, Saleme S, et al. Cumulative incidence of restenosis in the endovascular treatment of extracranial carotid artery stenosis: a meta-analysis. *J Neurointerv Surg* 2019;11:916–23.
- 12 Huang M-P, Fang H-Y, Chen C-Y, et al. Long-term outcomes of carotid artery stenting for radiation-associated stenosis. *Biomed J* 2013;36:144–9.
- 13 Huang H, Wu L, Guo Y, et al. Treatment of the carotid in-stent restenosis: a systematic review. *Front Neurol* 2021;12:748304.
- 14 Bhatia K, Akhtar IN, Akinci Y, et al. Drug-eluting balloon angioplasty for in-stent restenosis following carotid artery stent placement. *J Neuroimaging* 2020;30:267–75.
- 15 Gray WA, Granada JF. Drug-coated balloons for the prevention of vascular restenosis. *Circulation* 2010;121:2672–80.
- 16 Scheller B, Speck U, Abramjuk C, et al. Paclitaxel balloon coating, a novel method for prevention and therapy of restenosis. *Circulation* 2004;110:810–4.
- 17 Gruber P, Garcia-Esperon C, Berberat J, et al. Neuro elutax SV drug-eluting balloon versus Wingspan stent system in symptomatic intracranial high-grade stenosis: a single-center experience. *J Neurointerv Surg* 2018;10:e32.
- 18 Vajda Z, Güthe T, Perez MA, et al. Neurovascular in-stent stenoses: treatment with conventional and drug-eluting balloons. *AJNR Am J Neuroradiol* 2011;32:1942–7.
- 19 AbuRahma AF, Abu-Halimah S, Bensenhaver J, et al. Optimal carotid duplex velocity criteria for defining the severity of carotid in-stent restenosis. *J Vasc Surg* 2008;48:589–94.
- 20 Ferguson GG, Eliasziw M, Barr HW, et al. The North American Symptomatic Carotid Endarterectomy Trial: surgical results in 1415 patients. *Stroke* 1999;30:1751–8.
- 21 Jeger RV, Eccleshall S, Wan Ahmad WA, et al. Drug-coated balloons for coronary artery disease: third report of the International DCB consensus group. *JACC Cardiovasc Interv* 2020;13:1391–402.
- 22 Huang C-C, Zhou Z-Y, Huang W-M, et al. Percutaneous transluminal angioplasty and stenting of post-irradiated stenosis of subclavian artery. *J Formos Med Assoc* 2022;121:1102–10.
- 23 Huang C-C, Chiang H-F, Hsieh C-C, et al. Percutaneous transluminal angioplasty and stenting of post-irradiation stenosis of the vertebral artery. *J Neuroradiol* 2022.
- 24 Halle M, Gabrielsen A, Paulsson-Berne G, et al. Sustained inflammation due to nuclear factor-kappa B activation in irradiated human arteries. *J Am Coll Cardiol* 2010;55:1227–36.
- 25 Zhao W, Robbins MEC. Inflammation and chronic oxidative stress in radiation-induced late normal tissue injury: therapeutic implications. *Curr Med Chem* 2009;16:130–43.
- 26 Granada JF, Stenoien M, Buszman PP, et al. Mechanisms of tissue uptake and retention of paclitaxel-coated balloons: impact on neointimal proliferation and healing. *Open Heart* 2014;1:e000117.
- 27 Marx SO, Totary-Jain H, Marks AR. Vascular smooth muscle cell proliferation in restenosis. *Circ Cardiovasc Interv* 2011;4:104–11.
- 28 Chowdhury MM, Singh K, Albaghdadi MS, et al. Paclitaxel drug-coated balloon angioplasty suppresses progression and inflammation of experimental atherosclerosis in rabbits. *JACC Basic Transl Sci* 2020;5:685–95.
- 29 Sato Y, Kuntz SH, Surve D, et al. What are the pathological concerns and limitations of current drug-coated balloon technology? *Heart Int* 2019;13:15–22.
- 30 Cremers B, Speck U, Kaufels N, et al. Drug-eluting balloon: very short-term exposure and overlapping. *Thromb Haemost* 2009;101:201–6.
- 31 Kim NY, Choi JW, Whang K, et al. Neurologic complications in patients with carotid artery stenting. *J Cerebrovasc Endovasc Neurosurg* 2019;21:86–93.
- 32 Dakour-Aridi H, Rizwan M, Nejim B, et al. Association between the choice of anesthesia and in-hospital outcomes after carotid artery stenting. *J Vasc Surg* 2019;69:1461–70.
- 33 Farooq MU, Goshgarian C, Min J, et al. Pathophysiology and management of reperfusion injury and hyperperfusion syndrome after carotid endarterectomy and carotid artery stenting. *Exp Transl Stroke Med* 2016;8:7.
- 34 Napodano M, Ramondo A, Tarantini G, et al. Predictors and time-related impact of distal embolization during primary angioplasty. *Eur Heart J* 2009;30:305–13.
- 35 Mo D, Luo G, Wang B, et al. Staged carotid artery angioplasty and stenting for patients with high-grade carotid stenosis with high risk of developing hyperperfusion injury: a retrospective analysis of 44 cases. *Stroke Vasc Neurol* 2016;1:147–53.
- 36 Batool S, O'Donnell M, Sharma M, et al. Incidental magnetic resonance diffusion-weighted imaging-positive lesions are rare in neurologically asymptomatic community-dwelling adults. *Stroke* 2014;45:2115–7.
- 37 Wang D, Li Z, Zheng X, et al. Head and neck CT angiography to assess the internal carotid artery stealing pathway. *BMC Neurol* 2020;20:334.
- 38 Tekieli L, Pieniazek P, Musialek P, et al. Zotarolimus-eluting stent for the treatment of recurrent, severe carotid artery in-stent stenosis in the TARGET-CAS population. *J Endovasc Ther* 2012;19:316–24.
- 39 Gupta R, Al-Ali F, Thomas AJ, et al. Safety, feasibility, and short-term follow-up of drug-eluting stent placement in the intracranial and extracranial circulation. *Stroke* 2006;37:2562–6.
- 40 Wholey MH, Wholey MH, Tan WA, et al. A comparison of balloon-mounted and self-expanding stents in the carotid arteries: immediate and long-term results of more than 500 patients. *J Endovasc Ther* 2003;10:171–81.
- 41 Torii S, Jinnouchi H, Sakamoto A, et al. Comparison of biologic effect and particulate embolization after femoral artery treatment with three drug-coated balloons in healthy swine model. *J Vasc Interv Radiol* 2019;30:103–9.
- 42 Boitet A, Grassin-Delyle S, Louedec L, et al. An experimental study of paclitaxel embolisation during drug coated balloon angioplasty. *Eur J Vasc Endovasc Surg* 2019;57:578–86.
- 43 Fukai K, Nakagami T, Hamaoka T, et al. Clinical outcome of the patients with femoropopliteal artery disease after endovascular therapy: focused on drug-coated-balloon-related distal embolism detected by laser Doppler flowmetry. *Cardiovasc Interv Ther* 2022;37:526–32.
- 44 Liu Y, Zhang Y-J, Deng L-X, et al. 12-Month clinical results of drug-coated balloons for de novo coronary lesion in vessels exceeding 3.0 mm. *Int J Cardiovasc Imaging* 2019;35:579–86.
- 45 Baan J, Claessen BE, Dijk KB, et al. A randomized comparison of paclitaxel-eluting balloon versus everolimus-eluting stent for the treatment of any in-stent restenosis: the DARE trial. *JACC Cardiovasc Interv* 2018;11:275–83.
- 46 Kumar R, Batchelder A, Saratzis A, et al. Restenosis after carotid interventions and its relationship with recurrent ipsilateral stroke: a systematic review and meta-analysis. *Eur J Vasc Endovasc Surg* 2017;53:766–75.
- 47 Lal BK, Beach KW, Roubin GS, et al. Restenosis after carotid artery stenting and endarterectomy: a secondary analysis of crest, a randomised controlled trial. *Lancet Neurol* 2012;11:755–63.