



OPEN ACCESS

Original research

Tigertriever in the treatment of acute ischemic stroke with underlying intracranial atherosclerotic disease

Diego J Ojeda,¹ Malik Ghannam,¹ Sebastian Sanchez,¹ Mohammad Almajali,¹ Prateeka Koul,¹ Jeffrey L Saver ,² Rishi Gupta,³ Santiago Ortega-Gutierrez ,⁴ David S Liebeskind,⁵ Edgar A Samaniego ⁴

► Additional supplemental material is published online only. To view, please visit the journal online (<http://dx.doi.org/10.1136/jnis-2023-020796>).

¹Department of Neurology, University of Iowa Hospitals and Clinics, Iowa City, Iowa, USA

²Neurology and Comprehensive Stroke Center, University of California Los Angeles, Los Angeles, California, USA

³Neurosurgery, WellStar Medical Group, Marietta, Georgia, USA

⁴Departments of Neurology, Neurosurgery and Radiology, University of Iowa, Iowa City, Iowa, USA

⁵Department of Neurology, University of California Los Angeles, Los Angeles, California, USA

Correspondence to
Dr Edgar A Samaniego;
edgarsama@gmail.com

Received 12 July 2023
Accepted 10 September 2023
Published Online First
30 September 2023

ABSTRACT

Background The Tigertriever device offers a unique feature that enables gradual control of the radial expansion. We sought to evaluate the safety and efficacy of the Tigertriever device in patients with large vessel occlusion (LVO) and underlying intracranial atherosclerotic disease (ICAD). The patients were part of the TIGER trial.

Methods The presence of underlying ICAD was determined by a core imaging laboratory using CT angiography and digital subtraction angiography. The primary outcomes included successful reperfusion, puncture to reperfusion time, and complications associated with the use of the Tigertriever device. Patients underwent mechanical thrombectomy with the Tigertriever device for up to three passes, and alternative devices were employed for subsequent passes.

Results A total of 160 patients were enrolled in the TIGER trial, and 32 patients had ICAD. Among the patients with ICAD, 78% achieved successful reperfusion within three passes of the Tigertriever device, without requiring rescue therapy. Additionally, a first pass effect was observed in 46.8%. The median time from puncture to reperfusion was 22 minutes. There were no device-related complications. The National Institutes of Health Stroke Scale (NIHSS) score at 24 hours was significantly reduced, from an average of 17 at baseline to 8. At the 3 month follow-up, 50% of patients achieved a modified Rankin Scale score of ≤ 2 .

Conclusion Endovascular therapy (EVT) with the Tigertriever device for LVO in patients with underlying ICAD is effective and safe. When compared with historical data from other devices employed in similar cases, we observed a high rate of successful reperfusion, along with a shorter puncture to reperfusion time.

INTRODUCTION

Endovascular therapy (EVT) with stentriever has become the gold standard for the treatment of acute ischemic stroke (AIS) caused by large vessel occlusion (LVO).¹⁻³ However, patient-specific factors can affect the performance and outcomes of stentriever, such as the presence of underlying intracranial atherosclerotic disease (ICAD). ICAD can lead to challenges during EVT, including persistent stenosis after the procedure and the possibility of re-occlusion.⁴ Assessing the performance of stentriever specifically in patients with underlying

WHAT IS ALREADY KNOWN ON THIS TOPIC

⇒ Endovascular treatment of AIS in patients with ICAD is challenging because it is associated with a longer procedure time and higher re-occlusion rates compared with patients without ICAD.

WHAT THIS STUDY ADDS

⇒ Information about the efficacy and safety of the Tigertriever device in patients with underlying ICAD.

HOW THIS STUDY MIGHT AFFECT RESEARCH, PRACTICE OR POLICY

⇒ The Tiger stentriever may be an effective tool to achieve recanalization in patients with large vessel occlusion and underlying ICAD.

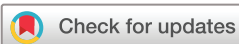ICAD is crucial for proper device selection and optimizing treatment outcomes.⁴

The Tigertriever is a unique stentriever that offers the operator the ability to manually control the radial force exerted by the device. This feature sets it apart from other stentriever available in the market.⁵ The Tigertriever device has proven to be safe and effective for the treatment of AIS.⁴⁻⁶ However, there is little published data about the performance of the Tigertriever device in patients with underlying ICAD. To address this gap in knowledge, we analyzed data from the prospective multicenter TIGER study with the aim of assessing the safety and efficacy of the Tigertriever device in patients presenting with AIS and underlying ICAD.

METHODS

Study design and data acquisition

This study is a secondary analysis of the Treatment Intent to Generate Endovascular Reperfusion (TIGER) trial. The study enrolled patients diagnosed with AIS who presented within 8 hours of the last known well time and were eligible for EVT using the Tigertriever device.⁶ Clinical data, digital subtraction angiography (DSA), and post-procedural non-contrast computed tomography (CT) scans were obtained for each patient at each participating center. All the images were analyzed by an independent core imaging laboratory consisting of blinded readers (described below). These readers assessed image quality, determined the location of



© Author(s) (or their employer(s)) 2024. Re-use permitted under CC BY-NC. No commercial re-use. See rights and permissions. Published by BMJ.

To cite: Ojeda DJ, Ghannam M, Sanchez S, et al. *J NeuroIntervent Surg* 2024;**16**:1083–1087.

occlusion, and evaluated the reperfusion rate for each pass of the Tigris retriever device. DSA images were also used to identify any post-procedural complications, such as embolization to a new territory, vessel perforation, or vessel dissection. Additionally, non-contrast CT scans were used to assess post-procedural hemorrhage at 24 hours.

The primary efficacy outcome was successful reperfusion as evaluated by the TIGER trial.⁶ Successful reperfusion was defined as a modified treatment in cerebral infarction (mTICI) score 2b-3 within three passes exclusively using the Tigris retriever device. If the patient required more than three passes, rescue therapy with an ancillary device was allowed. Furthermore, an analysis of the first pass effect in patients with ICAD was conducted. First pass effect was defined as the attainment of successful recanalization (mTICI 2b-3) using only one pass of the Tigris retriever device.⁷ Primary safety outcomes included the rate of 24-hour symptomatic hemorrhage and 90 days of good outcome, defined as a modified Rankin Scale score (mRS) of <2 points.⁶ Additionally, a historical review was performed to compare the effectiveness and safety of the Tigris retriever with other devices.

ICAD adjudication and analysis

An independent imaging core laboratory performed a secondary analysis of the TIGER trial for adjudication of underlying ICAD in the target vessel. Pre-procedure CT, CT angiography (CTA) images and procedural DSA images were reviewed independently with Horos (Annapolis, MD USA). ICAD was defined if one or more of the following criteria were present: (1) angiographic evidence of tapered-shape occlusion,⁸⁻¹⁰ (2) presence of arterial calcific lesions on non-contrast head CT and correlated angiographic changes suggestive of underlying atherosclerosis,¹¹

and/or (3) remnant stenosis >70% after mechanical thrombectomy (MT, [figure 1](#) and online supplemental figure 1).¹¹⁻¹⁴ There is a possibility of inducing vasospasm with EVT, which can sometimes be mistaken for ICAD.¹⁵ Additional areas of arterial narrowing outside the manipulated vascular territory were evaluated to ensure accurate diagnosis and to differentiate between vasospasm and the presence of underlying ICAD as the cause of arterial narrowing. This approach aimed to provide supporting evidence that the observed stenosis was indeed caused by the presence of an underlying plaque. However, if uncertainty persisted and vasospasm could not be ruled out, the area of arterial narrowing was not attributed to ICAD. Other angiographic features, such as the presence of intracranial carotid artery atherosclerotic changes, presence of multifocal narrowing and/or the presence of leptomeningeal collaterals on CT angiography strongly favored the diagnosis of ICAD.^{16,17} Four blinded reviewers (MG, SS, PK, and MA) determined the presence of an underlying plaque or atherosclerotic lesion. In case of discrepancy, a fifth senior reviewer (EAS) adjudicated cases of underlying ICAD. The anteroposterior and lateral projections of DSA images were selected to visualize the entire arterial segment. The best projection was used to obtain pre- and post-thrombectomy measurements of the occlusion site. The proximal parent vessel was also measured to assess changes in vessel caliber after the Tigris retriever device was used (online supplemental figure 2).

Statistical analysis

Statistical analyses were performed using SPSS 27 (IBM Corp, Armonk, New York, USA). The Shapiro-Wilk test was used to assess normality in each variable. Normally distributed variables were presented as mean±SD, and non-normally distributed

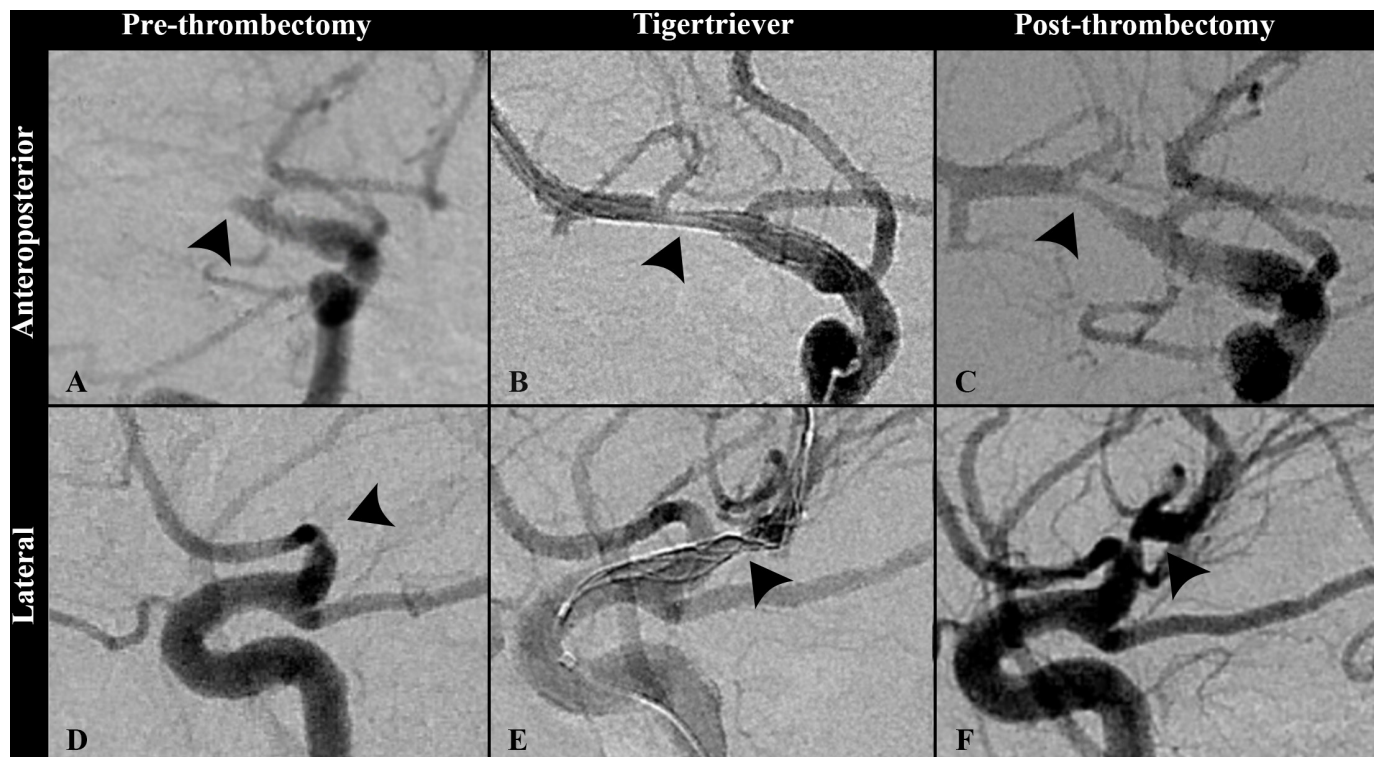


Figure 1 Mechanical thrombectomy of a patient with a right middle cerebral artery occlusion due to underlying ICAD. (A) A complete occlusion of the M1 segment of the right middle cerebral artery is observed before thrombectomy (arrowhead). (B) The Tigris retriever device is progressively deployed in the occluded vessel. (C) Successful reperfusion, TICI 3 was achieved after the first pass of Tigris retriever. Note that there is persistent stenosis at the site of occlusion due to underlying ICAD. (D) Lateral view of the occluded M1 in the same patient. (E) Underlying ICAD (arrowhead) distorts the shape of the device as it is deployed. (F) Persistent stenosis (arrowhead) due to underlying ICAD after successful reperfusion is achieved.

variables as median (interquartile range (IQR)). The Mann-Whitney *U* test was used to compare among non-normally distributed variables, whereas Student's *t*-test was used for normally distributed variables. The alpha value was set at <0.05 .

RESULTS

Patient population

We analyzed images from 160 patients who were included in the TIGER study and who had presented with ischemic strokes. Initially, 68 patients (43%) with images suggesting underlying ICAD were identified. On a more detailed review, 32 (20%) patients were identified with probable underlying ICAD. Twenty-five (15.6%) patients underwent EVT exclusively with Tigertriever. Our analysis focused on the 25 patients with ICAD exclusively treated with Tigertriever, and who did not require any rescue therapy. The mean age of these patients was 60 ± 17.5 years, and 56% were men. The mean baseline National Institutes of Health Stroke Scale (NIHSS) score was 17 ± 5 and the mean Alberta Stroke Program Early CT (ASPECT) score was 8 ± 1 . Additionally, intravenous tPA was used in 16/25 (64%) and procedural general anesthesia was used in 10/25 (40%) patients.

Procedural and clinical outcomes

Seventy-eight percent of all identified cases of ICAD achieved successful reperfusion (mTICI 2b-3) within the first three passes with the Tigertriever device. The remaining 22% of patients required adjunctive rescue therapy with other ancillary devices due to persistent occlusion. A successful reperfusion was achieved during the first pass in 15/32 (46.8%) of patients. Ninety-six percent (24/25) of the occlusions occurred in the anterior

circulation, with the middle cerebral artery being the most common location in 21/25 (84%) of cases (online supplemental table). Baseline thrombolysis in cerebral infarction (TICI) scores were 0 for 23/25 (92%) of patients and 2a for 2/25 (8%). The median (IQR) time from last known well to puncture was 184 (124.5–261) min, and the median (IQR) time from puncture to reperfusion was 22 (13.5–26.5) min.

Post-thrombectomy, there was a significant increase in the mean diameter of the arterial segment at the site of the occlusion compared with pre-thrombectomy (1.5 ± 0.73 mm vs 1.88 ± 0.67 mm, $p < 0.01$). The diameter of the parent artery proximal to the occlusion did not show a significant change after MT (2.22 ± 0.68 mm vs 2.32 ± 0.64 mm; $p = 0.34$) (figure 2).

Patients who achieved successful reperfusion with the Tigertriever device had an NIHSS score of 8 ± 7 at 24 hours post-procedure. Asymptomatic intracranial hemorrhage at 24 hours was diagnosed in 4/25 (16%) of patients. Notably, there were no additional complications, such as symptomatic intracranial hemorrhage (sICH), vessel dissection, or embolism to a new vascular territory. At the 3 month follow-up, 16/25 (64%) of patients achieved an mRS score between 0–2, indicating a good functional outcome. The overall mortality rate at the 3 month follow-up for any cause was 20% (table 1).

DISCUSSION

Our study aimed to explore the safety and efficacy of utilizing the Tigertriever device in patients with ICAD who experienced an LVO. Thirty-two patients with AIS and underlying ICAD underwent EVT using the Tigertriever device. The Tigertriever device resulted in high rates of successful reperfusion and first

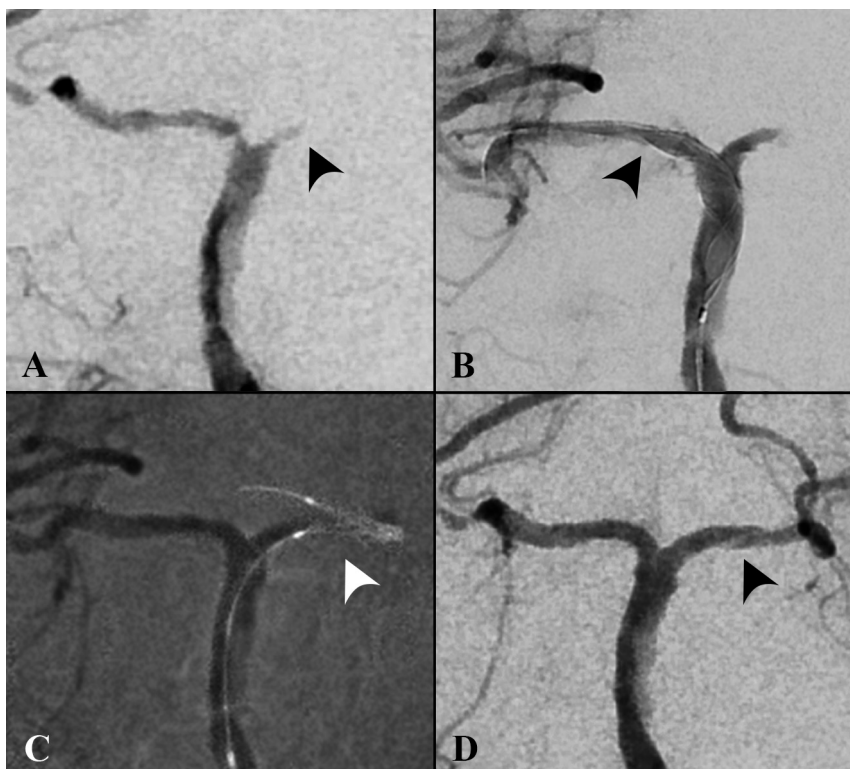


Figure 2 Basilar artery occlusion with stenosis of bilateral posterior cerebral arteries. (A) Complete occlusion of the left posterior cerebral artery (PCA), and ICAD of the contralateral PCA. (B) The device is radially adjusted and progressively deployed in the right PCA (arrowhead). (C) The Tigertriever device is then advanced and deployed in the left PCA (arrowhead) achieving reperfusion after two passes. (D) Complete reperfusion was achieved with a final TICI score of 3. Additionally, there is increased diameter of bilateral PCAs and the occluded left PCA (arrowhead) after stentoplasty with the Tigertriever device.

Table 1 Outcomes in ICAD patients treated exclusively with the Tigertriever device

Patients with successful reperfusion* within three passes and without rescue therapy N (%)	25/32 (78.1)
Last known well to puncture time, median (IQR)†	184 (124.5–261)
Puncture to reperfusion time, median (IQR)†	22 (13.5–26.5)
IV tPA n (%)	16 (64)
Baseline mTICI n (%)	
0	23 (92)
2a	2 (8)
Passes required for successful reperfusion* n (%)	
1	15 (60)
2	5 (20)
3	5 (20)
Final successful reperfusion* score within three passes n (%)	
2b	7 (28)
2c	10 (40)
3	8 (32)
Postprocedural complications	
24-hour asymptomatic hemorrhage, n (%)	4 (16)
24-hour symptomatic hemorrhage, n (%)	0
Perforation	0
Dissection	0
Embolism in new territory	0
Clinical outcomes	
NIHSS at 24-hour, $\mu \pm$ SD	8 \pm 7
90 days good outcome (mRS score 0–2) n, (%)	16 (64)
All causes of mortality at 90 days, n (%)	5 (20)

*Successful reperfusion is defined as mTICI 2b-3.
 †Expressed in minutes.
 mRS, modified Rankin Scale ; mTICI, modified treatment in cerebral infarction;
 NIHSS, National Institutes of Health Stroke Scale; SD, standard deviation; TICI, thrombolysis in cerebral infarction.

pass effect in patients with AIS and underlying ICAD. Additionally, the complication rate was negligible with no sICH, dissection, perforation, or embolism to different vascular territories.

In this sub-analysis of TIGER, the reported rate of underlying ICAD was 20%. A separate prospective registry conducted in China documented a higher incidence of ICAD at 34% among patients with LVO.¹⁸ Furthermore, various series have reported similar rates ranging from 10% to 27.9%.^{13 19–21} These differences in the prevalence of ICAD are likely influenced by variations in the criteria used to identify ICAD, inclusion of different vascular territories, as well as racial and demographic disparities among the cohorts. The primary outcome for analysis of this study, was defined as a final mTICI score of 2b-3, the same

outcome used in the TIGER trial.⁶ The rate of successful reperfusion achieved with Tigertriever was higher (78%) than what has been reported with other MT devices (28–72%).^{18 22} A comprehensive meta-analysis comprising 17 studies and 1315 patients revealed an overall recanalization rate of 88% (95% confidence interval (CI) 84 to 92%) when utilizing both MT and rescue therapy.¹⁴ However, it is worth noting that the studies included in the meta-analysis exhibited moderate to high heterogeneity and encompassed a wide array of technologies spanning from 2008 to 2018.

The Tigertriever achieved a first pass effect rate of (46.8%) in these challenging occlusions. The Tigertriever device has unique features that may contribute to its higher efficacy in patients with underlying ICAD. In contrast to most stentriever, the Tigertriever does not fully deploy on unsheathing, allowing the operator to precisely position the device through subtle movements of the pusher.^{4 23} This distinctive feature enables repetitive expansion and constriction, facilitating the incorporation of clots into the device while simultaneously performing ‘stent-plasty’. Notably, some studies suggest that patients with LVO and underlying ICAD may benefit from early angioplasty rather than delayed angioplasty after multiple passes with the stent retriever.²⁰ The observed high first pass effect described in this sub-analysis may be attributed to the ability to perform stentplasty during the initial pass. In a recent study by Li *et al* conducted in China, involving 184 patients, better 90-day outcomes were reported in patients who underwent rescue therapy compared with those treated solely with MT (mRS 0–2: 51% vs 35%). Furthermore, the rate of 24-hour re-occlusion was lower in the group that received rescue therapy (4% vs 22%). Most patients treated with rescue therapy received a tirofiban infusion (82% vs 46%), which was associated with a higher risk of hemorrhagic transformation (ICH at 24 hours was 39% vs 30%).²⁴ None of the patients in the Tigertriever study received tirofiban, and no re-occlusions at 24 hours were observed, probably due to the more durable effect of stentplasty exerted by Tigertriever. Moreover, no significant hemorrhagic complications or device-specific complications were observed. This is consistent with other studies with the Tigertriever device.⁴ One advantage of the Tigertriever device is the radiopacity of its wires, enabling visualization of the device at the time of unsheathing and during stentplasty.⁴ The position and expansion of the Tigertriever can be monitored at all times during the procedure, adding an extra layer of safety during MT. The protocol used during the TIGER trial suggested that after expanding the device in a control manner, the device can be relaxed and retrieved after approximately 2 minutes. As the operators gained experience with the device, it was recommended to “massage” the clot with repetitive expansions and relaxations of the device.

Two Tigertriever device versions were available in the TIGER study: the standard Tigertriever, which can expand up to 6 mm, and the Tigertriever 17, which can expand up to 3 mm.^{4 6} In our study, the diameter of the vessel at the site of occlusion was 1.5 \pm 0.73 mm. Notably, we observed a significant increase in

Table 2 Tigertriever compared with other devices in the treatment of patients with LVO and underlying ICAD

Author	Type of study	Sample size	Device	Reperfusion (mTICI 2b-3)	mRS \geq 2 at 90 days (%)	Puncture to Recanalization, minutes	sICH (%)
Jia <i>et al</i> ¹⁸	Retrospective	47	Solitaire	72.3%	63.8	68 (42–112)	4.3
Baek <i>et al</i> ²²	Retrospective	56	Solitaire	28.9%	46.4	73 (49–122)	5.4
TIGER	Prospective	32	Tiger	78.1%	64	22 (13.5–26.5)	0

LVO, large vessel occlusion ; mRS, modified Rankin score; sICH, symptomatic intracranial hemorrhage.

diameter at the occlusion site after stentplasty with the Tigertriever device ($p < 0.01$). This can be attributed to the high radial force generated by the device at the time of stentplasty.¹⁰ The Tigertriever device allows the operator to exert pressure on the vessel wall using the slider mechanism, resulting in a substantial radial force being applied to the vessel wall (figure 2).⁴ In vitro testing has shown that the Tigertriever device exhibits a radial force two orders of magnitude higher than self-expanding stentriever (online supplemental figure 3), but lower than percutaneous transluminal angioplasty balloons (online supplemental figure 4). This effect may explain the high first pass effect and successful recanalization rate achieved by the Tigertriever device. Patients with underlying ICAD exhibit a higher rate of re-occlusion after recanalization, which can occur in up to 65% of cases.²⁵ These patients often require additional passes and potential angioplasty. A possible trade-off of the higher radial force of the Tigertriever is the increased risk of vasospasm, which was noted in several angiograms of the study.

The higher first pass and successful reperfusion rates achieved with the Tigertriever device in patients with underlying ICAD are likely to result in a shorter overall procedure time, a shorter time from puncture to reperfusion and better clinical outcomes.²⁶ In this sub-analysis of patients with underlying ICAD, the median time from puncture to successful reperfusion was 22 minutes, with a range of 13.5–26.5 minutes. The puncture to reperfusion time of the original Tigertriever trial was 24 minutes (range: 16–38 minutes).⁵ Other studies have reported longer procedural times (table 2).

Our study has some limitations, first, most of the patients included in this cohort had occlusions in the anterior circulation, with only one patient having an occlusion in the basilar artery. Therefore, further studies are warranted to assess the safety and effectiveness of the Tigertriever device in posterior circulation occlusions due to underlying ICAD. Second, although the adjudication of underlying ICAD was performed with strict imaging criteria by a core laboratory, there is always the risk of overestimating or underestimating the prevalence of ICAD. Third, the study sample is relatively small, however it is part of the large prospectively acquired dataset of the TIGER trial. Lastly, the absence of follow-up images makes it challenging to accurately estimate the final effect of “stentplasty” in the underlying atherosclerotic plaque.

CONCLUSION

MT with the Tigertriever device for LVO patients with underlying ICAD is safe. This device provides a higher rate of successful reperfusion compared with historical studies that utilized other MT devices. Additionally, the puncture to reperfusion time was shorter with the Tigertriever device. This preliminary analysis suggests that the Tigertriever device may be effective in patients with AIS attributed to underlying ICAD.

Correction notice Since first publication, David S Liebeskind has been added as an author.

X Mohammad Almajali @mo_majali91, Santiago Ortega-Gutierrez @CerebrovasLab and Edgar A Samaniego @esamaniego

Contributors DJO: data collection and manuscript drafting. MG: data collection and manuscript drafting. SS: data collection and manuscript drafting. MA: data collection. PK: data collection. JLS: data collection. RG: data collection. SO-G: data collection. EAS: conception and design of the study, analysis and interpretation of data, drafting and revising the article. Guarantor of the study.

Funding The authors have not declared a specific grant for this research from any funding agency in the public, commercial or not-for-profit sectors.

Competing interests Dr Samaniego is a consultant for Rapid Medical.

Patient consent for publication Not applicable.

Provenance and peer review Not commissioned; externally peer reviewed.

Data availability statement Data are available upon reasonable request.

Supplemental material This content has been supplied by the author(s). It has not been vetted by BMJ Publishing Group Limited (BMJ) and may not have been peer-reviewed. Any opinions or recommendations discussed are solely those of the author(s) and are not endorsed by BMJ. BMJ disclaims all liability and responsibility arising from any reliance placed on the content. Where the content includes any translated material, BMJ does not warrant the accuracy and reliability of the translations (including but not limited to local regulations, clinical guidelines, terminology, drug names and drug dosages), and is not responsible for any error and/or omissions arising from translation and adaptation or otherwise.

Open access This is an open access article distributed in accordance with the Creative Commons Attribution Non Commercial (CC BY-NC 4.0) license, which permits others to distribute, remix, adapt, build upon this work non-commercially, and license their derivative works on different terms, provided the original work is properly cited, appropriate credit is given, any changes made indicated, and the use is non-commercial. See: <http://creativecommons.org/licenses/by-nc/4.0/>.

ORCID iDs

Jeffrey L Saver <http://orcid.org/0000-0001-9141-2251>

Santiago Ortega-Gutierrez <http://orcid.org/0000-0002-3408-1297>

Edgar A Samaniego <http://orcid.org/0000-0003-2764-2268>

REFERENCES

- Berkhemer OA, Fransen PSS, Beumer D, *et al*. A randomized trial of intraarterial treatment for acute ischemic stroke. *N Engl J Med* 2015;372:11–20.
- Saver JL, Goyal M, Bonafe A, *et al*. Stent-retriever thrombectomy after intravenous t-PA vs. t-PA alone in stroke. *N Engl J Med* 2015;372:2285–95.
- Jovin TG, Chamorro A, Cobo E, *et al*. Thrombectomy within 8 hours after symptom onset in ischemic stroke. *N Engl J Med* 2015;372:2296–306.
- Kara B, Selcuk HH, Erbahceci Salik A, *et al*. Single-center experience with the tigertriever device for the recanalization of large vessel occlusions in acute ischemic stroke. *J NeuroIntervent Surg* 2019;11:455–9.
- Gruber P, Diepers M, von Hessler A, *et al*. Mechanical thrombectomy using the new tigertriever in acute ischemic stroke patients - A Swiss prospective multicenter study. *Interv Neuroradiol* 2020;26:598–601.
- Gupta R, Saver JL, Levy E, *et al*. New class of radially adjustable stentriever for acute ischemic stroke: primary results of the multicenter TIGER trial. *Stroke* 2021;52:1534–44.
- Zaidat OO, Castonguay AC, Linfante I, *et al*. First pass effect: a new measure for stroke thrombectomy devices. *Stroke* 2018;49:660–6.
- Kim JG, Suh DC, Song Y, *et al*. Direct stenting of intracranial atherosclerosis-related acute large vessel occlusion. *Clin Neuroradiol* 2021;31:833–41.
- Garcia-Bermejo P, Patro SN, Ahmed AZ, *et al*. Baseline occlusion angiographic appearance on mechanical thrombectomy suggests underlying etiology and outcome. *Front Neurol* 2019;10:499.
- Jin X, Shi F, Chen Y, *et al*. Jet-like appearance in angiography as a predictive image marker for the occlusion of intracranial atherosclerotic stenosis. *Front Neurol* 2020;11:575567.
- Yang D, Lin M, Wang S, *et al*. Primary angioplasty and stenting may be superior to thrombectomy for acute atherosclerotic large-artery occlusion. *Interv Neuroradiol* 2018;24:412–20.
- Wu C, Chang W, Wu D, *et al*. Angioplasty and/or stenting after thrombectomy in patients with underlying intracranial atherosclerotic stenosis. *Neuroradiology* 2019;61:1073–81.
- Yoon W, Kim SK, Park MS, *et al*. Endovascular treatment and the outcomes of atherosclerotic intracranial stenosis in patients with hyperacute stroke. *Neurosurgery* 2015;76:680–6.
- Li H, Zhang Y, Zhang L, *et al*. Endovascular treatment of acute ischemic stroke due to intracranial atherosclerotic large vessel occlusion: a systematic review. *Clin Neuroradiol* 2020;30:777–87.
- Lee JS, Lee S-J, Hong JM, *et al*. Endovascular treatment of large vessel occlusion strokes due to intracranial atherosclerotic disease. *J Stroke* 2022;24:3–20.
- Tsang ACO, Lau KK, Tsang FCP, *et al*. Severity of intracranial carotid artery calcification in intracranial atherosclerosis-related occlusion treated with endovascular thrombectomy. *Clin Neurol Neurosurg* 2018;174:214–6.
- Baek J-H, Kim BM, Kim JW, *et al*. Utility of leptomeningeal collaterals in predicting intracranial atherosclerosis-related large vessel occlusion in endovascular treatment. *J Clin Med* 2020;9:2784.
- Jia B, Feng L, Liebeskind DS, *et al*. Mechanical thrombectomy and rescue therapy for intracranial large artery occlusion with underlying atherosclerosis. *J Neurointerv Surg* 2018;10:746–50.
- Lee JS, Hong JM, Lee KS, *et al*. Primary stent retrieval for acute intracranial large artery occlusion due to atherosclerotic disease. *J Stroke* 2016;18:96–101.

- 20 Deng Y, Yao Y, Tong X, *et al*. Necessity and timing of angioplasty in acute large-vessel occlusion strokes due to intracranial atherosclerotic disease: a cohort analysis with data from the angel-ACT registry. *Front Neurol* 2023;14:1087816.
- 21 Bartolini B, Krajina A, Budzik R, *et al*. Outcomes of mechanical thrombectomy of acute basilar artery occlusion due to underlying intracranial atherosclerotic disease. *SVN* 2023;3.
- 22 Baek JH, Kim BM, Heo JH, *et al*. Outcomes of endovascular treatment for acute intracranial atherosclerosis-related large vessel occlusion. *Stroke* 2018;49:2699–705.
- 23 Kara B, Selcuk HH, Yildiz O, *et al*. Revascularization of acute basilar artery occlusion using the tigertriever adjustable clot retriever. *Clin Neuroradiol* 2017;27:241–3.
- 24 Li W, Sui X, Li C, *et al*. Emergency angioplasty or stenting for stroke patients with intracranial atherosclerotic large vessel occlusion. *J Atheroscler Thromb* 2023;30:160–9.
- 25 Kang DH, Kim YW, Hwang YH, *et al*. Instant reocclusion following mechanical thrombectomy of in situ thromboocclusion and the role of low-dose intra-arterial Tirofiban. *Cerebrovasc Dis* 2014;37:350–5.
- 26 Jahan R, Saver JL, Schwamm LH, *et al*. Association between time to treatment with endovascular reperfusion therapy and outcomes in patients with acute ischemic stroke treated in clinical practice. *JAMA* 2019;322:252–63.