




OPEN ACCESS

Original research

Clinical results of 30 consecutive patients of carotid artery stenosis treated with CASPER stent placement: 1-year follow-up and in-stent findings on intravascular ultrasound examination immediately and 6 months after treatment

Hiroyuki Matsumoto , Daisuke Izawa, Hirokazu Nishiyama, Yukie Nakayama, Kazuhide Maeshima

Neurological Surgery, Kishiwada Tokushukai Hospital, Kishiwada, Osaka, Japan

Correspondence to

Dr Hiroyuki Matsumoto, Neurological Surgery, Kishiwada Tokushukai Hospital, Kishiwada, Osaka 596-8522, Japan; hiroyuki.matsumoto@tokushukai.jp

Received 8 February 2023

Accepted 14 June 2023

Published Online First

30 June 2023

ABSTRACT

Background The CASPER stent is expected to reduce periprocedural ischemic complications, but there is concern about restenosis in the early period. One-year follow-up results of CASPER stenting and findings on intravascular ultrasound (IVUS) immediately and 6 months after treatment are evaluated.

Methods Thirty consecutive patients were treated with CASPER stents for carotid artery stenosis. IVUS was performed immediately after stenting, and MRI and carotid ultrasonography were performed the next day, at 1 week, at 2 weeks, and then every 3 months. One-year follow-up results were evaluated. Twenty-five patients underwent follow-up angiography and IVUS after 6 months and their findings were investigated.

Results All patients were treated without complications during the intraoperative and periprocedural periods. After 6 months, all 25 patients with follow-up angiography and IVUS showed various degrees of intimal formation on IVUS and 8 of them had $\geq 50\%$ stenosis on angiography. Three of the 30 patients required retreatment within 6 months because of severe restenosis. In these patients, the inner layer of the stent was deformed toward the inside due to intimal hyperplasia on follow-up IVUS, and there was dissociation between the inner and outer layers. All but the 3 of 30 patients with 1-year follow-up did not lead to symptomatic cerebrovascular events or retreatment.

Conclusions The CASPER stent appears to be effective for preventing periprocedural ischemic complications. IVUS showed various degrees of intimal formation within 6 months after treatment, and it is possible that the CASPER stent is structurally prone to intimal formation or hyperplasia.

WHAT IS ALREADY KNOWN ON THIS TOPIC

⇒ The CASPER stent has been expected to reduce periprocedural ischemic complications, but there is concern about restenosis in the early period. The cause has not yet been investigated.

WHAT THIS STUDY ADDS

⇒ To investigate the cause, we observed the inner surface of the stent with intravascular ultrasound (IVUS) at the 6-month follow-up.

HOW THIS STUDY MIGHT AFFECT RESEARCH, PRACTICE OR POLICY

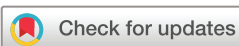⇒ According to the IVUS findings, the dual-layer structure of the CASPER stent may have a structurally weak contact between the inner and outer layers. Careful follow-up for restenosis is necessary in the future.

preventing periprocedural plaque protrusion and distal embolism, but the frequency of restenosis of closed-cell stents due to intimal hyperplasia at follow-up is higher than that of open-cell stents because of poor apposition to the vascular wall.¹⁻³ The CASPER stent (Terumo Co., Tokyo, Japan) is a unique, all-metal, micromesh stent with a low-profile, dual-layer structure. The CASPER stent has the properties of preventing plaque protrusion and embolism in the periprocedural period while maintaining good apposition to the vascular wall.⁴⁻⁷ According to a recent systematic review and meta-analysis, outcomes at 30 days were significantly improved by some types of second-generation dual-layer stents (SGS) compared with conventional first-generation stents (FGS).⁸ However, individual SGS significantly varied in their performance as regard ipsilateral stroke and in-stent restenosis at 12 months. It has also been reported that the CASPER stent has a higher rate of restenosis than other SGS despite its similar dual-layer structure.

A total of 30 consecutive patients with carotid artery stenosis treated with the CASPER stent were retrospectively investigated. The results from the periprocedural period to 1 year are presented, and

INTRODUCTION

In carotid artery stenting (CAS), the development of various protective devices and techniques has made it possible to prevent intraoperative ischemic complications. However, some issues still remain regarding periprocedural plaque protrusion and restenosis during early to long-term follow-up. It has been reported that closed-cell stents are more effective than open-cell stents in



© Author(s) (or their employer(s)) 2024. Re-use permitted under CC BY-NC. No commercial re-use. See rights and permissions. Published by BMJ.

To cite: Matsumoto H, Izawa D, Nishiyama H, et al. *J NeuroIntervent Surg* 2024;**16**:715–720.

the mechanism of restenosis in the CASPER stent was considered based on findings of intimal proliferation on the surface of the stent observed by intravascular ultrasound (IVUS).

METHODS

Subjects

From February 2021 to June 2022, 30 consecutive patients with carotid artery stenosis were treated with the CASPER stent. The background and lesion characteristics of these 30 patients are shown in [table 1](#). The study included 24 men (80%), and the patients' mean age was 74 (range 62–87) years. Seventeen patients had asymptomatic lesions, and 13 patients had symptomatic lesions (transient ischemic attack (TIA) 2 patients, minor stroke 10 patients, major stroke 1 patient). The average stenosis rate measured by the North American Symptomatic Carotid Endarterectomy Trial method⁹ was 77.8%, and the plaques were fibrous plaques in 10 patients, soft plaques in 19 patients, and calcified plaques in 1 patient.

Procedure and management

At our institution, routine MRI, magnetic resonance angiography (MRA) including intracranial and carotid arteries, MRI plaque imaging (black-blood method), carotid ultrasonography, and diagnostic angiography are routinely performed before CAS. CAS was performed according to previously reported indication criteria: $\geq 50\%$ symptomatic stenosis on angiography resulting in ischemic stroke, TIA, or $\geq 70\%$ asymptomatic stenosis on angiography.^{10 11} We also referred to carotid ultrasonography with peak systolic velocity (PSV) 130 and 230 cm/s indicating 50% and 70% stenosis, respectively.

Dual antiplatelet therapy (DAPT) was started 1 week before treatment. After treatment, DAPT was continued for 3 months and then reduced to single antiplatelet therapy.

In order to prevent intraoperative distal embolism, distal protection with Filterwire EZ (Stryker, Fremont, CA, USA) was basically performed, but depending on the characteristics of the plaque, distal balloon protection with Carotid Guard-Wire PS (Medtronic, Irvine, CA, USA) and proximal protection with a reversal flow system were performed as needed. Pre-dilatation was first performed on the stenotic lesion with percutaneous transluminal angioplasty (PTA) balloon, then the stent was placed, and post-dilatation was routinely added with a PTA balloon inside the stent. Immediately after stent placement, IVUS was performed to evaluate plaque protrusion and incomplete stent apposition (ISA). AltaView and VISICUBE (Terumo Co., Tokyo, Japan) were used for IVUS studies, with settings of 60 MHz, 90 frames/s, and pullback speed of 9 mm/s. To avoid the artifact due to blood-speckled reflections, saline was injected manually through the guiding catheter into the carotid artery at about 5 mL/s under flow arrest using a balloon guiding catheter during IVUS recording (negative contrast method).¹²

To investigate delayed plaque protrusion and periprocedural ischemic complications, MRI including diffusion-weighted imaging (DWI) and carotid ultrasonography were performed on the day after CAS, 1 week after CAS, and 2 weeks after CAS. After that, both MRI and carotid ultrasonography were performed at 3–6 months, 7–11 months, and about 12 months after CAS at outpatient examination to investigate cerebrovascular events or restenosis.

About 6 months after treatment, follow-up angiography and IVUS were performed, and in-stent restenosis and intimal proliferation on the inner surface of the stent were evaluated. In the evaluation of IVUS, the width from the stent mesh surface to

Table 1 Background and lesion characteristics of the 30 patients investigated

Characteristic (N=30)	Value
Age (years), mean \pm SD	74.1 \pm 5.9
Male, n (%)	25 (83.3)
Site left/right, n (%)	18 (60.0)/12 (40.0)
Hypertension, n (%)	29 (96.7)
Dyslipidemia, n (%)	21 (70.0)
Diabetes mellitus, n (%)	9/30 (30.0)
Smoking, n (%)	12 (40.0)
Total cholesterol (mg/dL), mean \pm SD	177.7 \pm 32.2
LDL-cholesterol (mg/dL), mean \pm SD	102.8 \pm 31.8
Atherogenic index, mean \pm SD	2.8 \pm 1.4
Triglycerides (mg/dL), mean \pm SD	133.3 \pm 72.2
Symptomatic, n (%)	13 (43.3)
Plaque imaging	
Soft plaque, n (%)	19 (63.3)
Fibrous plaque, n (%)	10 (33.3)
Calcified plaque, n (%)	1 (3.3)
Stenosis (%), mean \pm SD	77.8 \pm 9.1
LDL, low-density lipoprotein; SD, standard deviation.	

the inner surface of the intima at the thickest part of the intimal proliferation in the stent was measured, and its value was defined as the maximum intimal thickness (MIT). We distinguished the dual-layer part of the stent into three portions, namely the distal, middle, and proximal portions, and examined in which portion MIT had been included.

During the follow-up, if the patient developed a symptomatic cerebrovascular event (major or minor stroke, TIA) with restenosis (defined as $\geq 50\%$ stenosis on angiography), we performed retreatment for restenosis. If restenosis showed $\geq 70\%$ on angiography or PSV ≥ 300 cm/s on carotid ultrasonography, we performed additional treatments even for asymptomatic restenosis.

This study received ethical approval from our institutional ethics committee with the use of an opt-out method for consent.

RESULTS

Intraoperative and periprocedural period

In all patients, the stenosis improved with no intraoperative complications, and the average stenosis rate was decreased to 31.9%. The CASPER stents used were 8–20 mm in 2 patients, 8–25 mm in 3 patients, 8–30 mm in 6 patients, 9–20 mm in 3 patients, 9–30 mm in 11 patients, 10–20 mm in 2 patients, and 10–30 mm in 3 patients ([table 2](#)).

Intraoperative IVUS showed plaque protrusion in nine patients. In two of them, angiography also showed plaque protrusion. One of the two patients with plaque protrusion on angiography was treated with additional CASPER stent placement because of a mobile plaque, and the plaque disappeared. The other patient had no additional treatment and was followed up. Neither of them had any periprocedural ischemic complications. ISA was observed in eight patients by intraoperative IVUS. In all 8 patients, ISA was found in the distal portion of the dual-layer part of the stent; post-dilatation with a PTA balloon was added again in 3 of these 8 patients of them, and the others were followed up. Bradycardia and hypotension were observed in 14

Table 2 Procedural and clinical results after stenting

Intraoperative and perioperative period (N=30)	Value
Balloon/artery ratio (pre-dilatation), mean±SD	66.7±7.6
Balloon/artery ratio (post-dilatation), mean±SD	86.5±9.0
Plaque protrusion detected by IVUS, n (%)	9 (30.0)
Plaque protrusion detected by angiography, n (%)	2 (6.7)
Maximum residual stenosis diameter (mm), mean±SD	3.7±0.5
Residual stenosis ratio (%), mean±SD	31.9±9.1
Portion with ISA on IVUS, n (%)	
Distal portion of the dual-layer part, n (%)	8 (26.7)
Middle portion of the dual-layer part, n (%)	0 (0)
Proximal portion of the dual-layer part, n (%)	0 (0)
Bradycardia and hypotension, n (%)	14 (46.6)
Asymptomatic hyperintensity detected by DWI, n (%)	10 (33.3)
Cerebrovascular event, n (%)	1 (3.3)
Follow-up after 6 months (N=25)	
Restenosis ≥50% on angiography, n (%)	8 (26.7)
Portion with MIT on IVUS	
Distal portion of the dual-layer part, n (%)	0 (0)
Middle portion of the dual-layer part, n (%)	19 (76.0)
Proximal portion of the dual-layer part, n (%)	6 (24.0)
Dissociation between the dual layers on IVUS	12 (40.0)
Cerebrovascular event, n (%)	1 (3.3)
Retreatment, n (%)	3 (10.0)

DWI, diffusion-weighted imaging; ISA, incomplete stent apposition; IVUS, intravascular ultrasound; MIT, maximum intimal thickness; SD, standard deviation.

patients during the procedure, and 3 of them required treatment with atropine or vasopressors.

DWI on the day after CAS showed asymptomatic hyperintensity lesions in 10 patients, who were all followed up. Carotid ultrasonography on the day after CAS showed no obvious plaque protrusion. One symptomatic cerebral infarction in the ipsilateral cortical branch was found on DWI 1 week after the procedure, but no additional treatment was given, and medical treatment was provided. Carotid ultrasonography 1 week after the procedure showed no obvious plaque protrusion. No new cerebral infarction or plaque protrusion was observed on both DWI and carotid ultrasonography 2 weeks after the procedure.

Follow-up 6 months after treatment

In 25 of the 30 patients, informed consent was obtained for follow-up angiography and IVUS after 6 months (table 2).

Eight of the 25 patients showed ≥50% on angiography. On IVUS examination, various degrees of intimal formation had already occurred on the inner surface of the dual-layer part of the stent in all 25 patients. The MIT was found in the middle portion of the dual-layer part of the CASPER stent in 19 of 25 patients, where it almost corresponded to the original stenotic region. Intimal formation was also seen between the inner and outer layers of the dual-layer part. Dissociation of the dual-layer part was observed in 12 of 25 patients.

Three of the 25 patients required retreatment. They showed ≥70% stenosis on angiography and PSV ≥300 cm/s on carotid ultrasonography. One patient had symptomatic stenosis with minor cerebral infarction and two patients had asymptomatic stenosis. In three patients who underwent retreatment, IVUS showed that the inner layer was pushed inward and deformed by the intimal proliferation, and then severe dissociation occurred between the inner and outer layers of the stent due to intimal hyperplasia (figure 1). All three

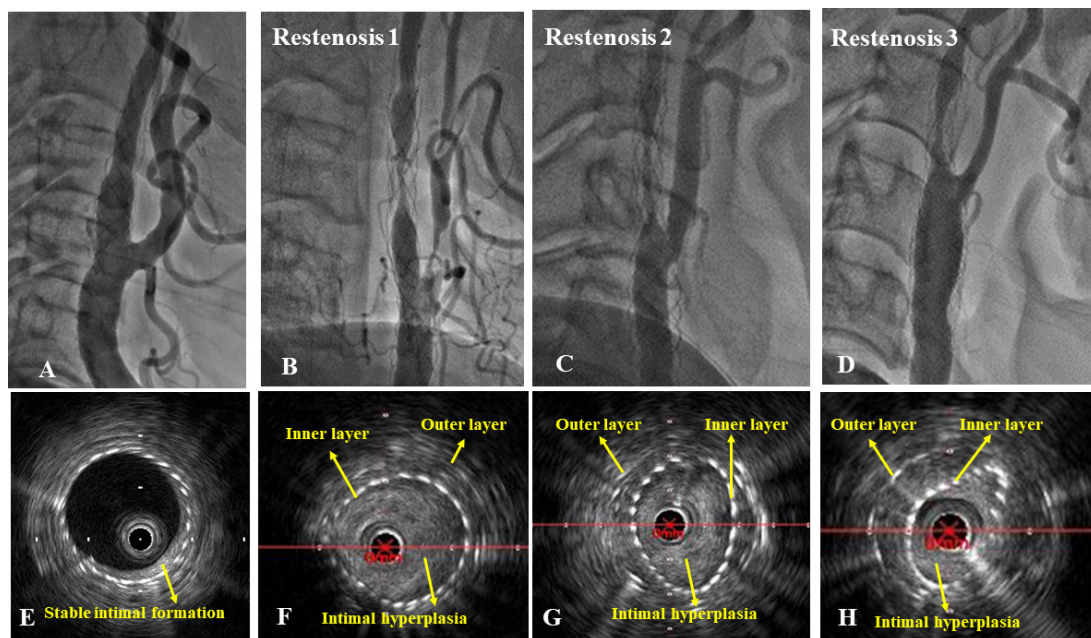


Figure 1 Good progress case (A,E). Follow-up angiography 6 months after carotid artery stenting (CAS) showing good dilatation of the stent. Intravascular ultrasound (IVUS) showing intimal formation of appropriate thickness on the inner surface of the stent. Restenosis cases (case 1: B and F, case 2: C and G, case 3: D and H). Follow-up angiography 6 months after CAS showing severe restenosis (B,C,D). IVUS findings at the narrowest portion showing that intimal proliferation is observed between the inner and outer layers of the stent, and the inner layer is dissociated from the outer layer due to intimal hyperplasia (F,G,H) and deformed (G,H).

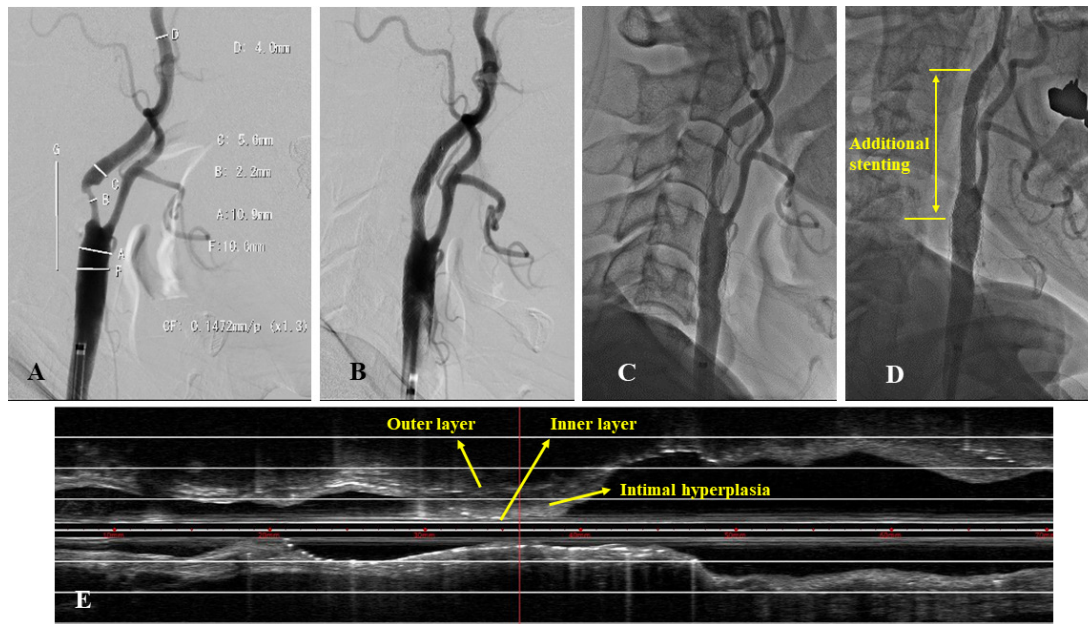


Figure 2 Case of restenosis 3 in figure 1. An adult patient presenting with symptomatic minor stroke underwent carotid artery stenting (CAS) using the CASPER stent (10–30 mm) for 75% stenosis of soft plaque (A). Angiography immediately after CAS showing good patency of the CASPER stent (B). Follow-up angiography after 6 months showing severe restenosis (C). Stent placement was performed with a precise stent (10–40 mm) (Johnson & Johnson, New Brunswick, NJ, USA) (between the yellow lines) for restenosis (D). Intravascular ultrasound (IVUS) after 6 months showing that the inner and the outer layers of the stent are dissociated due to intimal hyperplasia, and the inner layer is partially deformed (E).

patients were retreated with PTA and additional stenting with a conventional open-cell stent (figure 2).

Follow-up 1 year after treatment

Figure 3 shows the progression of PSV values on follow-up carotid ultrasonography from the periprocedural period to 1 year after treatment. There were no cerebrovascular events or restenosis on carotid ultrasonography and MRI from 6 months to 1 year after treatment.

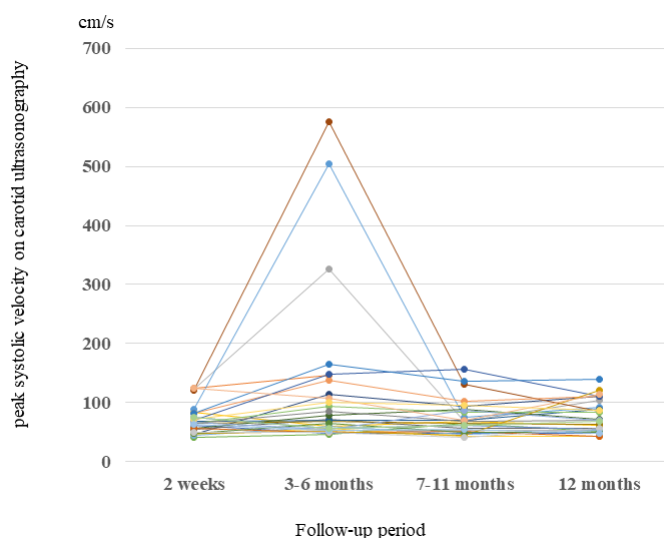


Figure 3 Peak systolic velocity (PSV) of carotid ultrasonography during the 1-year follow-up. Three patients who underwent retreatment had PSV ≥ 300 cm/s within 6 months, but PSV decreased and remained stable in those patients after treatment. No other patient had PSV ≥ 300 cm/s during the 1-year follow-up.

DISCUSSION

In this study, intraprocedural IVUS examination and angiography detected asymptomatic plaque protrusion in nine and two patients respectively, and there was one symptomatic ischemic lesion detected by DWI within 1 week after treatment. Three patients required retreatment within 6 months because of restenosis with severe intimal hyperplasia. IVUS examination revealed the following points. (1) Immediately after CASPER stent placement, ISA occurred at the distal portion of the dual-layer part due to weak contact between the inner and outer layers of the stent. (2) Various degrees of intimal formation have already occurred in all patients 6 months after CAS. (3) Intimal proliferation is observed between the inner and outer layers of the stent. (4) In some findings, the inner layer is deformed and dissociated from the outer layer due to intimal hyperplasia. These findings cannot be detected with angiography. To the best of our knowledge, there have been no reports of observing the appearance of the vascular lumen by IVUS 6 months after CAS.

Yamada *et al*¹³ observed plaque protrusion immediately after CASPER stent placement in 46 consecutive patients with soft plaque using optical coherence tomography, and they compared the degree of plaque protrusion with that of conventional stents. They found that the CASPER stent has a significantly smaller amount of protruding plaque, and prevention of plaque protrusion can be expected. Conversely, it has been pointed out that the rate of in-stent restenosis of SGS tends to be higher than that of conventional stents after 1 year. Sýkora *et al*¹⁴ reported that dual-layer stents had significantly higher rates of restenosis and retreatment than FGS, based on 1-year follow-up with carotid ultrasonography. They pointed out that many of the patients with restenosis had risk factors for hyperlipidemia. In this study, three patients who underwent retreatment had hyperlipidemia. Management of periprocedural hyperlipidemia may be important in CASPER stent placement.

Mazurek *et al*⁸ reported in their meta-analysis that the CASPER stent has a higher rate of restenosis than the CGuard stent (InspireMD, Boston, MA, USA), despite both being SGS with a similar dual-layer structure. Therefore, they questioned whether both stents could be grouped together as the same dual-layer stent. This may be due to the difference in the dual-layer structure of the two stents. The CGuard stent has a two-layer structure with a self-expandable open-cell stent placed on the inside and a micro-net cover with a polyethylene terephthalate placed on the outside. Theoretically, the outer mesh structure is pressed against the vessel wall by the radial force of the inner stent.^{15–17} Conversely, the CASPER stent has a dual-layer structure with a nitinol mesh placed on the inside and a self-expandable braided stent placed on the outside. Although the mesh structure is partially joined to the outer stent, the inner layer has little radial force. The weak contact between the inner and outer layers may be one of the reasons why the rate of in-stent restenosis with intimal hyperplasia is higher with the CASPER stent than with other stents.

In coronary intervention, in-stent restenosis is thought to be induced by persistent mechanical stress on the vessel wall, which triggers a chronic inflammatory response to metal ions at the contact surfaces.¹⁸ Although the detailed mechanism is unknown, it is thought that the intimal proliferation stops when uniform intimal proliferation is formed all around the inner surface of the stent. Dual-layer CASPER stents have a higher metal content than conventional single-layer stents, and they may be more prone to intimal hyperplasia due to metal reactions. Furthermore, due to the difference in the material and the structure of the dual layer, the CASPER stent has a larger amount of metal on the contact surface with the vascular wall than the CGuard stent.

According to the IVUS findings after 6 months in our study, the intimal proliferation in the CASPER stent was predominantly found in the dual-layer part and was thickest in the original stenotic region. This suggests that the inflammatory response to metal might be strong in the original stenotic region. Intimal hyperplasia was also observed between the inner and outer layers

of the CASPER stent, and the inner layer was pushed inwards and deformed, causing dissociation due to intimal hyperplasia between the inner and outer layers. This may be a characteristic phenomenon that occurs with the CASPER stent due to the weak radial force of the inner layer.

Figure 4 shows the mechanism of intimal proliferation in the CASPER stent based on IVUS findings. First, intimal formation starts from the outer layer and then proliferates between the dual layers, and if the contact between the dual layers is good, it proliferates beyond the inner layer, and it eventually stops when stable uniform intimal proliferation forms inside the stent surface. Conversely, when the contact of the dual layer is poor, intimal proliferation pushes the inner layer inward and proliferates, and metallic stress continues to be applied to the intima from both the inner and outer layers, which further promotes intimal proliferation. When the inner layer can no longer be deformed, the intimal proliferation eventually reaches the inner surface of the stent beyond the inner layer; after that normal intimal proliferation occurs, and finally the intimal proliferation stably stops. In summary, if contact between the inner layer and the outer layer is weak in a dual-layer stent, once intimal proliferation occurs, it may be difficult to stop the proliferation. Therefore, thick intimal hyperplasia is more likely to occur than in conventional stents, and it may cause severe in-stent restenosis in the CASPER stent.

In the present study, various degrees of intimal formation on IVUS occurred within 6 months, and subsequent follow-up on carotid ultrasonography showed no significant increase in PSV. Intimal formation may have already occurred and stabilized within 6 months. In the coronary intervention, it has been reported that regression of the neointimal volume is usually observed from 6 months to 4 years after bare-metal stent implantation and, conversely, some lesions lead to restenosis in the very late period due to in-stent neoatherosclerotic change.^{19 20} Therefore, also in CAS, it will be necessary to continue careful follow-up in the future.

On IVUS immediately after stenting, ISA was likely to occur in the distal portion of the dual-layer part of the stent. This also

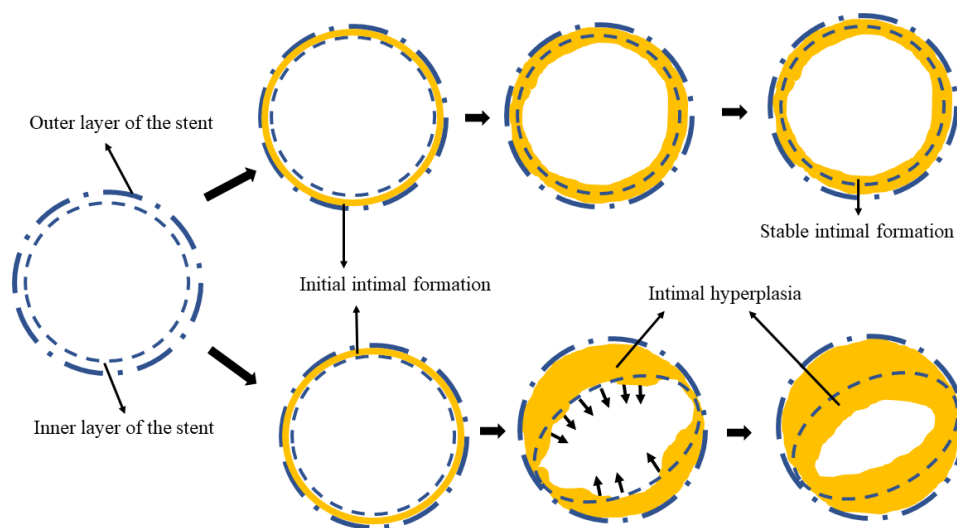


Figure 4 Mechanism of restenosis in the CASPER stent. First, initial conventional intimal formation due to metal reaction occurs between the inner and outer layers of the dual-layer stent. After that, as with conventional stents, when uniform intimal formation is completed on the surface of the inner layer, intimal proliferation stops, and proper intimal formation stabilizes (upper side). Conversely, if the contact between the inner and outer layers is weak due to some factor, dissociation occurs between the dual layers, and intimal proliferation continues due to metal reactions from both the inner and outer layers, and the inner layer eventually deforms. When the dual layers can no longer be dissociated, intimal proliferation crosses over the inner layer and shifts to conventional intimal proliferation, and proliferation stops when uniform intimal formation is completed (lower side).

seems to be one of the structural problems of the CASPER stent. It is possible that ISA in the distal portion could serve as a scaffold for intimal hyperplasia in the future. Therefore, in CASPER stent placement, post-dilatation with a PTA balloon should be applied firmly to ensure contact of the inner layer to the outer layer, and a long PTA balloon that covers the dual-layer part should be recommended. Treatment for in-stent restenosis after CASPER stenting should be considered with PTA or additional stenting, as in conventional in-stent restenosis. Considering the structure of the CASPER stent, if an additional stent is used for restenosis, it seems that the conventional open-cell stent should be selected to keep the inner layer tightly pressed against the outer layer without increasing the amount of metal as much as possible.

The limitations of this study are as follows: comparison with other stents was not performed; this was a single-center, retrospective study and the number of patients was small; and due to the small number of patients, it is unclear what kind of patient background and lesion characteristics could be risk factors for restenosis. Careful and long-term follow-up is necessary, as well as accumulating more cases and elucidating the risk factors for restenosis, such as including patient background and lesion characteristics.

CONCLUSIONS

The CASPER stent appears to be effective for preventing periprocedural ischemic complications. IVUS observations showed various degrees of intimal formation within 6 months after treatment, and it is possible that the CASPER stent is structurally prone to intimal formation or hyperplasia. Careful follow-up for restenosis is necessary in the future.

Contributors HM: study design, data collection and analysis, manuscript preparation, manuscript editing, and guarantor of the whole study. DI: study design, data collection and analysis. HN: study design, data collection and analysis. YN: data collection. KM: data collection.

Funding The authors have not declared a specific grant for this research from any funding agency in the public, commercial or not-for-profit sectors.

Competing interests None declared.

Patient consent for publication Not applicable.

Ethics approval This study involved human participants and was approved by the institutional review board of Kishiwada Tokushukai Hospital (permission number 21-16). Participants gave informed consent to participate in the study before taking part.

Provenance and peer review Not commissioned; externally peer reviewed.

Data availability statement Data are available upon reasonable request.

Open access This is an open access article distributed in accordance with the Creative Commons Attribution Non Commercial (CC BY-NC 4.0) license, which permits others to distribute, remix, adapt, build upon this work non-commercially, and license their derivative works on different terms, provided the original work is properly cited, appropriate credit is given, any changes made indicated, and the use is non-commercial. See: <http://creativecommons.org/licenses/by-nc/4.0/>.

ORCID iD

Hiroyuki Matsumoto <http://orcid.org/0000-0002-1520-3586>

REFERENCES

- 1 Texakalidis P, Giannopoulos S, Kokkinidis DG, *et al*. Effect of open- vs closed-cell stent design on periprocedural outcomes and restenosis after carotid artery stenting: a systematic review and comprehensive meta-analysis. *J Endovasc Ther* 2018;25:523–33.
- 2 de Vries EE, Meershoek AJA, Vonken EJ, *et al*. A meta-analysis of the effect of stent design on clinical and radiologic outcomes of carotid artery stenting. *J Vasc Surg* 2019;69:1952–61.
- 3 Faateh M, Dakour-Arudi H, Mathlouthi A, *et al*. Comparison of open- and closed-cell stent design outcomes after carotid artery stenting in the Vascular Quality Initiative. *J Vasc Surg* 2021;73:1639–48.
- 4 Diaz O, Lopez G, Roehm Jr JOF, *et al*. The Casper carotid artery stent: a unique all metal micromesh stent designed to prevent embolic release. *J Neurointerv Surg* 2018;10:133–6.
- 5 Broussalis E, Griessenauer C, Mutzenbach S, *et al*. Reduction of cerebral DWI lesion burden after carotid artery stenting using the CASPER stent system. *J Neurointerv Surg* 2019;11:62–7.
- 6 Kahlberg A, Bilman V, Ardita V, *et al*. Contemporary results of carotid artery stenting using low-profile dual-metal layer nitinol micromesh stents in relation to single-layer carotid stents. *J Endovasc Ther* 2021;28:726–36.
- 7 Imamura H, Sakai N, Matsumoto Y, *et al*. Clinical trial of carotid artery stenting using dual-layer CASPER stent for carotid endarterectomy in patients at high and normal risk in the Japanese population. *J Neurointerv Surg* 2021;13:524–9.
- 8 Mazurek A, Malinowski K, Rosenfield K, *et al*. Clinical outcomes of second- versus first-generation carotid stents: a systematic review and meta-analysis. *J Clin Med* 2022;11:4819.
- 9 North American Symptomatic Carotid Endarterectomy Trial (NASCET) Steering Committee. North American Symptomatic Carotid Endarterectomy Trial. Methods, patient characteristics, and progress. *Stroke* 1991;22:711–20.
- 10 Brott TG, Hobson 2nd RW, Howard G, *et al*. Stenting versus endarterectomy for treatment of carotid-artery stenosis. *N Engl J Med* 2010;363:11–23.
- 11 Rosenfield K, Matsumura JS, Chaturvedi S, *et al*. Randomized trial of stent versus surgery for asymptomatic carotid stenosis. *N Engl J Med* 2016;374:1011–20.
- 12 Honye J, Saito S, Takayama T, *et al*. Clinical utility of negative contrast intravascular ultrasound to evaluate plaque morphology before and after coronary interventions. *Am J Cardiol* 1999;83:687–90.
- 13 Yamada K, Yoshimura S, Miura M, *et al*. Potential of new-generation double-layer micromesh stent for carotid artery stenting in patients with unstable plaque: a preliminary result using OFDI analysis. *World Neurosurg* 2017;105:321–6.
- 14 Sýkora J, Zeleňák K, Vorčák M, *et al*. Comparison of restenosis risk in single-layer versus dual-layer carotid stents: a duplex ultrasound evaluation. *Cardiovasc Intervent Radiol* 2022;45:1257–66.
- 15 Abdullayev N, Maus V, Mpotsaris A, *et al*. Comparative analysis of CGUARD embolic prevention stent with Casper-RX and Wallstent for the treatment of carotid artery stenosis. *J Clin Neurosci* 2020;75:117–21.
- 16 Karpenko A, Bugurov S, Ignatenko P, *et al*. Randomized controlled trial of conventional versus micronet-covered stent in carotid artery revascularization. *JACC Cardiovasc Interv* 2021;14:2377–87.
- 17 Wissgott C, Schmidt W, Brandt-Wunderlich C, *et al*. Clinical results and mechanical properties of the carotid CGUARD double-layered embolic prevention stent. *J Endovasc Ther* 2017;24:130–7.
- 18 Kornowski R, Hong MK, Tio FO, *et al*. In-stent restenosis: contributions of inflammatory responses and arterial injury to neointimal hyperplasia. *J Am Coll Cardiol* 1998;31:224–30.
- 19 Nobuyoshi M, Kimura T, Ohishi H, *et al*. Restenosis after percutaneous transluminal coronary angioplasty: pathologic observations in 20 patients. *J Am Coll Cardiol* 1991;17:433–9.
- 20 Habara M, Terashima M, Nasu K, *et al*. Difference of tissue characteristics between early and very late restenosis lesions after bare-metal stent implantation: an optical coherence tomography study. *Circ Cardiovasc Interv* 2011;4:232–8.