

microcatheter. Eighteen aneurysms in 9 swine were surgically created using vein auto-grafts. Embolizations were performed in following device combinations: Novel Stent with coil (Group1: Novel stent, n = 6), commercially available stent (Group2: Neuroform stent, n = 6) with coil, and coil alone (Group3: coil, n = 6). Swine were sacrificed 14 days after stent deployment.

**Results** Mean aneurysm neck size was 6.24 mm (4.3–8.26 mm), and average aneurysm fundus size was 9.0 mm (5.8–10.9 mm). All cases in Group2 were treated by Neuroform stent. Average VER (volume embolization ratio) of Group1, Group2, and Group3 was 10.1%, 10.9%, and 10.5%, respectively. There were no technical complications during novel stent deployment, such as migration, occlusion, etc. Favorable angiographic outcome, such as complete aneurysm thrombosis, was observed in 50% of group3, and there was no favorable outcome in both group2 and 3. Recanalization rate of group1, 2, and 3 is 50% (n = 3), 100% (n = 6), and 66% (n = 4), respectively. Aneurysmal rupture after procedure was observed in three cases from group 2, and two cases from group 3.

**Conclusion** The present study showed promising initial experience with the novel stent, particularly for its role as a low profile flow diverting stent and as an assisting stent for coil therapy.

**Disclosures** I. Kan: 1; C; Japan Agency for Medical Research and Development. Y. Murayama: 1; C; Japan Agency for Medical Research and Development. K. Karagiozov: None. A. Ikemura: None. I. Yuki: None. H. Takao: None. T. Kodama: None.

E-072

#### 50 SHADES OF GRADIENTS: DOES THE PRESSURE GRADIENT IN VENOUS SINUS STENTING FOR IDIOPATHIC INTRACRANIAL HYPERTENSION MATTER?

<sup>1</sup>C McDougall, <sup>2</sup>J Beecher, <sup>2</sup>V Shen Ban, <sup>1</sup>M Fiesta, <sup>1</sup>J Barr, <sup>2</sup>J White, <sup>1</sup>R Novakovic, <sup>1</sup>G Pride, <sup>2</sup>B Welch. <sup>1</sup>Radiology, University of Texas Southwestern, Dallas, TX; <sup>2</sup>Neurosurgery, University of Texas Southwestern, Dallas, TX

10.1136/neurintsurg-2016-012589.144

**Introduction** Idiopathic intracranial hypertension (IIH) is a relatively uncommon, poorly understood disease that is often difficult to treat. First line medical and surgical therapies are often ineffective. Venous sinus stenosis is found in the vast majority of patients with IIH and venous sinus stenting (VSS) has been demonstrated to be effective in a select patient group. Identifying which patients will benefit from stenting

remains unclear. One strategy is to measure the pressure gradient across the stenosis using retrograde transvenous manometry. Many authors have adopted a strategy whereby VSS is offered to patients with a pressure gradient above a certain threshold. This number is variable between different operators. In this study we reviewed the literature to try and establish what if any evidence exists to support a relationship between the pressure gradient across the stenosis and clinical outcomes. **Materials and methods** We systematically reviewed the English literature for studies reporting both the pressure gradients across the stenosis for each patient and the individual patient outcomes. Data was then analyzed for statistical correlations between the pressure gradient and the outcome.

**Results** We identified 85 patients from 13 studies in which both the pressure gradient and clinical outcomes were reported for each patient.

ANOVA comparing gradients with outcomes was not significant ( $p = 0.06$ ). Student's *t*-test analysis of the groups with a dichotomization between the group with favorable outcomes and those with unfavorable outcomes was also not significant ( $p = 0.13$ ). The pressure gradient was not found to be a statistically significant predictor of outcome on univariate logistic regression analysis ( $p = 0.15$ ).

**Conclusion** Venous sinus stenting for IIH appears to have good clinical results in selected cases. However, from the available reported cases in the literature, there does not appear to be any correlation between an increasing pressure gradient across the region of stenosis and the chances of an improved outcome. These findings underscore the need for further study of IIH and reflect our incomplete understanding of its exact pathophysiology.

**Disclosures** C. McDougall: None. J. Beecher: None. V. Shen Ban: None. M. Fiesta: None. J. Barr: None. J. White: None. R. Novakovic: None. G. Pride: None. B. Welch: None.

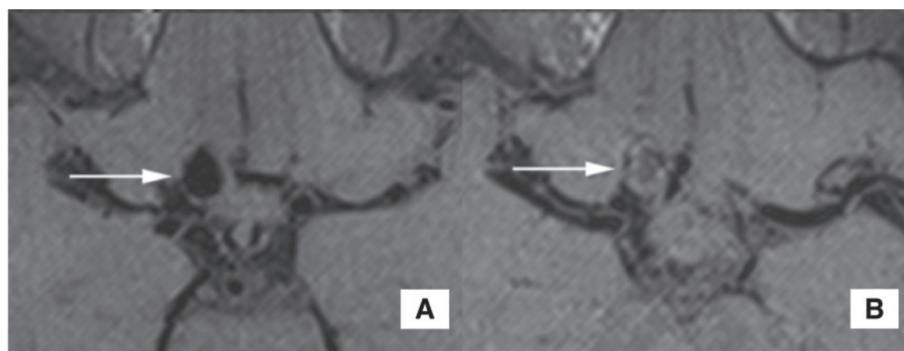
E-073

#### HIGH RESOLUTION MAGNETIC RESONANCE IMAGING OF INTRACRANIAL ANEURYSMS TREATED BY FLOW DIVERSION

<sup>1</sup>J Guan, <sup>2</sup>S McNally, <sup>3</sup>A de Havenon, <sup>1</sup>P Tuassky, <sup>2</sup>S Kim, <sup>1</sup>M Park. <sup>1</sup>Neurosurgery, University of Utah, Salt Lake City, UT; <sup>2</sup>Radiology and Imaging Sciences, University of Utah, Salt Lake City, UT; <sup>3</sup>Neurology, University of Utah, Salt Lake City, UT

10.1136/neurintsurg-2016-012589.145

The use of flow diverters to treat intracerebral aneurysms is highly successful with a low rate of morbidity of mortality.



**Abstract E-073 Figure 1** A) Pre-flow diversion 3D T1w Black Blood pre-contrast image; B) Post-flow diversion 3D T1w Black Blood pre-contrast image

One of the primary concerns following endovascular aneurysm treatment is recurrence, and close imaging followup is often required. High resolution MRI is being employed in an increasingly wide variety of pathologies, but its use as a surveillance tool following flow diversion has not been extensively explored. We present three cases where high resolution MRI was performed following flow diversion for intracranial aneurysms and discuss its utility in this patient population.

**Abstract E-073 Table 1**

MRI sequence parameters					
MRI sequence	TR/TE (ms)	FOV (mm <sup>2</sup> )	Matrix	Thickness (mm)	Scan time (min:sec)
3D TOF	22/3.6	200x181	384x331	0.5	6:50
3D DANTE T1w BB SPACE	800/21	162x162	196x192	0.8	5:47
3D T2w BB SPACE	1000/118	200x200	384x380	0.5	4:18

**Disclosures** J. Guan: None. S. McNally: None. A. de Havenon: None. P. Tuassky: 2; C; Covidien. S. Kim: None. M. Park: None.

**E-074 AN ANALYSIS TO FINAL DIAGNOSIS IN CEREBROVASCULAR ACCIDENT (CVA) PROTOCOL ACTIVATION PATIENTS: SINGLE CENTER STUDY**

**B Moon, S Park, K Jang, D Jang.** *Neurosurgery, Incheon St. Mary's Hospital, Incheon, Republic of Korea*

10.1136/neurintsurg-2016-012589.146

**Introduction** The cerebrovascular accident(CVA) is a disease that can result in life threatening or permanent neurologic sequelae. Although CVA is a world-wide problem, the burden of CVA is particularly serious in Asia; its mortality is higher than in Europe or North America. For patients with CVA occurrence for quick diagnosis and treatment of the CVA protocol, we have many hospitals are trying to maintain the life of patients without neurological sequelae and rapid treatment. The classification of patients is made to only initial patient questionnaire in this protocol. The cases that are often mistaken for CVA have occurred. This study was conducted for determine the method for more accurate patients classification and then to reduce the misdiagnosis.

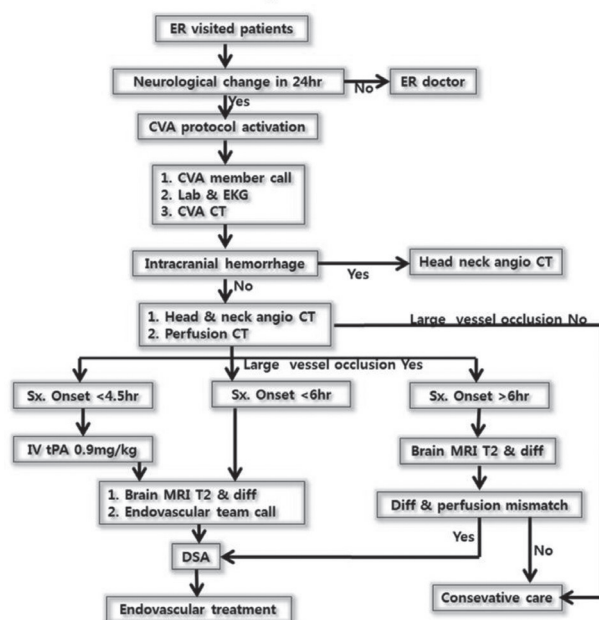
**Methods** The authors conducted a retrospective analysis of CVA protocol activation patient data that were collected at Incheon St. Mary's hospitals over a 8 year period (from January 2008 to July 2015).

The authors were reviewed for CVA protocol activation patients with early symptoms, radiologic image study, lab finding, electronic medical record(EMR) and including the final diagnosis for the patient through the EMR. The diagnosis was classified as a acute CVA such as cerebral infarction, transient ischemic attack (TIA), intracerebral hemorrhage (ICH), intraventricular hemorrhage (IVH), subarachnoid hemorrhage(SAH), arteriovenous malformation (AVM) and diseases that can be confused with this disease such as brain tumor, seizure, traumatic intracranial hemorrhage, medical problem (i.g hyponatremia, pneumonia, myocardial infarction, hypoglycemia), drug abuse, peripheral neuropathy, spinal problem, neuromuscular disease, psychiatric problem.

**Results** In total, 2191 patients met the inclusion criteria of this study. These patients were diagnosed with cerebral infarction (1187, 54.17%), TIA (241, 10.99%), ICH (376, 17.16%), SAH (134, 6.11%), AVM (10, 0.45%), IVH (4, 0.18%), brain tumor (22, 1.00%), traumatic hemorrhage (75, 3.42%), medical problem (31, 1.41%), seizure (22, 1.00%), drug abuse (6, 0.27%), psychiatric disorder (4, 0.18%), peripheral neuropathy (17, 0.77%), neuromuscular disease (5, 0.22%), etc (57, 2.60%).

**Conclusions** This analysis showed that the 89% of patients in the CVA protocol activation were the acute CVA disease. But, the 11% of patients in the CVA protocol activation were the others disease. Well-trained doctors should be conducted initial history taking and accurate neurological examination for reduce to misdiagnosis. And then, we could achieve a cost effective rapid treatment.

## CVA protocol



**Abstract E-074 Figure 1**

**Disclosures** B. Moon: None. S. Park: None. K. Jang: None. D. Jang: None.

**E-075 PERCUTANEOUS THORACOLUMBAR DECOMPRESSION COMBINED WITH PERCUTANEOUS PEDICLE SCREW FIXATION AND FUSION: A METHOD FOR TREATING SPINAL DEGENERATIVE PAIN IN A BIPLANE ANGIOGRAPHY SUITE WITH THE AVOIDANCE OF GENERAL ANESTHESIA**

**B Chopko.** *Neurosurgery, Stanford University, Henderson, NV*

10.1136/neurintsurg-2016-012589.147

**Objective** Spondylitic degeneration of the axial lumbar spine is a major cause of pain and disability. Recent advances in spinal surgical instrumentation, including percutaneous access and fusion techniques, have made possible the performance of instrumented fusion through small incisions. By blending