

SUPPLEMENT:

Supplemental Methods: imaging

Imaging was performed within a CT imaging suite, equipped with a commercially available 64-slice SOMATOM Definition AS CT scanner (Siemens Healthcare GmbH, Forchheim, Germany), was used in combination with a mobile C-arm X-ray device (Cios Alpha, Siemens Healthcare GmbH) with a full-view flat detector. Multimodal CT imaging included native CT, single-phase CT-angiography and CTP. Native CT and CT-angiography were acquired with 120 kV and 20 mAs, and for CT-angiography a single contrast bolus of 65ml Xenetix 350 (Guerbet, Sulzbach, Germany) was given at a flow rate of 4.0 ml/s, followed by a 20 ml saline chaser. CTP was performed with 35 consecutive spiral scans at 180 kV and 80 mAs, with a single contrast bolus of 36ml Xenetix 350 at a flow rate of 6.0 ml/s, followed by a 20 ml saline chaser, for a total acquisition time of 60s. CTA was reconstructed with both the B26f and B46f kernels at a thickness of 0.75mm, while native CT was reconstructed with J40s kernel at 4mm thickness. CTP was reconstructed with H20f Kernel, 5mm slice thickness every 3mm, matrix 512x512, covering 128mm on the z-axis. All patients underwent a repeated native CT follow-up within 48h of intervention.

Supplemental Methods: image processing

Perfusion image pre-processing steps within the Cercare Medical Neurosuite included removal of gantry from the raw images, correction for non-equidistant slice timing, and skull stripping. Standard motion correction was applied using an affine transformation matrix determined in a standard four-level pyramid with a normalized mutual information (NMI) metric.

All image sequences (native CT, raw CTP and CTP maps) were converted to the NIfTI format for further analysis using mcverter (Lewis Center for Neuroimaging, University of Oregon). The first dynamic acquisition scan of the raw CTP was then separated from the 4-dimensional image block for both pre- and post-interventional CTP, and the images were skull stripped to

improve registration performance. The post-interventional CTP was then linearly registered to the pre-interventional CTP using FSL (FMRIB, Oxford, United Kingdom). The same transformation was then applied to the parametric CTP maps, resulting in pre- and post-interventional perfusion images on the same plane.

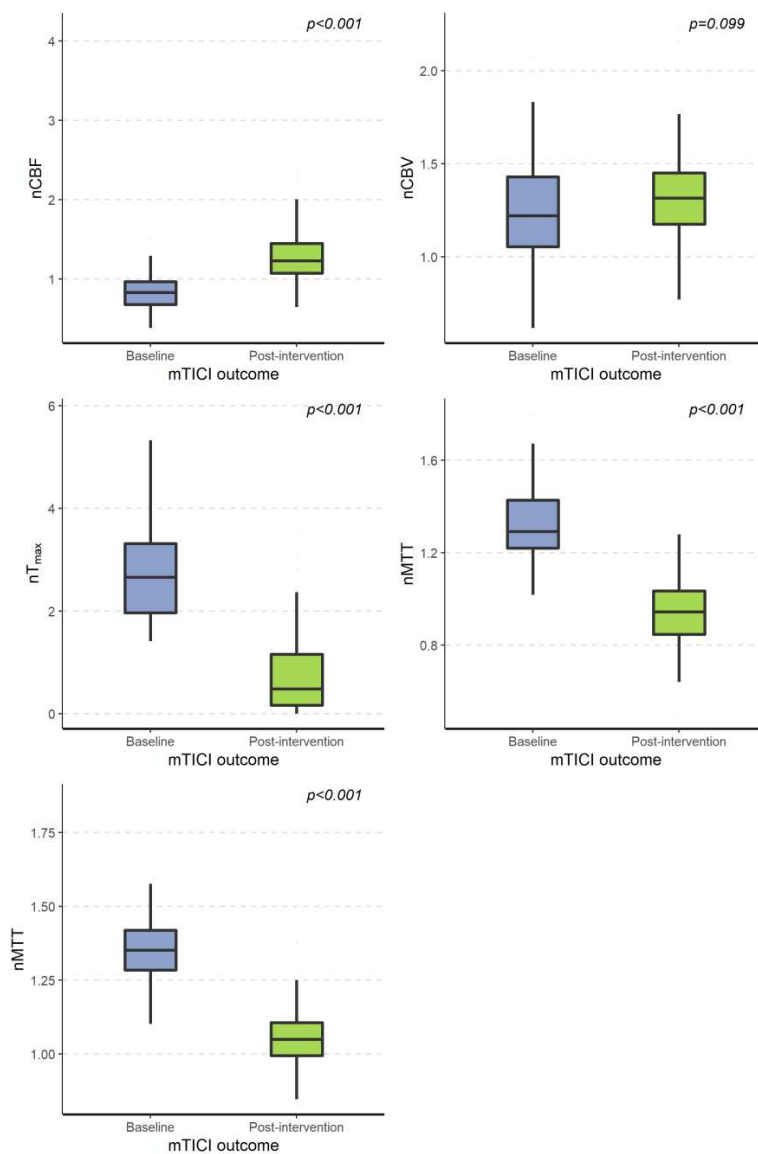
Electronic ASPECTS (eASPECTS) was automatically calculated on NCCT at baseline using the Brainomix software (version 7.1, Oxford, United Kingdom, www.brainomix.com), which has been shown to generate robust values for eASPECTS, and visually reviewed to avoid inconsistencies. Collateral status was evaluated and scored using the eCTA suite of Brainomix.

Supplemental Table 1. Comparison of clinical, imaging, and angiographic characteristics between patients with complete (mTICI > 2b) and incomplete recanalization (mTICI ≤ 2b).

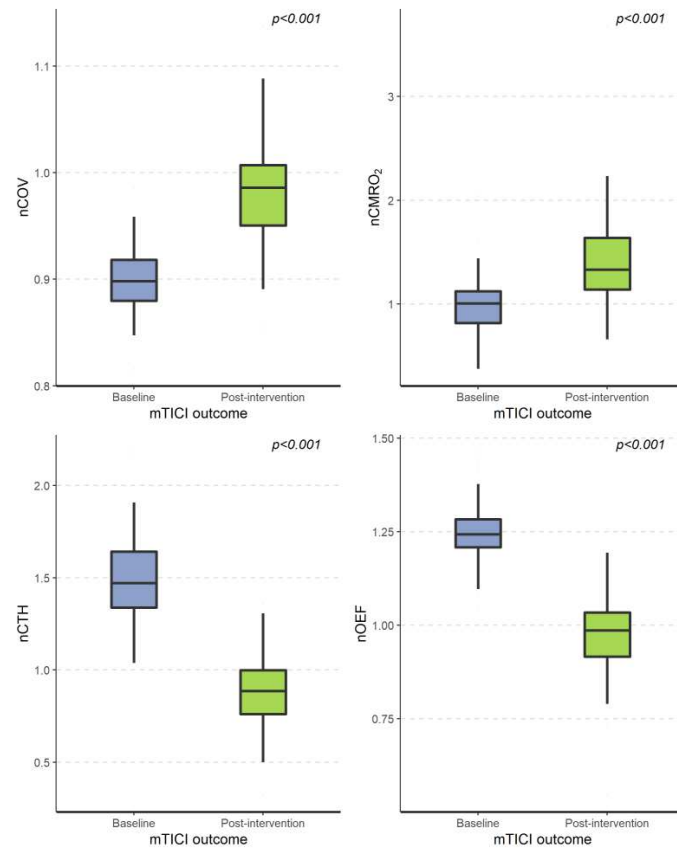
Parameter	mTICI ≤ 2b	mTICI > 2b	p-value*
Patients (n)	22	25	-
Age (median, IQR)	76 (65-85)	79 (73-83)	0.579
Sex (n, %)			
male	10 (45%)	13 (52%)	0.876
female	12 (54%)	12 (48%)	
NIHSS (median, IQR)			
Admission	17 (11-20)	18 (15-21)	0.330
Discharge	12 (4-16)	6 (3-13)	0.309
Wake-up Stroke (n, %)	2 (9%)	2 (8%)	1.000
mRS (median, IQR)			
Pre-morbid	0 (0-2)	1 (0-3)	0.331
Discharge	4 (4-5)	3 (3-5)	0.142
Comorbidities (n, %)			
Hypercholesterolemia	6 (27%)	9 (36%)	0.743
Hypertension	16 (72%)	20 (80%)	0.809
Diabetes mellitus	5 (23%)	2 (8%)	0.315
Coronary heart disease	8 (36%)	6 (24%)	0.545
Intravenous rTPA (n, %)			
Yes	13 (59%)	11 (44%)	0.459
No	9 (41%)	14 (56%)	
Baseline eASPECTS score (median, IQR)	7 (2-9)	7 (2-8)	0.146
eCTA collateral score (median, IQR)	3 (2-3)	2 (1-3)	0.409
Location of Occlusion on CT-Angiography:			
Carotid T	4 (16%)	7 (28%)	0.354
M1 Segment	11 (44%)	15 (60%)	
M2 Segment	6 (24%)	3 (12%)	
M3/4 Segment	1 (4%)	0	

Onset to puncture time [minutes] (median, IQR)	188 (132-271)	189 (126-252)	0.662
Puncture to mTICI time [minutes] (median, IQR)	81 (59-104)	49 (38-72)	0.005

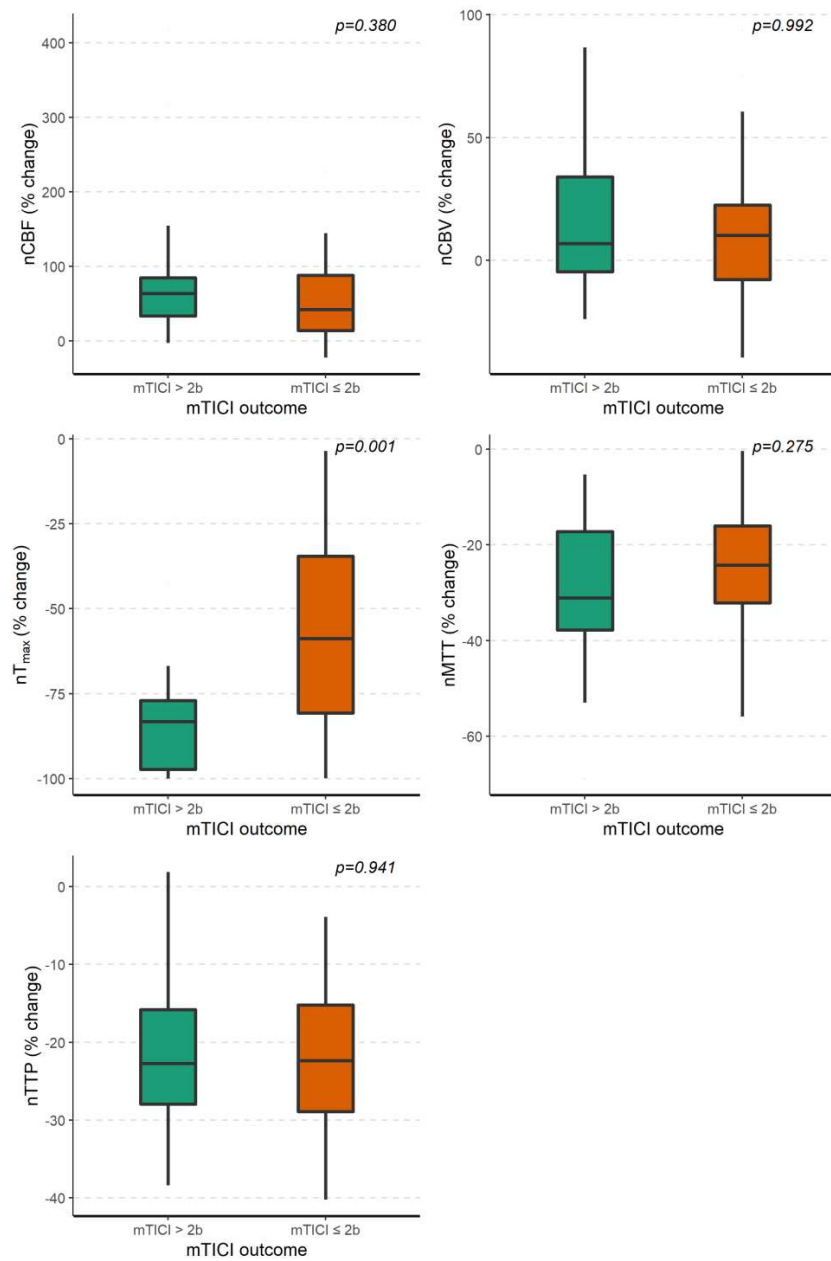
Supplemental Figure 1. Changes in perfusion values before and after mechanical thrombectomy.



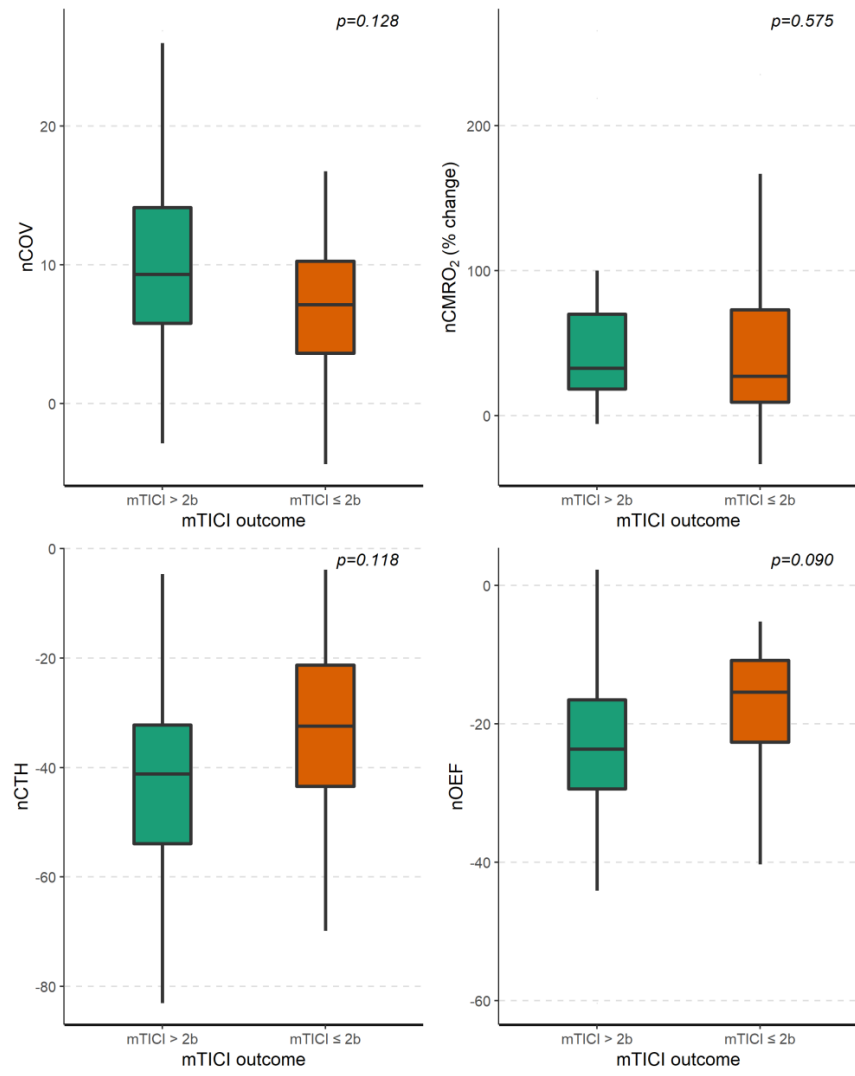
Supplemental Figure 2. Changes in oxygenation values before and after mechanical thrombectomy.



Supplemental Figure 3. Comparison of the percentage-wise changes in perfusion metrics after EVT stratified by mTICI outcome.



Supplemental Figure 4. Comparison of the percentage-wise changes in oxygenation metrics after EVT stratified by mTICI outcome.



Supplemental Figure 5. Comparison of the percentage-wise change in volume after EVT for the total hypoperfused area, the ischemic penumbra, and the ischemic core, stratified by mTICI outcome.

