



OPEN ACCESS

Original research

Accuracy of augmented reality-guided drainage versus stereotactic and conventional puncture in an intracerebral hemorrhage phantom model

Theo Demerath,¹ Amin Stanicki,² Roland Roelz,³ Mateo Tomas Farina Nunez ³, Marco Bissolo,³ Christine Steiert,³ Panagiotis Fistouris,³ Volker Arnd Coenen,² Horst Urbach,¹ Christian Fung,³ Jürgen Beck,³ Peter Christoph Reinacher^{2,4}

► Additional supplemental material is published online only. To view, please visit the journal online (<http://dx.doi.org/10.1136/neurintsurg-2022-018678>).

¹Department of Neuroradiology, Medical Center - University of Freiburg, Faculty of Medicine, University of Freiburg, Freiburg, Germany

²Department of Stereotactic and Functional Neurosurgery, Medical Center - University of Freiburg, Faculty of Medicine, University of Freiburg, Freiburg, Germany

³Department of Neurosurgery, Medical Center - University of Freiburg, Faculty of Medicine, University of Freiburg, Freiburg, Germany

⁴Fraunhofer Institute for Laser Technology (ILT), Aachen, Germany

Correspondence to

Dr Peter Christoph Reinacher, Stereotactic and Functional Neurosurgery, Medical Center - University of Freiburg, Freiburg 79106, Baden-Württemberg, Germany; peter.reinacher@uniklinik-freiburg.de

Received 18 January 2022

Accepted 19 May 2022



Check for updates

© Author(s) (or their employer(s)) 2022. Re-use permitted under CC BY-NC. No commercial re-use. See rights and permissions. Published by BMJ.

To cite: Demerath T, Stanicki A, Roelz R, et al. *J NeuroIntervent Surg* Epub ahead of print: [please include Day Month Year]. doi:10.1136/neurintsurg-2022-018678

ABSTRACT

Background Minimally invasive intracranial drain placement is a common neurosurgical emergency procedure in patients with intracerebral hemorrhage (ICH). We aimed to retrospectively investigate the accuracy of conventional freehand (bedside) hemorrhage drain placement and to prospectively compare the accuracy of augmented/mixed reality-guided (AR) versus frame-based stereotaxy-guided (STX) and freehand drain placement in a phantom model.

Methods A retrospective, single-center analysis evaluated the accuracy of drain placement in 73 consecutive ICH with a visual rating of postinterventional CT data. In a head phantom with a simulated deep ICH, five neurosurgeons performed four punctures for each technique: STX, AR, and the freehand technique. The Euclidean distance to the target point and the lateral deviation of the achieved trajectory from the planned trajectory at target point level were compared between the three methods.

Results Analysis of the clinical cases revealed an optimal drainage position in only 46/73 (63%). Correction of the drain was necessary in 23/73 cases (32%). In the phantom study, accuracy of AR was significantly higher than the freehand method ($P < 0.001$ for both Euclidean and lateral distances). The Euclidean distance using AR (median 3 mm) was close to that using STX (median 1.95 mm; $P = 0.023$).

Conclusions We demonstrated that the accuracy of the freehand technique was low and that subsequent position correction was common. In a phantom model, AR drainage placement was significantly more precise than the freehand method. AR has great potential to increase precision of emergency intracranial punctures in a bedside setting.

INTRODUCTION

Acute placement of an intracranial drain is necessary for various constellations in clinical neurosurgery. Spontaneous intracerebral hemorrhage (ICH) is a frequent indication for drainage, considered for hemorrhage volumes > 30 mL.^{1,2} Accordingly, although open surgical evacuation of spontaneous ICH has failed to show clinical benefit,^{3,4} recent studies suggest that some patients may benefit from a timely and precise minimally invasive hematoma evacuation in terms of a ‘MISTIE procedure’.^{2,5,6}

WHAT IS ALREADY KNOWN ON THIS TOPIC

⇒ Augmented reality is increasingly being investigated for freehand bedside interventions. Current studies on the treatment of intracerebral hemorrhage suggest that a timely minimally invasive drainage is beneficial.

WHAT THIS STUDY ADDS

⇒ This study demonstrates a high precision of augmented reality guided drainage placement. For this purpose, a systematic study was performed in a phantom model with comparison to stereotaxy and landmark-based freehand methods.

HOW THIS STUDY MIGHT AFFECT RESEARCH, PRACTICE OR POLICY

⇒ These results provide a basis for applying augmented reality in a clinical context for precise and timely drainage placement in deep intracerebral hemorrhage but also other applications (e.g. external ventricular drainage).

There are different minimally invasive techniques for the placement of intracranial drains, and ‘high precision’ procedures (associated with a high expenditure of time and material) can be distinguished from ‘conventional’ freehand drainage. In particular, highly precise procedures include the current ‘gold standard’ stereotactic-guided (STX) drainage, which necessitates application of a stereotactic frame with subsequent image acquisition and choice of an appropriate trajectory. Other techniques include endoscopic hemorrhage drainage placement and procedures using intraoperative image guidance (‘neuronavigated surgery’). These are usually performed in a primarily surgical environment (the operating room (OR)), which significantly increases the procedural time required and the cost. In contrast, current freehand ‘bedside’ drainage techniques use superficial head landmarks, such as the nasion, coronal suture, and external auditory canal.⁷ Non-OR-based procedures can save time, but are likely to be associated with lower precision. Attempts to improve precision of bedside procedures may also include the use of ultrasound,⁸ however, to our knowledge there are currently no

data available that demonstrate an improvement in precision in a prospective setting. Further, angiosuite flat detector⁹ or computed tomography (CT)¹⁰ guidance have also been shown to improve accuracy and enable immediate image acquisition for positional control after drain placement. To our knowledge, there are few data on the accuracy of bedside intracranial puncture procedures. In a retrospective study of 346 patients who underwent bedside ventriculostomy, external ventricular drain (EVD) placement was rated as optimal in 77% of cases and bleeding complications occurred in 5%.¹¹

Therefore, we retrospectively analyzed our internal data regarding the drainage position after bedside freehand puncture (performed according to the following standard¹²) performed in patients with supratentorial ICH. With the advent of augmented reality (AR)/mixed reality techniques, new applications are emerging in which isotropic image datasets can be overlaid with patients or simulated patient models and used to guide a procedure.^{13–20} Recent hardware products such as the Magic Leap 1 (Magic Leap, Plantation, FL, USA; in collaboration with Brainlab, Munich, Germany) are easy to carry and capable of transmitting high-resolution image datasets in real time. Compared with freehand landmark-based techniques, AR-guidance may be used to perform rhizotomy of the Gasserian ganglion with increased accuracy.²¹ These techniques combine increased accuracy with feasibility for use in a ‘bedside procedure setting’, with justifiable time expenditure. However, the methods are not yet approved for clinical use, as precision and applicability in the clinical setting require further studies. Since the application of these new technologies to intracranial punctures has not been adequately tested, our study aimed to compare the accuracy of AR-guided drainage with clinically established techniques (STX and freehand drainage) using a realistic skull model in a simulated deep ICH.

METHODS

Clinical study of ICH drainage position

In a retrospective analysis of patient data in a tertiary referral center between January 2010 and December 2012 (36 months), we identified all patients with supratentorial ICH, who had received a freehand drain placement and postintervention CT. Drain location was classified by a board-certified neuroradiologist according to: (1) the location of the drain tip (perforated apically and sideways) within (ie, 360° surrounded by) hyperdense hemorrhage components; (2) the marginal location of the drain tip, with the drain tip adjacent to hyperdense hemorrhage components; (3) the location of the drain tip outside the hemorrhage area (ie, surrounded by brain parenchyma); and (4) the drain tip passed through the hemorrhage area but the drain tip protruded beyond into adjacent brain parenchyma. In addition, the number of (CT-documented) repositions was evaluated on a case level.

Phantom study comparing STX, AR, and freehand techniques

We built a head phantom using an X-ray-dense bone skull model (Zimmer Biomet Holdings, Inc., Warsaw, IN, USA) and a simulated deep ICH at the level of the right basal ganglia, with a total volume of 82 mL. The hemorrhage model was a surgical glove filled with a sponge soaked in Solustrast 250M diluted 1:10 with saline solution 0.9%, and an iron fragment (1 mm) placed in the center, indicating the target point. A CT scan of the phantom was acquired (Siemens Somatom Scope; Siemens Healthcare, Forchheim, Germany; tube voltage 130 kV, exposure 65 mAs, pitch factor 0.55, tilt 0°, slice thickness 0.75 mm, helical mode).

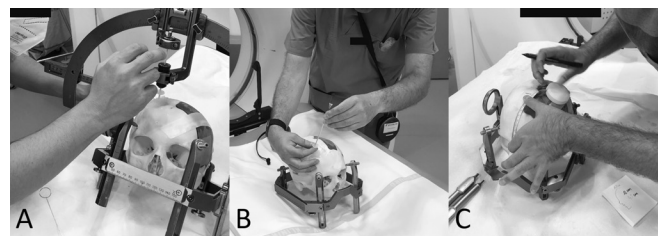


Figure 1 Intracerebral hemorrhage punctures performed in a phantom model under stereotactic (A), augmented reality (B) guidance, or using the freehand technique based on superficial landmarks (C).

Digital imaging and communications in medicine (DICOM) images were transferred to a neurosurgical planning workstation (Brainlab Elements; Brainlab AG, Munich, Germany), where the optimal trajectory for drain placement was determined by an experienced functional neurosurgeon and superimposed into a 3D dataset. The 3D model including the optimal trajectory was then transferred to the AR headset (Magic Leap 1; Brainlab AG, Munich, Germany). The skull model was then filled with commercial petroleum jelly. For practical reasons and to preserve the integrity of the phantom model, a large-area right frontal craniotomy was carried out instead of drilling individual burr holes (figure 1 and online supplemental video). Five neurosurgeons trained in stereotactic neurosurgery independently performed four punctures for each technique: STX, AR, and the freehand approach (figure 1). Stereotactic procedures were performed using the Leksell Coordinate G-Frame (Elekta, Stockholm, Sweden) and Stereotactic Arc (Leksell Multi-Purpose Stereotactic Arc; Elekta). For AR, the holographic projection (hologram) of the phantom was manually aligned with the skull model (figure 1 and online supplemental video). Once sufficiently aligned, the operator tried to replicate the superimposed virtual trajectory in order to place a 23 cm long silicone drain, threaded on a guide needle, as routinely used in clinical practice (straight ventricular catheter, 1.5 mm inner diameter, 3 mm outer diameter, multiperforated over a distance of 25 mm from the proximal tip, radiopaque strip; Sophysa, Orsay, France) (figure 1). Freehand punctures were planned using preoperative 3D isotropic scans in a Picture Archiving and Communication System (PACS) multiplanar reformations plugin. The puncture site was determined based on the superficial distance, starting from the nasion, the lateral deviation between target point and midline, and puncture depth.¹² The external auditory canals were used as superficial landmarks to define the midline and to estimate the angulation of the puncture. After each drain placement, a CT scan was performed to document the needle tip position and trajectory. To address training effects and habituation, the sequence of procedure techniques (STX, AR, and freehand approach) was randomized. The CT images after each needle placement were transferred to the planning workstation, and both the Euclidean distance between the achieved needle tip position and the target point, as well as the lateral deviation between the achieved trajectory and the optimal trajectory at the level of the target point, were analyzed. The clinical study was performed in accordance with the 1964 Declaration of Helsinki and its subsequent amendments and was approved by the local ethics committee (EK-FR 131/19). No ethical approval was required for the phantom trial.

Statistics

The normal distribution was tested using the Shapiro–Wilk test. Non-parametric values are presented as median and interquartile

ranges (IQR) as appropriate. A repeated-measures non-parametric ANOVA with Durbin–Conover pairwise comparison test was calculated over Euclidean and lateral distances between target and drain tip points, comparing STX, AR, and freehand drain placements. All statistical analyses were performed using R statistics V. 4.0 (R Core Team 2020; <https://www.R-project.org>). Boxplots were calculated using CRAN.R packages.

RESULTS

Retrospective clinical data on ICH drainage position

Within 36 months, 71 patients (30 female; median age 73.1 (IQR 19.2) years) with 73 supratentorial ICH required drainage (two patients had multilocular ICH components). In these ICH, the postinterventional drainage position (referring to the perforated drainage tip) was rated as optimal in 46/73 (63%), marginal in 23/73 (32%), and outside the bleeding area in 4/73 (5%) cases. Of note, the drainage tip initially extended beyond the ICH area in 31/73 (42%) cases. In total, repositioning was conducted in 23/73 (32%) of ICH, with two cases requiring more than one correction. However, no hemorrhagic complications beyond the bleeding volume were detectable on imaging.

Phantom study comparing STX, AR, and freehand techniques

There was an overall group difference regarding the Euclidean distance (χ^2 29.0, df 2; $P < 0.001$) and also lateral deviation (χ^2 31.5, df 2; $P < 0.001$) from the target point. In the pairwise comparison, the Euclidean distance with AR (median 3.0 (IQR 1.7) mm) was significantly lower than with the freehand technique (median 11.1 (IQR 6.7) mm; $P < 0.001$). There was also a significantly lower lateral deviation with AR (median 2.3 (IQR 2.1) mm) compared with the freehand technique (median 9.5 (IQR 7.4) mm; $P < 0.001$). STX, as the gold standard, showed the highest accuracy of any method, with a median Euclidean distance of 2.0 (IQR 1.6) mm ($P = 0.023$ vs AR and $P < 0.001$ vs freehand) and a median lateral deviation of 0.9 (IQR 0.5) mm ($P < 0.001$ vs AR and freehand). The maximum Euclidean deviation of a puncture was 23.5 mm and the maximum lateral deviation was 18.2 mm – both performed with the freehand technique. Descriptive values are presented in [table 1](#), with distributions in [figure 2](#).

DISCUSSION

Current literature suggests that patients with spontaneous supratentorial ICH may benefit from minimally invasive hemorrhage drainage; however, further data evaluating early, minimally invasive drainage in particular are required.² Even in primary care centers, current minimally invasive techniques such as STX, neuronavigation, or endoscopic techniques are not commonly available 24/7. Conversely, our in-house retrospective analysis of 73 supratentorial ICH in a primary care setting demonstrated

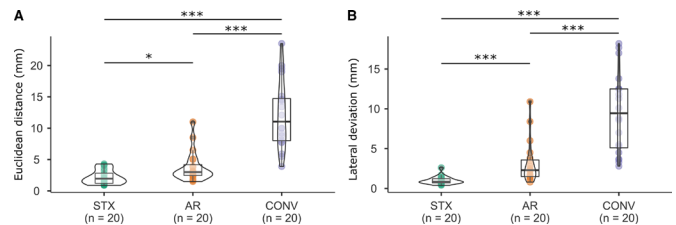


Figure 2 Technical accuracy achieved measuring the Euclidean distance to the target point (A) and lateral deviation of the achieved trajectory from the planned trajectory at target point level (B) using stereotactic-guided (STX), augmented reality-guided (AR), and freehand (CONV) techniques.

that common bedside puncture techniques can be inaccurate, requiring (mostly single) drain repositioning in 32% of cases – results that are consistent with the existing literature on external ventriculostomies.¹¹ Therefore, we believe there is a need for readily available, easy-to-perform techniques that allow for precise catheter placement.

Our data also showed that a marginal drainage position was much more common than an aberrant (intraparenchymal) position, and we assume that corrections were also made for functional reasons (eg, non-functional drainage). However, drainage tip positions exceeding the bleeding volume in the axis of the drainage were also frequent (42%). The data are comparable to the bedside ventriculostomy study by Kakarla *et al*¹¹ in which an optimal location of an EVD was described in 77% of cases. However, no hemorrhagic complications were observed in our study.

According to our results in the realistic phantom model, AR led to enhanced precision compared with the conventional bedside technique. In almost all punctures, we achieved accuracies of less than 1 cm, and in 15/20 cases even less than 5 mm, (measured by Euclidean distances and lateral deviations), which was not the case for most of the conventional punctures. The accuracy of AR-assisted drainage placement was, in fact, very close to stereotactic guidance. The question of whether and to what extent this superior precision could result in a clinical benefit remains open. However, the need for increased precision in bedside punctures of ICH can also be supported by the following consideration: if drainage is considered in a volume of ≥ 30 mL, as per current guidelines,¹ this would correspond to a radius of 1.93 cm, assuming a spherical configuration. Even greater accuracy is desired in non-spherical daily routine cases of ICH.

In our study, AR puncture was preceded by visual surface-based and manual co-registration of the 3D dataset with the phantom model. We anticipate that further improvements can be expected soon, possibly including (semi-)automated surface-based co-registration,²² which may lead not only to more rapidly performable punctures but also to higher accuracy. To provide an outlook for a future clinical scenario, the applied experimental setting was exemplarily transferred to a simulated puncture in the intensive care unit ([figure 3](#) and online supplemental video). Application in a bedside setting would primarily have the advantage of even faster feasibility and potential reduction in the use of (costly) OR capacity. This is the reason why some centers do them as bedside procedures.¹²

Previous studies have shown that hematoma evacuation in spontaneous supratentorial ICH has the potential for improvement in functional outcome and mortality at 3 to 12 months.² In this regard, early drain placement, ideally using a minimally

Table 1 Descriptive values of Euclidean distance and lateral deviation using stereotactic-guided (STX), augmented reality-guided (AR), and freehand (CONV) techniques

	Euclidean distance (mm)			Lateral deviation (mm)		
	STX	AR	CONV	STX	AR	CONV
Median	2.0	3.0	11.1	0.9	2.3	9.5
Interquartile range	1.6	1.7	6.7	0.5	2.1	7.4
Minimum	0.9	1.5	3.9	0.4	0.8	2.8
Maximum	4.3	11.0	23.5	2.6	10.9	18.2

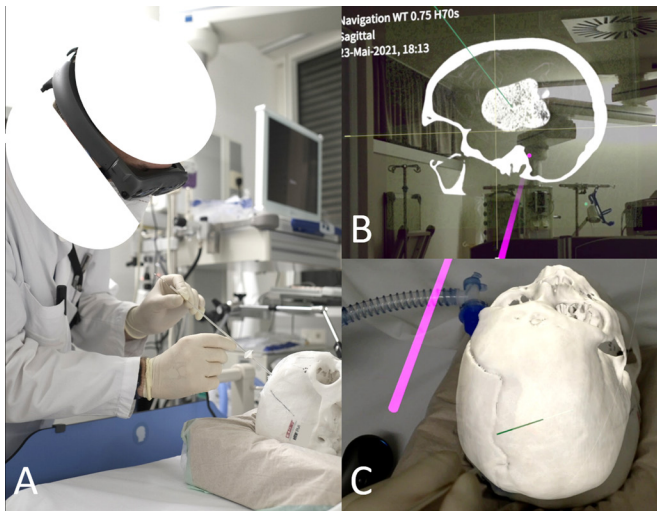


Figure 3 Cranial puncture in an intracerebral hemorrhage phantom model, simulating a bedside intensive care unit setting with augmented reality guidance (A). The Magic Leap 1 headset provides image representations in space that can be freely moved and magnified with a remote control device (B, pink line). The puncture is performed after superimposing the 3D dataset with the real phantom model (C), following the previously planned trajectory (green line).

invasive technique, seems most promising. In MISTIE III, surgical treatment was started on average 58.3 hours after symptom onset, the first administration of alteplase was made after an average of 72.6 hours, and treatment was completed after on average 123 hours. This fact being related to the study design is related to previous evidence of increased rebleeding rates, when evacuation is performed early.²³ However, in MISTIE III, increased volume reduction was related to higher likelihood of improved clinical outcomes (modified Rankin Scale (mRS) 0–3).⁶ Future studies should, on the one hand, consider the potential risk of rebleeding based on current evidence²⁴ but, on the other hand, aim for early, minimally invasive drain placement with relevant ICH volume reduction.

There are limitations to our study. Unfortunately, portable frameless navigation techniques, which are used in many centers in the bedside setting, for example for ventricular puncture, were not part of our study. It is obvious to compare these with mixed-reality applications in the near future, especially with regard to the achievable precision. We used a phantom model that is optimized for multiple punctures with different modalities based on the experimental design. The phantom used is realistic in the sense that cerebral soft tissue was simulated by petroleum jelly, which created a realistic feel of the puncture from the surgeon's point of view. In addition, petroleum jelly has the advantage over agar, for example, in that a previous puncture channel closes completely spontaneously or after minor remodeling and is subsequently neither visually nor haptically detectable. Nevertheless, due to the limited stability of the cranial plaster material regarding multiple punctures, and due to probable biasing by previous punctures, no individual trepanations were performed. The model used does not account for potential errors that may occur during drilling of individual burr holes. In the future, this model could be refined by using new bone flaps for each puncture in order to incorporate the potential error due to drilling of burr holes. However, the acquired image data used can be considered realistic. Furthermore, only one striatal hemorrhage

model was used; nevertheless, this can be considered a frequent and realistic scenario in clinical routine.

There is a need for more precise, easily available, minimally invasive techniques to drain ICH. The AR technique combines greater precision of cranial puncture with applicability in a bedside setting compared with the conventional technique, and thus has great future potential to replace highly precise yet resource-intensive intraoperative techniques in most cases. In addition, there are interesting potential applications of AR such as in EVD placement in patients with narrow lateral ventricles, in application of pain therapy procedures or in the planning of craniotomies, and in brain tumor surgery, which could make this technology a multi-functional tool for neurosurgery.

CONCLUSIONS

According to our clinical analysis, the freehand bedside puncture technique for ICH drainage is inaccurate. In a simulation study of deep ICH, the accuracy of drain placement can be significantly increased by AR and almost reaches that of a more cumbersome stereotactic procedure. AR promises that intracranial punctures can be performed precisely even in a bedside setting.

Contributors PCR, TD: study conception and manuscript writing, guarantors for the overall content of the study. AS, RR, MTFN, MB, CS, PF: data acquisition and critical review of the manuscript. JB, VAC, HU, CF: critical review of the manuscript.

Funding The authors have not declared a specific grant for this research from any funding agency in the public, commercial or not-for-profit sectors.

Competing interests PCR has received research support from Else Kröner-Fresenius Foundation, Fraunhofer Foundation (ATTRACT), German Ministry for Economic Affairs and Energy, and Medical Faculty of the University of Freiburg. He has received personal honoraria for lectures or advice from Boston Scientific, Brainlab, Inomed, and Fraunhofer Foundation and is a consultant to Boston Scientific, Brainlab, and Inomed. TD received funding from the Research Commission, Medical Center - University of Freiburg. VAC receives a collaborative grant from BrainLab (Munich, Germany). He is a consultant for Ceregate (Hamburg, Germany), Cortec (Freiburg, Germany), and Inbrain (Barcelona, Spain). He has ongoing IITs with Medtronic (USA) and Boston Scientific (USA). HU received speaker fees from Bayer AG, Bracco, Eisai, Stryker, and UCB Pharma. The other authors have no personal, financial, or institutional interest in any of the drugs, materials, or devices described in this article.

Patient consent for publication Not applicable.

Ethics approval This study involves human participants and was approved by EK-Freiburg 131/19. Due to the retrospective design of the clinical part of the study, obtaining informed consent was waived by the institutional ethics committee.

Provenance and peer review Not commissioned; externally peer reviewed.

Data availability statement All data relevant to the study are included in the article or uploaded as supplementary information. 'Not applicable'.

Supplemental material This content has been supplied by the author(s). It has not been vetted by BMJ Publishing Group Limited (BMJ) and may not have been peer-reviewed. Any opinions or recommendations discussed are solely those of the author(s) and are not endorsed by BMJ. BMJ disclaims all liability and responsibility arising from any reliance placed on the content. Where the content includes any translated material, BMJ does not warrant the accuracy and reliability of the translations (including but not limited to local regulations, clinical guidelines, terminology, drug names and drug dosages), and is not responsible for any error and/or omissions arising from translation and adaptation or otherwise.

Open access This is an open access article distributed in accordance with the Creative Commons Attribution Non Commercial (CC BY-NC 4.0) license, which permits others to distribute, remix, adapt, build upon this work non-commercially, and license their derivative works on different terms, provided the original work is properly cited, appropriate credit is given, any changes made indicated, and the use is non-commercial. See: <http://creativecommons.org/licenses/by-nc/4.0/>.

ORCID iD

Mateo Tomas Farina Nunez <http://orcid.org/0000-0001-6427-5407>

REFERENCES

- 1 Steiner DT. Behandlung von spontanen intrazerebralen Blutungen. *Leitlinien für Diagnostik und Therapie in der Neurologie*;54.
- 2 Sondag L, Schreuder FHBM, Boogaarts HD, et al. Neurosurgical intervention for supratentorial intracerebral hemorrhage. *Ann Neurol* 2020;88:239–50.
- 3 Mendelow A, Gregson B, Fernandes H, et al. Early surgery versus initial conservative treatment in patients with spontaneous supratentorial intracerebral haematomas in the International Surgical Trial in Intracerebral Haemorrhage (STICH): a randomised trial. *Lancet* 2005;365:387–97.
- 4 Mendelow AD, Gregson BA, Rowan EN, et al. Early surgery versus initial conservative treatment in patients with spontaneous supratentorial lobar intracerebral haematomas (STICH II): a randomised trial. *Lancet* 2013;382:397–408.
- 5 Hanley DF, Thompson RE, Rosenblum M, et al. Efficacy and safety of minimally invasive surgery with thrombolysis in intracerebral haemorrhage evacuation (MISTIE III): a randomised, controlled, open-label, blinded endpoint phase 3 trial. *Lancet* 2019;393:1021–32.
- 6 Awad IA, Polster SP, Carrión-Penagos J, et al. Surgical performance determines functional outcome benefit in the minimally invasive surgery plus recombinant tissue plasminogen activator for intracerebral hemorrhage evacuation (MISTIE) procedure. *Neurosurgery* 2019;84:1157–68.
- 7 Raabe C, Fichtner J, Beck J, et al. Revisiting the rules for freehand ventriculostomy: a virtual reality analysis. *J Neurosurg* 2018;128:1250–7.
- 8 Niesen W-D, Reinhard M, Gierthmuehlen M, et al. Sonographic-assisted catheter-positioning in intracerebral hemorrhage. *Front Neurol* 2018;9:651.
- 9 Dornbos Iii D, Halabi C, DiNitto J, et al. How to iGuide: flat panel detector, CT-assisted, minimally invasive evacuation of intracranial hematomas. *J Neurointerv Surg* 2022;14:neurintsurg-2021-017903.
- 10 Nowacki A, Wagner F, Söll N, et al. Preliminary results of emergency computed tomography-guided ventricular drain placement-precision for the most difficult cases. *World Neurosurg* 2018;114:e1290–6.
- 11 Kakarla UK, Kim LJ, Chang SW, et al. Safety and accuracy of bedside external ventricular drain placement. *Neurosurgery* 2008;63:ONS162–7.
- 12 Deininger MH, Adam A, Van Velthoven V. Bedside catheter evacuation of predominantly isolated traumatic supratentorial hemorrhage. *J Trauma* 2008;65:1194–9.
- 13 Kockro RA, Tsai YT, Ng I, et al. DEX-Ray: augmented reality neurosurgical navigation with a handheld video probe. *Neurosurgery* 2009;65:795–807.
- 14 Cabrilo I, Bijlenga P, Schaller K. Augmented reality in the surgery of cerebral aneurysms: a technical report. *Neurosurgery* 2014;10 Suppl 2:252–61.
- 15 Watanabe E, Satoh M, Konno T, et al. The Trans-Visible Navigator: a see-through neuronavigation system using augmented reality. *World Neurosurg* 2016;87:399–405.
- 16 Deng W, Li F, Wang M, et al. Easy-to-use augmented reality neuronavigation using a wireless tablet PC. *Stereotact Funct Neurosurg* 2014;92:17–24.
- 17 Maruyama K, Watanabe E, Kin T, et al. Smart glasses for neurosurgical navigation by augmented reality. *Oper Neurosurg* 2018;15:551–6.
- 18 Elmi-Terander A, Burström G, Nachabe R, et al. Pedicle screw placement using augmented reality surgical navigation with intraoperative 3D imaging: a first in-human prospective cohort study. *Spine* 2019;44:517–25.
- 19 Abe Y, Sato S, Kato K, et al. A novel 3D guidance system using augmented reality for percutaneous vertebroplasty: technical note. *J Neurosurg Spine* 2013;19:492–501.
- 20 Agten CA, Denner C, Roskopf AB, et al. Augmented reality-guided lumbar facet joint injections. *Invest Radiol* 2018;53:495–8.
- 21 Rau A, Roelz R, Urbach H. Application of augmented reality in percutaneous procedures—rhizotomy of the Gasserian ganglion. *Oper Neurosurg* 2021:opab155.
- 22 Fang W, Zheng L, Deng H, et al. Real-time motion tracking for mobile augmented/virtual reality using adaptive visual-inertial fusion. *Sensors* 2017;17:1037.
- 23 Morgenstern LB, Demchuk AM, Kim DH, et al. Rebleeding leads to poor outcome in ultra-early craniotomy for intracerebral hemorrhage. *Neurology* 2001;56:1294–9.
- 24 Al-Shahi Salman R, Frantzas J, Lee RJ, et al. Absolute risk and predictors of the growth of acute spontaneous intracerebral hemorrhage: a systematic review and meta-analysis of individual patient data. *Lancet Neurol* 2018;17:885–94.