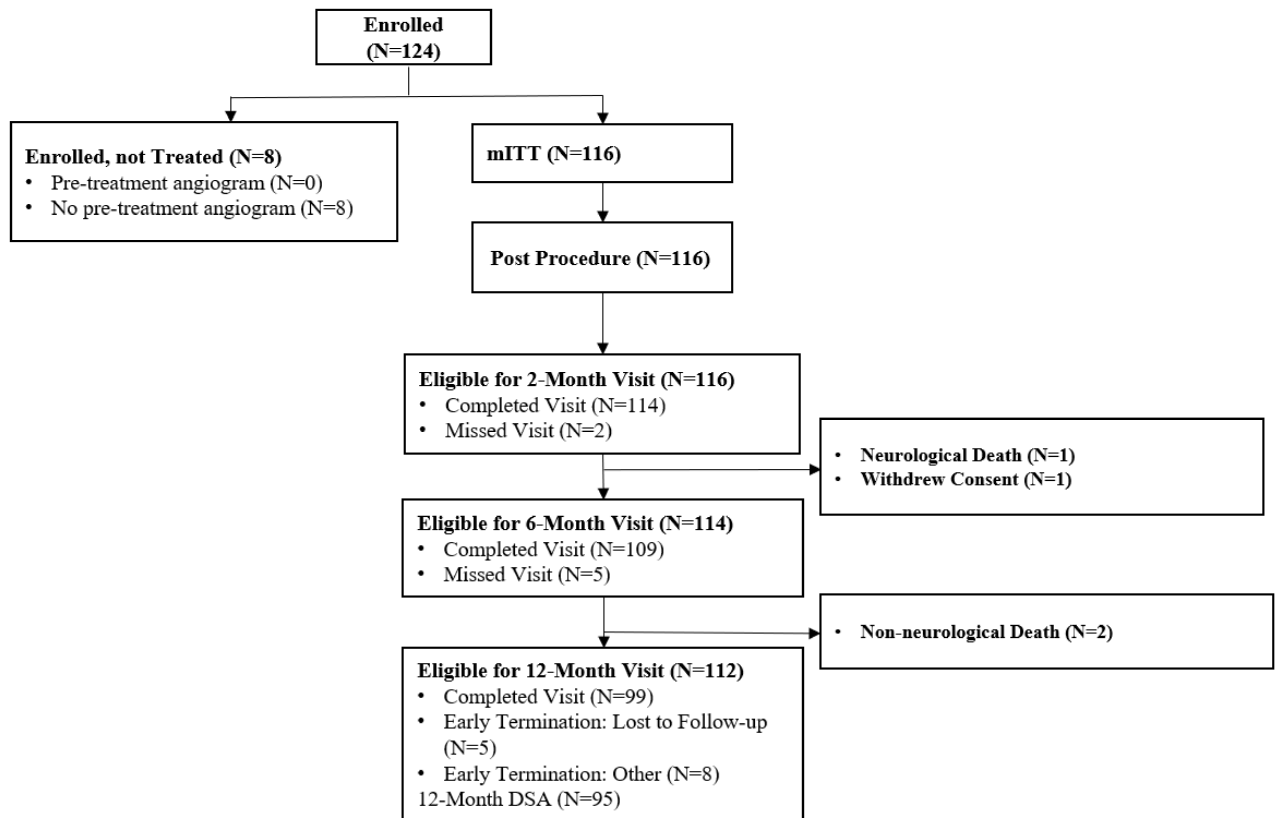


SUPPLEMENTAL MATERIAL

The Pivotal Trial of the Neuroform Atlas™ Stent for Treatment of Wide-Necked Posterior Circulation Aneurysms Multicenter One-Year Clinical Efficacy and Safety



Supplementary Figure I. ATLAS Patient Flow Diagram.

Supplementary Table I. Study Inclusion/Exclusion Criteria

Study Inclusion Criteria
<ol style="list-style-type: none">1. Patient is between 18 and 80 years of age.2. Patient has a documented, wide neck (neck \geq 4 mm or a dome-to-neck ratio $<$ 2), intracranial, saccular aneurysm arising from a parent vessel with a diameter of \geq 2 mm and \leq 4.5 mm, which will be treated with bare metal coils.3. Patient or legal representative is willing and able to provide informed consent.4. Patient is willing and able to comply with protocol follow up requirements.
Study Exclusion Criteria
<ol style="list-style-type: none">1. Patient has known multiple untreated cerebral aneurysms, other than non-target blister aneurysm, infundibulum, or aneurysm measuring $<$ 3 mm for each of three dimensions assessed (height, width, and depth) that will not require treatment during the study period.2. Patient has a target lesion that is a blister aneurysm, infundibulum, or aneurysm measuring $<$ 3 mm for each of three dimensions assessed (height, width, and depth).3. Patient has a target aneurysm that will require an Investigator to intentionally leave a neck remnant in order to preserve blood flow in a bifurcation or branch.4. Patient has undergone coiling or stenting of a non-target intracranial aneurysm within 30 days prior to study treatment.5. Patient has a target aneurysm in the anterior circulation proximal to the superior hypophyseal ICA.6. Patient has acute target aneurysm rupture less than 14 days prior to study treatment.7. Patient has a Hunt and Hess score \geq 3 or a pre-morbid mRS score \geq 4.8. Patient has an admission platelet count of $<$ 50,000, any known coagulopathy, or an International Normalized Ratio (INR) $>$ 3.0 without oral anticoagulation therapy.9. Patient has a known absolute contraindication to angiography.10. Patient has evidence of active cancer, terminal illness, or any condition which, in the opinion of the treating physician, would/could prevent the patient from completing the study (e.g., a high risk of embolic stroke, atrial fibrillation, co-morbidities, psychiatric disorders, substance abuse, major surgery \leq 30 days pre-procedure, etc.).11. Patient has a known absolute contraindication to the use of required study medications or agents

(e.g., heparin, aspirin, clopidogrel, and radiographic contrast agents etc.).

12. Patient is female and is pregnant or intends to become pregnant during the study.

13. Patient has Moya-Moya disease, arteriovenous malformation(s), arteriovenous fistula(e), intracranial tumor(s), or intracranial hematoma(s) (unrelated to target aneurysm).

14. Patient has significant atherosclerotic stenosis, significant vessel tortuosity, vasospasm refractory to medication, unfavorable aneurysm morphology or vessel anatomy, or some other condition(s) that, in the opinion of the treating physician, would/could prevent or interfere with access to the target aneurysm and/or successful deployment of the Neuroform Atlas Stent.

15. Patient has been previously treated (e.g., surgery, stenting) in the parent artery that, in the opinion of the treating physician, would/could prevent or interfere with successful use of the Neuroform Atlas Stent System and/or successful deployment of embolic coils.

16. Patient has undergone previous stent-assisted coiling of the target aneurysm.

ATLAS Posterior Investigator Group (Sorted by number of patients recruited):

University of Pittsburgh Medical Center, Pittsburgh, PA, USA (14) – B. Jankowitz (National PI), A. Jadhav (Past PI), B. A. Gross (Current PI)

University of Kentucky, Lexington, KY, USA (10) – A. Alhajeri (Past PI), J. Fraser (Current PI)

Lyerly Neurosurgery, Jacksonville, Florida, USA (8) – R. Hanel (PI), E. Sauvageau (Sub-I), A. N. Aghaebrahim (Sub-I)

Radiology Imaging Associates, Swedish Medical Center, Englewood, CO, USA (8) – D. Frei (PI), R. Bellon (Sub-I), B. Atchie (Sub-I), I. Kaminsky (Sub-I)

University of Massachusetts Medical School, Worcester, MA, USA (7) – A. Puri (PI), F. Massari (Sub-I)

Department of Neurosurgery, Tufts Medical Center, Boston, MA, USA (6) – A. Malek (PI)

Beth Israel Deaconess Medical Center, Boston, MA, USA (6) – A. Thomas (PI), C. Ogilvy (Sub-I)

Neuroscience Department, Bon Secours Mercy Health St. Vincent Medical Center, Toledo, OH, USA (5) – S. Zaidat (National PI), E. Lin (Sub-I)

Cerebrovascular Center, Cleveland Clinic, Cleveland, OH, USA (5) – G. Toth (PI), M Bain (Sub-I), P. Rasmussen (Sub-I), M. S. Hussain (Sub-I), N. Moore (Sub-I), T. Masaryk (Sub-I), M. Elgabaly (Sub-I)

Rush University Medical College, Chicago, IL, USA (5) – R. W. Crowley (Current PI), D. Lopes (Past PI)

Semmes Murphey Clinic, Memphis, TN, USA (5) – A. Arthur (PI), L. Eljovich (Sub-I), D. Hoit (Sub-I), C. Nickele (Sub-I)

Virginia Commonwealth University Medical Center, Richmond, VA, USA (5) – J. Reavey-Cantwell (Current PI), D. Rivet (Co-PI),

SUNY University at Buffalo, Buffalo, NY, USA (4) – A. Siddiqui (PI), E. Levy (Sub-I), K. Snyder (Sub-I)

Cedars-Sinai Medical Center, Los Angeles, CA, USA (4) – M. J. Alexander (PI), F. Moser (Sub-I), M. Maya (Sub-I), M. Schiraldi (Sub-I)

WellStar Medical Group, Neurosurgery WellStar Health System, Marietta, GA, USA (3) – A. Khaldi (PI), R. Gupta (Sub-I)

The Johns Hopkins Hospital, Baltimore, MD, USA (3) – J. Caplan (Current PI) (did not treat patients but is current PI), G. Colby (Past PI), B. Jiang (Sub-I), M. Bender (Sub-I)

Christiana Care Health System, Newark, DE, USA (3) – S. R. Satti (PI), T. Sivapatham (Sub-I)

Medical University of South Carolina, Charleston, SC, USA (3) – A. M. Spiotta (did not treat patients but is current PI), Q. Turk (Past PI), J. Lena (Sub-I), K. Kicielinski (Sub-I)

Houston Methodist, Houston, TX, USA (3) – R. P. Klucznik (PI), O. Diaz (Sub-I), G. Britz (Sub-I)

Harborview Medical Center, Seattle, WA, USA (2) – D. K. Hallam (PI), B. Ghodke (Sub-I), M. Levitt (Sub-I), L. Kim (Sub-I)

University of Pennsylvania, Philadelphia, PA, USA (2) – D. Kung (Current PI), M. Smith (Past PI), B. Pukenas (Sub-I), R. Hurst (Sub-I)

Vanderbilt University Medical Center, Nashville, TN, USA (2) – M. T. Froehler (PI), M. Fusco (Sub-I), R. Chitale (Sub-I)

SSM Health DePaul Hospital St Louis, Bridgeton, MO, USA (2) – R. C. Callison (PI)

Baylor College of Medicine, Houston, TX, USA (1) – P. Kan (PI)

Vascular Neurology of Southern California, Thousand Oaks, CA, USA (0) – M. Taqi (PI)