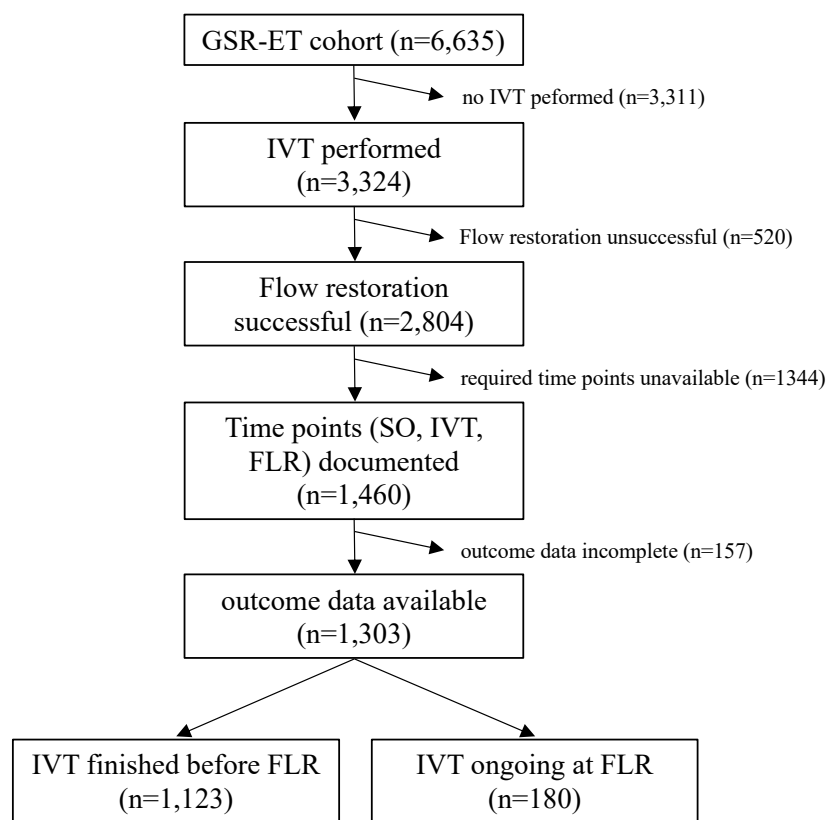


SUPPLEMENTAL MATERIAL

Intravenous thrombolysis upon flow restoration improves outcome in endovascular thrombectomy**Supplementary Figure 1.** Flow diagram for patient inclusion.

SO indicates symptom onset; *IVT*, intravenous thrombolysis; *FLR*, flow restoration.

GSR-ET Collaborators

A. Alegiani, J. Berrouschot, T. Boeck-Behrens, G. Bohner, J. Borggrefe, A. Bormann, M. Braun, B. Eckert, R.M. Eckert, U. Ernemann, M. Ernst, J. Fiehler, C. Gerloff, K. Gröschel, G.F. Hamann, K.H. Henn, L. Kellert, C. Kraemer, H. Leischner, J. Liman, A. Ludolph, O. Nikoubashman, C.H. Nolte, M. Petersen, S. Poli, A. Reich, J. Röther, J.H. Schäfer, P. Schellinger, E. Siebert, F. Stögbauer, G. Thomalla, S. Tiedt, C. Trumm, T. Uphaus, S. Wunderlich.