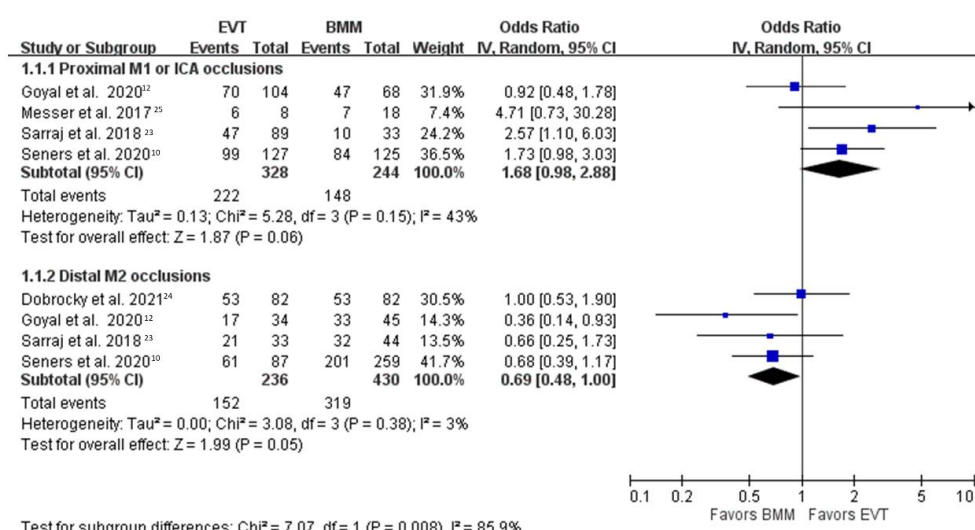


Supplemental Material

Online supplemental eFigure 1

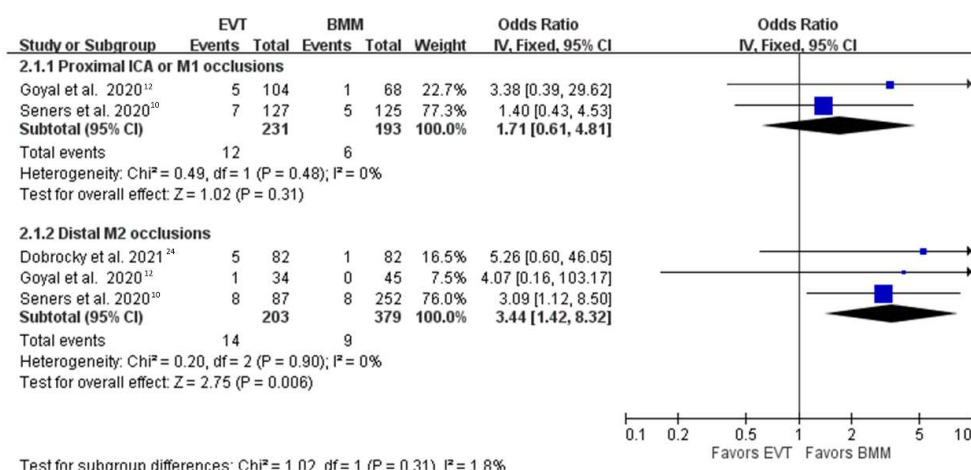
Forest plot comparing endovascular therapy versus best medical management for freedom of disability (modified Rankin Scale 0–1), pooled by random-effect model, in proximal ICA or M1 vs distal M2 occlusions.

BMM: best medical management, CI: confidence interval, EVT: endovascular therapy, ICA: internal carotid artery, M1: first segment of middle cerebral artery, M2: second segment of middle cerebral artery, OR: odds ratio.



Online supplemental eFigure 2

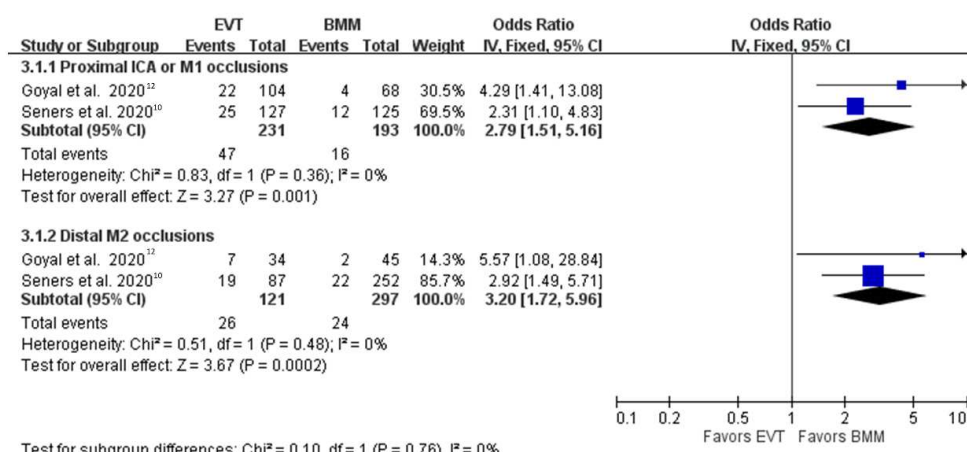
Forest plot comparing endovascular therapy versus best medical management for symptomatic intracranial hemorrhage in proximal ICA or M1 vs distal M2 occlusions. BMM: best medical management, CI: confidence interval, EVT: endovascular therapy, ICA: internal carotid artery, M1: first segment of middle cerebral artery, M2: second segment of middle cerebral artery, OR: odds ratio.



Online supplemental eFigure 3

Forest plot comparing endovascular therapy versus best medical management for any intracranial hemorrhage in proximal ICA or M1 vs distal M2 occlusions.

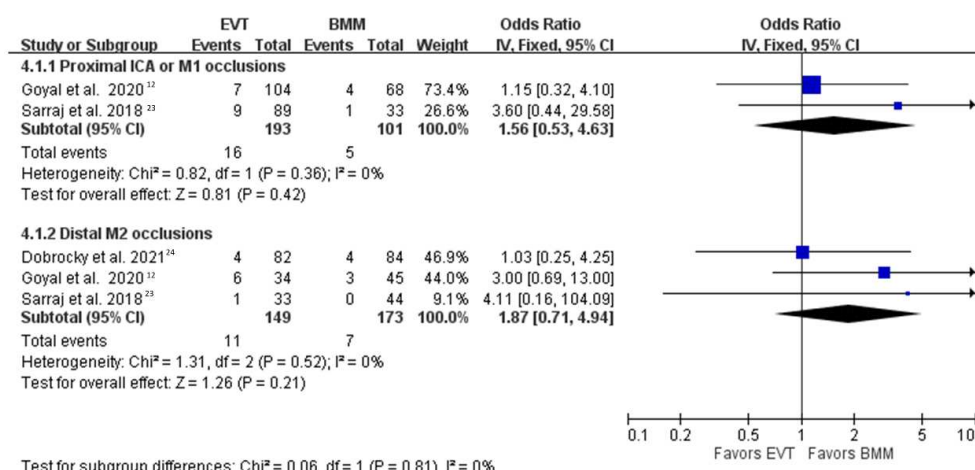
BMM: best medical management, CI: confidence interval, EVT: endovascular therapy, ICA: internal carotid artery, M1: first segment of middle cerebral artery, M2: second segment of middle cerebral artery, OR: odds ratio.



Online supplemental eFigure 4

Forest plot comparing endovascular therapy versus best medical management for all-cause mortality in proximal ICA or M1 vs distal M2 occlusions.

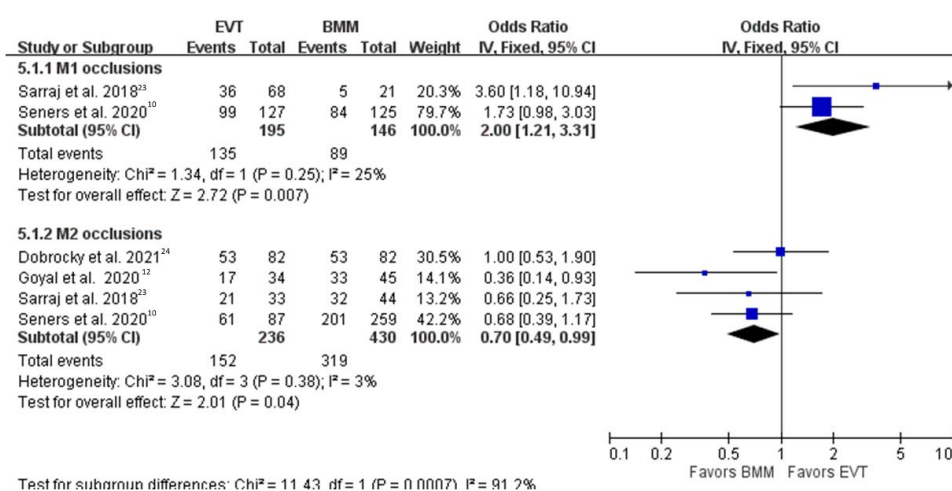
BMM: best medical management, CI: confidence interval, EVT: endovascular therapy, ICA: internal carotid artery, M1: first segment of middle cerebral artery, M2: second segment of middle cerebral artery, OR: odds ratio.



Online supplemental eFigure 5

Forest plot comparing endovascular therapy versus best medical management for freedom of disability (modified Rankin Scale 0–1) in M1 vs M2 occlusions.

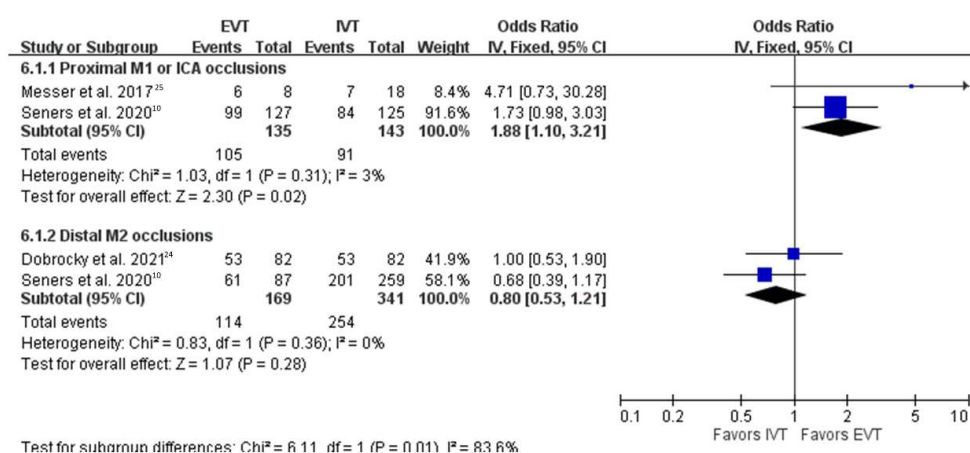
BMM: best medical management, CI: confidence interval, EVT: endovascular therapy, M1: first segment of middle cerebral artery, M2: second segment of middle cerebral artery, OR: odds ratio.



Online supplemental eFigure 6

Forest plot comparing endovascular therapy versus intravenous thrombolysis for freedom of disability (modified Rankin Scale 0–1) in proximal ICA or M1 vs distal M2 occlusions.

CI: confidence interval, EVT: endovascular therapy, ICA: internal carotid artery, IVT: intravenous thrombolysis, M1: first segment of middle cerebral artery, M2: second segment of middle cerebral artery, OR: odds ratio.



Online supplemental eFigure 7

Forest plot comparing endovascular therapy versus best medical management for freedom of disability (modified Rankin Scale 0–1) in proximal ICA or M1 vs distal M2 occlusions, restricted analysis to studies with all patients enrolled after 2011

BMM: best medical management, CI: confidence interval, EVT: endovascular therapy, ICA: internal carotid artery, M1: first segment of middle cerebral artery, M2: second segment of middle cerebral artery, OR: odds ratio.

