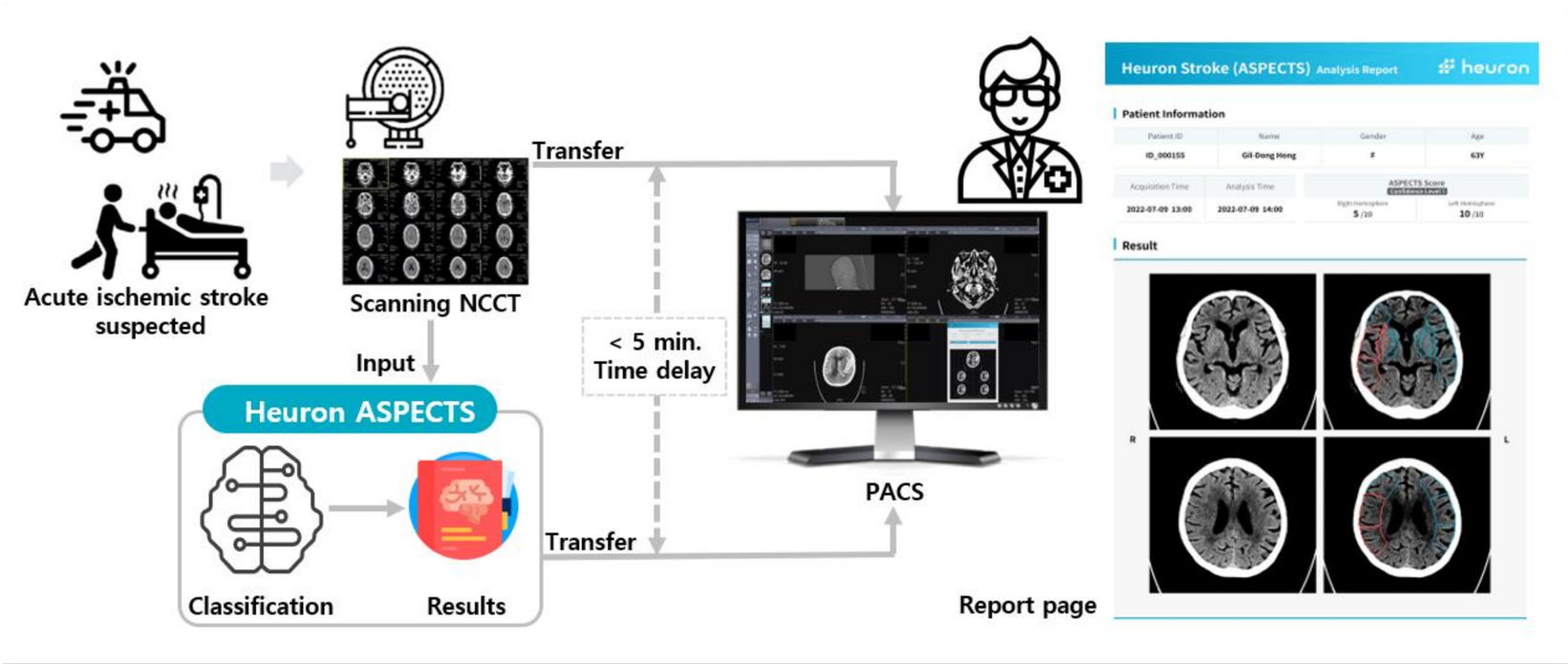


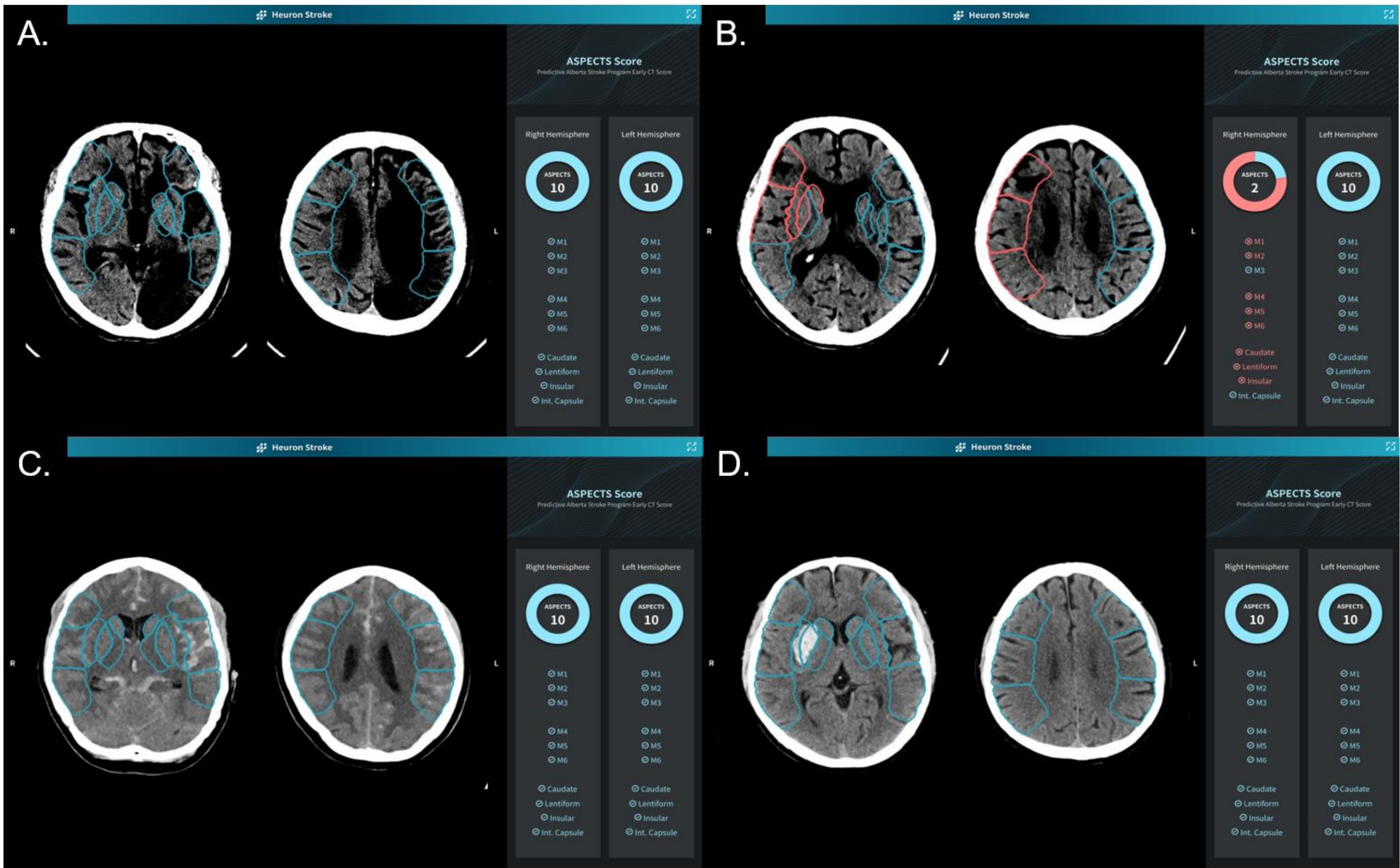
Clinical evaluation of a deep-learning model for automatic scoring of the Alberta Stroke

Program Early CT Score on non-contrast CT

Supplementary Figures



Supplementary Figure 1. A schematic diagram depicting the incorporation of Heuron ASPECTS into clinical workflow.



Supplementary Figure 2. Examples of early ischemic changes (EICs) detected by Heuron ASPECTS. (A) A case of old infarct not detected

as EIC. (B) Detection of EIC case with OI in the same hemisphere. (C) Case of subarachnoid hemorrhage, in which EIC is not detected even when cortical edema and gray–white matter blurring is present. (D) A case of intracerebral hemorrhage, in which no segment was misclassified as EIC by Heuron ASPECTS.